

**PATIENT PRESENTING CLINICAL SIGNS**

Mindy Hughes

**SPECIES**

Feline

**BREED**

DLH

**SEX**

Spayed Female

**AGE**

10/05/2017

**WEIGHT**

3.75 kg

**INTERPRETED BY**

Kathleen Sennello DVM,  
MS, Diplomate ACVIM  
(Small Animal Internal  
Medicine)

**IMAGING PERFORMED BY**

Loetitia Saint-Jacques,  
LVT

**HOSPITAL NAME**

Desert Hills AH

**REFERRING VET**

Dr. Jen Vittori

**INVOICE**

10391

**DATE**

8/8/2023

Patient presented for pre-op LW for dental procedure and found IRIS stage III renal disease. Dental procedure completed with precautions for renal health such as IV fluid support throughout day last week on 8/2/23. Two dental extractions performed, P responding well and is comfortable post-op as P was experiencing dental pain. AUS requested for further eval of renal structures. Working diagnosis IRIS stage III renal disease, suspect congenital with P's age. MEDS: Onsior 6 mg 1 tab PO SID x 3 days then d/c. Buprenorphine 0.6 mg/ml, 0.12 ml PO BID PRN. Switched food to Hill's K/D rx food, otherwise no medication at this time.

Abnormal PE/Chem/CBC/UA Results: Chem panel - BUN mildly elevated at 41 (14-36), Creatinine elevated at 3.4 (0.6-2.4), SDMA elevated at 22.8 (< 15.0). Rest of chem panel WNL. CBC - all values WNL T4 WNL at 1.9. UA - inadequate concentration at 1.018. 2+ occult blood likely due to cysto. Rest WNL/NSF. Keyscreen - undetected Urine culture NEG

**ULTRASONOGRAPHIC EXAMINATION OF THE ABDOMEN**

**Urinary System**

The urinary bladder is moderately distended with anechoic urine. The Bladder wall, trigone, ureteral papillae, and visible urethra (to a depth of 2cm) appear normal with no evidence of wall thickening, mucosal irregularities, masses, or cystic calculi.

The left kidney has a normal shape and size it measures 3.34 cm with severe pyelectasia at 0.79 cm. Additionally, the approximal ureter is dilated measuring 0.34 cm distally it is more normal measuring 0.17 cm. Overall echogenicity is slightly hyperechoic with poor corticomedullary distinction and a typical 1:3 cortex: medulla ratio. There is no evidence of focal perinephric inflammation or effusion. There is no evidence of nephroliths, infarcts or hydroureter. Renal vasculature is normal.

The right kidney has a normal shape and size measuring 3.3 cm with severe pyelectasia at 1.17 cm. The approximal ureter is dilated measuring 0.36 cm distally it normalized measuring 0.1 cm. Overall echogenicity is slightly hyperechoic with poor corticomedullary distinction and a typical 1:3 cortex: medulla ratio. There is no evidence of focal perinephric inflammation or effusion. There is no evidence of nephroliths, infarcts or hydroureter. Renal vasculature is normal.

**Adrenal Glands**

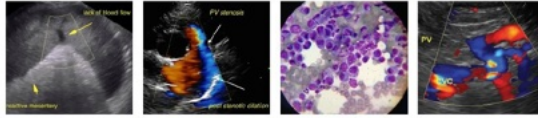
The region of left adrenal (Cranial to left renal artery) is unremarkable but the adrenal is not distinctly visualized. No evidence of a mass effect.

The region of the right adrenal (between right cranial kidney and vena cava) is unremarkable, but the adrenal is not distinctly visualized. No evidence of a mass effect.

**Spleen**

The spleen is subjectively normal in size, echotexture is homogenous, and the splenic capsule is smooth with no irregularities. The blood flow through the hilus and splenic parenchyma appears normal. No focal parenchymal abnormalities are visualized. The spleen measures 0.66 cm.

**Liver**



**PATIENT**

Mindy Hughes

The liver is subjectively normal in size, and echogenicity with smooth peripheral margins. The parenchyma is homogenous echotexture. The visible portions of the vasculature and biliary tract appear normal. No focal nodules or cystic lesions are observed.

**SPECIES**

Feline

The gallbladder lumen is moderately distended. The wall of the gall bladder is not thickened and has a smooth mucosal surface. Luminal contents are mild and primarily anechoic. The cystic and common bile ducts are normal/not visible.

**BREED**

**Gastrointestinal**

DLH

The stomach contains minimal luminal contents. It measures at a normal thickness of <0.36cm with some variability due to the presence of rugal folds. The distinction of the gastric wall layers is adequate and there is no impression of reduced peristaltic activity. No masses or focal lesions were observed.

**SEX**

Spayed Female

The visualized areas of duodenum, jejunum and ileum have a relatively uniform diameter with minimal fluid distension. Wall thickness is normal. Bowel loops follow a curvilinear path with distinct wall layering maintaining the typical 1:3 muscularis: mucosa layer ratio. The duodenum measured as normal (between 0.13-0.38cm in wall thickness) and the jejunum measured as normal (between 0.15-0.36cm.) Visualized peristalsis appears appropriate. There were no focal lesions consistent with obstruction or a mass effect observed.

**AGE**

10/05/2017

**WEIGHT**

3.75 kg

The ileocecal junction was visualized and exhibited normal intact wall layering and is subjectively of normal thickness. Sections of colon are visualized with formed fecal material and gas shadowing distally. There is no observed focal or generalized colon wall thickening or loss of layering.

**INTERPRETED BY**

Kathleen Sennello DVM,  
MS, Diplomate ACVIM  
(Small Animal Internal  
Medicine)

**Pancreas**

The pancreas is prominent and mottled compared to the surrounding isoechoic mesentery. There is no evidence of nodules or cystic lesions. There is no evidence of regional mesenteric inflammation or fluid.

**IMAGING PERFORMED BY**

Loetitia Saint-Jacques,  
LVT

**Free Abdomen**

Evaluation of the peritoneal cavity did not reveal any evidence of effusion, or subjective lymphadenomegaly. The Medial iliac nodes appear normal and there was no evidence of a caudal aortic thrombus at the bifurcation. The omentum is of normal uniform echogenicity.

**HOSPITAL NAME**

Desert Hills AH

**PRIMARY FINDINGS**

- Decreased corticomedullary distinction in both kidneys with bilateral severe pyelectasia and proximally dilated ureters. Pyelectasia of the kidneys could be consistent with pyelonephritis, chronic renal disease, secondary to PU/PD or fluid therapy (if applicable), other.

**REFERRING VET**

Dr. Jen Vittori

**INTERPRETATION OF THE FINDINGS & FURTHER RECOMMENDATIONS**

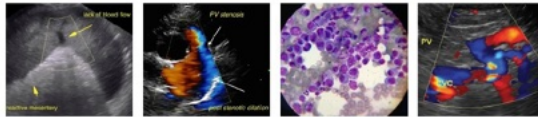
**INVOICE**

10391

There is significant pyelectasia noted in both kidneys. This could be secondary to pyelonephritis, obstructive disease, etc. There is no evidence of stones noted on today's scan. Correlate with abdominal radiographs, which can pick up smaller mineralizations. There would be concern for possible bilateral ureteral strictures in this case. Further evaluation would likely warrant a contrast CT scan, to more closely delineate the ureters and look for any evidence of congenital abnormality which could be contributing to these changes (a topical ureter, etc.) If a significant obstructive process is present, you

**DATE**

8/8/2023



**PATIENT**

Mindy Hughes

**SPECIES**

Feline

**BREED**

DLH

**SEX**

Spayed Female

**AGE**

10/05/2017

**WEIGHT**

3.75 kg

**INTERPRETED BY**

Kathleen Sennello DVM,  
MS, Diplomate ACVIM  
(Small Animal Internal  
Medicine)

**IMAGING PERFORMED BY**

Loetitia Saint-Jacques,  
LVT

**HOSPITAL NAME**

Desert Hills AH

**REFERRING VET**

Dr. Jen Vittori

**INVOICE**

10391

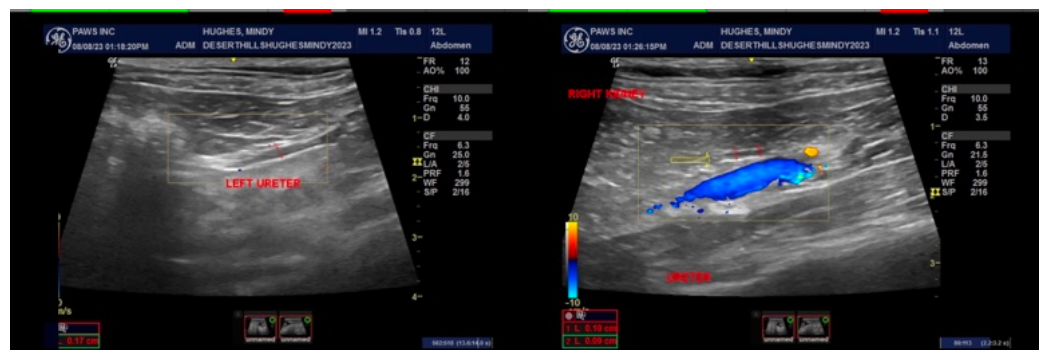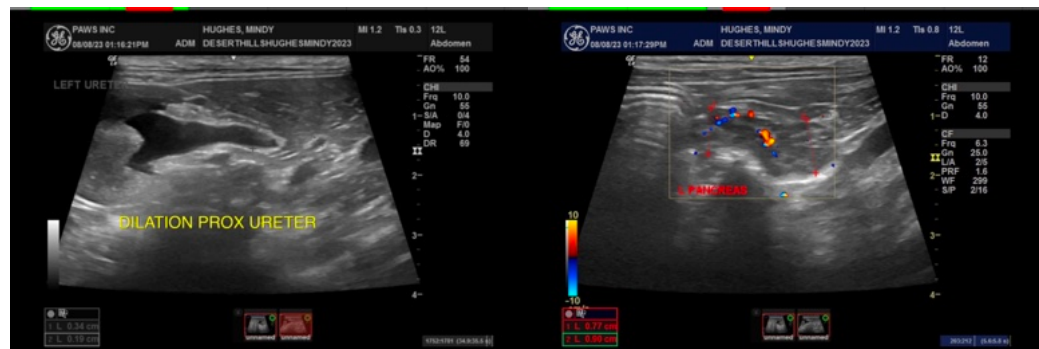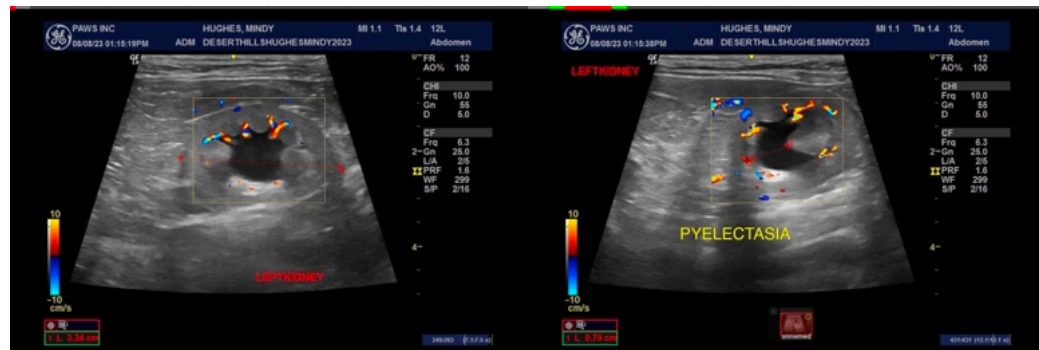
**DATE**

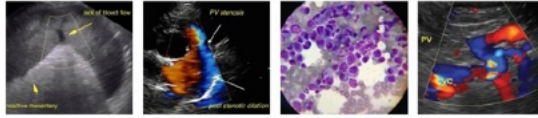
8/8/2023

could consider stenting or bypass procedure. If no significant obstructive process is present at this time this could be due to previous injury.

The pancreas is somewhat prominent and mottled. The significance of this is unclear. If GI signs develop or the patient is not doing well consider correlation with a qualitative fPLI level.

Recommend a urine analysis, culture, and blood pressure evaluation (I believe a urine culture already has been performed).





**PATIENT**

Mindy Hughes

**SPECIES**

Feline

**BREED**

DLH

**SEX**

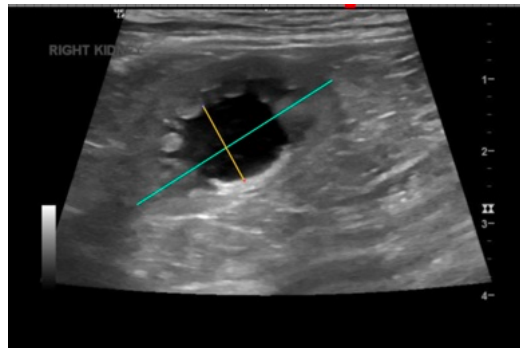
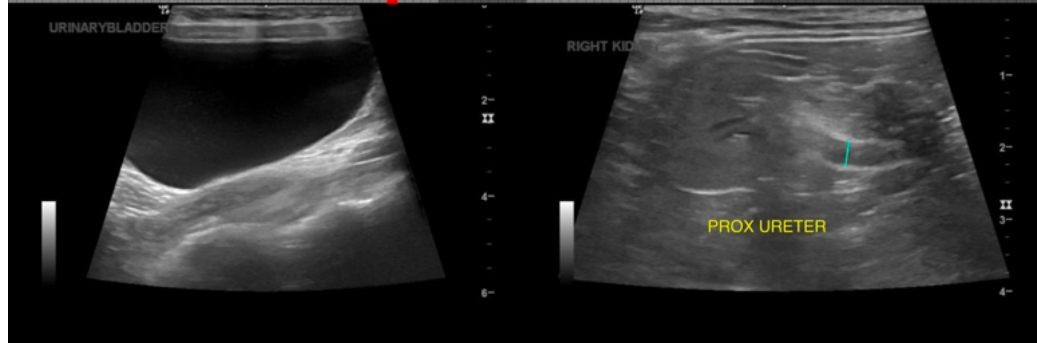
Spayed Female

**AGE**

10/05/2017

**WEIGHT**

3.75 kg



**INTERPRETED BY**

Kathleen Sennello DVM,  
MS, Diplomate ACVIM  
(Small Animal Internal  
Medicine)

**IMAGING  
PERFORMED BY**

Loetitia Saint-Jacques,  
LVT

**HOSPITAL NAME**

Desert Hills AH

**REFERRING VET**

Dr. Jen Vittori

**INVOICE**

10391

**DATE**

8/8/2023

The information and recommendations provided are based on the images presented by the referring veterinarian/sonographer. No evaluation can be communicated regarding pathology that was not visible in the image/video clips provided.

Thank you for this referral. If the clinical or image interpretation does not parallel your findings or if I can be of any further assistance, please contact me.

Kathleen Sennello DVM, MS, Diplomate ACVIM (Small animal Internal Medicine)

info@sonopath.com