



PATIENT

Donatella Castano

PRESENTING CLINICAL SIGNS

Elevated liver enzymes.
Abnormal PE/Chem/CBC/UA Results: ALP 270 and ALT 598.

SPECIES

Canine

ULTRASONOGRAPHIC EXAMINATION OF THE ABDOMEN

Urinary System

BREED

Pekingese

The urinary bladder is moderately distended with anechoic urine. The Bladder wall, trigone, ureteral papillae and visible urethra (to a depth of 2cm) appear normal with no evidence of wall thickening, mucosal irregularities, masses or cystic calculi.

SEX

Spayed Female

The left kidney has a normal shape and size (4.4 cm). Overall echogenicity is slightly hyperechoic with poor corticomedullary distinction and a typical 1:3 cortex:medulla ratio. There is no evidence of perinephric inflammation or effusion. There is no evidence of pyelectasia, nephroliths, infarcts or hydroureter. Renal vasculature is normal.

AGE

14 Years

The right kidney has a normal shape and size (4.39 cm). Overall echogenicity is slightly hyperechoic with poor corticomedullary distinction and a typical 1:3 cortex:medulla ratio. There is no evidence of perinephric inflammation or effusion. There is no evidence of pyelectasia, nephroliths, infarcts or hydroureter. Renal vasculature is normal.

WEIGHT

18 Pounds

Adrenal Glands

The left adrenal gland is normal in size measuring 0.58 cm at the caudal pole. It is observed in its normal position cranial to the left renal artery. It is normal in appearance (uniformly hypoechoic) and shape with no evidence of a mass effect.

INTERPRETED BY

Kathleen Sennello DVM,
MS, Diplomate ACVIM
(Small Animal Internal
Medicine)

The right adrenal gland is normal in size measuring 0.41 cm at the caudal pole. It is observed in its normal position between the cranial aspect of the right kidney and the caudal vena cava. It is normal in appearance (uniformly hypoechoic) and shape with no evidence of a mass effect.

Spleen

The spleen is subjectively normal in size, echotexture is homogenous, and the splenic capsule is smooth with no irregularities. The blood flow through the hilus and splenic parenchyma appears normal. No focal parenchymal abnormalities are visualized.

IMAGING PERFORMED BY

Kelly Vazquez

Liver

HOSPITAL NAME

Glen Rock VH

The liver is small and irregular. The parenchyma is heterogenous in echotexture with subtle, indistinct focal mottling. The visible portions of the vasculature and biliary tract appear normal. No focal nodules or cystic lesions are observed.

REFERRING VET

Dr. Scott Stekler

The gall bladder lumen is moderately distended. The wall of the gall bladder is not thickened and has a smooth mucosal surface. There is a mild amount of non-organized echogenic debris. The cystic and common bile ducts are normal/not visible.

Gastrointestinal

INVOICE

40169

The stomach is mildly dilated with fluid and irregular shadowing material most consistent with normal ingesta and gas. It measures at a normal thickness of <0.7cm with some variability due to the presence of rugal folds. The distinction of the gastric wall layering is adequate and there is no impression of reduced peristaltic activity. No masses or focal lesions were observed.

DATE

8/4/22



PATIENT

Donatella Castano

The visualized areas of duodenum, jejunum and ileum have a relatively uniform diameter with minimal fluid distension. Wall thickness is normal. Bowel loops follow a curvilinear path with distinct wall layering maintaining the typical 1:3 muscularis:mucosa layer ratio. Duodenum wall measured 0.36 cm. Jejunum wall measured 0.29 cm. Visualized peristalsis appears appropriate. There were no focal lesions consistent with obstruction or a mass effect observed.

SPECIES

Canine

The ileocecal junction was visualized and exhibited normal intact wall layering and is subjectively of normal thickness. Sections of colon are visualized with formed fecal material and gas shadowing distally. There is no observed focal or generalized colon wall thickening or loss of layering.

BREED

Pekingese

Pancreas

The pancreas is normal and isoechoic to surrounding mesentery. There is no evidence of nodules or cystic lesions. There is no evidence of regional mesenteric inflammation or fluid.

SEX

Spayed Female

Free Abdomen

Evaluation of the peritoneal cavity did not reveal any evidence of effusion, or subjective lymphadenomegaly. The Medial iliac nodes appear normal and there was no evidence of a caudal aortic thrombus at the bifurcation. The omentum is of normal uniform echogenicity.

AGE

14 Years

PRIMARY FINDINGS

- Small, irregular, heterogeneous liver – The diffuse hepatic changes are non-specific and could be consistent with vacuolar hepatopathy, nodular hyperplasia, inflammatory/immune-mediated disease, fibrosis, extramedullary hematopoiesis, toxic hepatopathy (e.g., copper), infiltrative neoplasia (less likely) or other hepatopathy.
- Mildly reduced corticomedullary distinction in both kidneys – The bilateral renal findings are consistent with age-related change.

WEIGHT

18 Pounds

SECONDARY FINDINGS

- Mild gallbladder debris – The significance of the aggregated gallbladder sludge is unclear. This could represent an early mucocele, cholestasis, or may be secondary to fasting.
- Mild fluid dilation of the gastric lumen – most consistent with ingesta.

INTERPRETED BY

Kathleen Sennello DVM,
MS, Diplomate ACVIM
(Small Animal Internal
Medicine)

INTERPRETATION OF THE FINDINGS & FURTHER RECOMMENDATIONS

The liver appears subjectively small and heterogeneous with an almost nodular silhouette. These are somewhat non-specific findings. Consider:

- Pre- and post-prandial bile acids to evaluate liver function.
- Screening for Leptospirosis if clinically appropriate.
- If liver function is abnormal, liver biopsy would likely be indicated. Based on the small size, I think a fine needle aspirate would be less helpful. If bile acids are significantly off, and a biopsy is not possible, then recommend supportive care for possible non-specific liver disease, etc. with Denamarin, Ursodiol, GI protectants, nausea meds, +/- low protein diet.

IMAGING PERFORMED BY

Kelly Vazquez

HOSPITAL NAME

Glen Rock VH

REFERRING VET

Dr. Scott Stekler

INVOICE

40169

DATE

8/4/22



PATIENT

Donatella Castano

SPECIES

Canine

BREED

Pekingese

SEX

Spayed Female

AGE

14 Years

WEIGHT

18 Pounds

INTERPRETED BY

Kathleen Sennello DVM,
MS, Diplomate ACVIM
(Small Animal Internal
Medicine)

**IMAGING
PERFORMED BY**

Kelly Vazquez

HOSPITAL NAME

Glen Rock VH

REFERRING VET

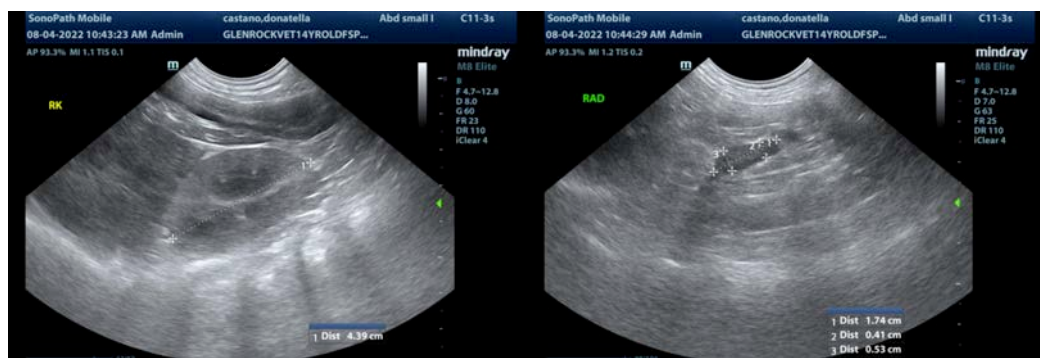
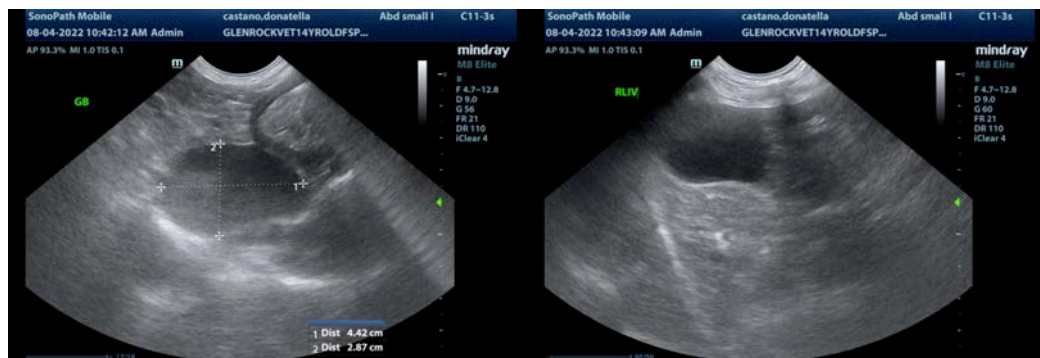
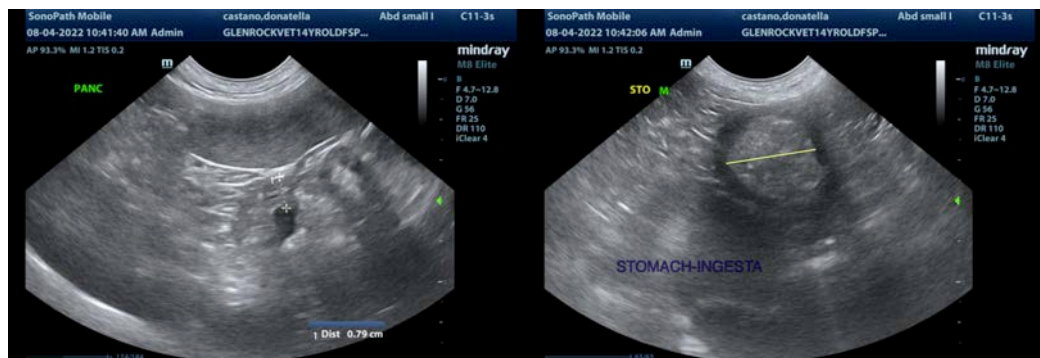
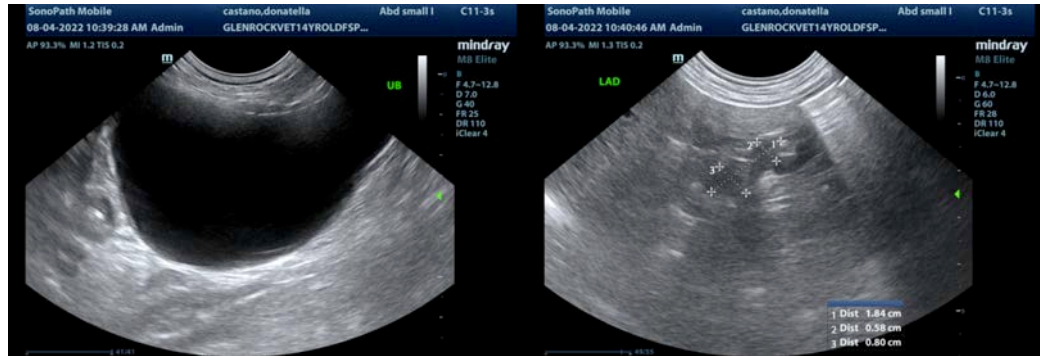
Dr. Scott Stekler

INVOICE

40169

DATE

8/4/22





PATIENT

Donatella Castano

SPECIES

Canine

BREED

Pekingese

SEX

Spayed Female

AGE

14 Years

WEIGHT

18 Pounds

INTERPRETED BY

Kathleen Sennello DVM,
MS, Diplomate ACVIM
(Small Animal Internal
Medicine)

**IMAGING
PERFORMED BY**

Kelly Vazquez

HOSPITAL NAME

Glen Rock VH

REFERRING VET

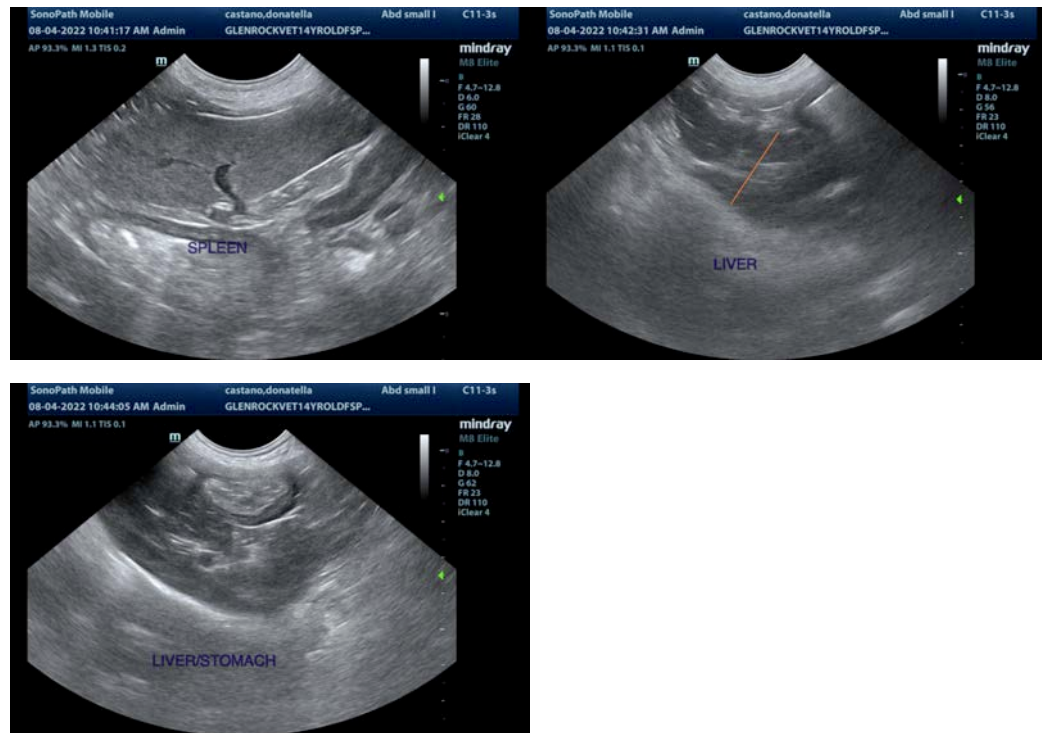
Dr. Scott Stekler

INVOICE

40169

DATE

8/4/22



The information and recommendations provided are based on the images presented by the referring veterinarian/sonographer. No evaluation can be communicated regarding pathology that was not visible in the image/video clips provided.

Thank you for this referral. If the clinical or image interpretation does not parallel your findings or if I can be of any further assistance please contact me.

Kathleen Sennello DVM,MS, Diplomate ACVIM (Small animal Internal Medicine)

kathleen.sennello@sonopath.com