



PATIENT

Jake Sanchez

PRESENTING CLINICAL SIGNS

P presented for wellness exam. Had been going to another DVM in town. P is currently in Apoquel but had been receiving Vetalog injections q 2-3 months. Last recorded injection administered in 4/2021. P was also dispensed TrizEDTA ear flush w DexSP added to it on 7/12/2022.

SPECIES

Canine

Abnormal PE/Chem/CBC/UA Results: 8/23/2022: CBC: WNL, Chem: ALP: 919H, choles: 502H, T4: 2.0, UA: SG: 1.025, quiet sediment, non fasted sample 8/2021: partial CBC: WNL, brief Chem: ALP: 512 8/2020: CBC: mild leukopenia, brief Chem: ALP: 245H

BREED

Golden Retriever

ULTRASONOGRAPHIC EXAMINATION OF THE ABDOMEN

Urinary System

SEX

Neutered Male

The urinary bladder is moderately distended with anechoic urine. The Bladder wall, trigone, ureteral papillae and visible urethra (to a depth of 2cm) appear normal with no evidence of wall thickening, mucosal irregularities, masses or cystic calculi.

AGE

12 Years

The visualized areas of prostate and surrounding tissue appear normal. Unfortunately, the prostate is not fully visualized likely due to its intrapelvic location. Correlate with rectal exam findings.

WEIGHT

61 Pounds

The left kidney has a normal shape and size (6.61 cm). Overall echogenicity is normal with adequate corticomedullary distinction and a typical 1:3 cortex:medulla ratio. There is no evidence of focal perinephric inflammation or effusion. There is no evidence of pyelectasia, nephroliths, infarcts or hydroureter. Renal vasculature is normal.

The right kidney has a normal shape and size (6.51 cm). Overall echogenicity is normal with adequate corticomedullary distinction and a typical 1:3 cortex:medulla ratio. There is no evidence of focal perinephric inflammation or effusion. There is no evidence of pyelectasia, nephroliths, infarcts or hydroureter. Renal vasculature is normal.

INTERPRETED BY

Kathleen Sennello DVM,
MS, Diplomate ACVIM
(Small Animal Internal
Medicine)

Adrenal Glands

The left adrenal gland is normal in size measuring 0.50 cm at the caudal pole. It is observed in its normal position cranial to the left renal artery. It is normal in appearance (uniformly hypoechoic) and shape with no evidence of a mass effect.

IMAGING

PERFORMED BY

Dr. Megan Cassels-
Conway

The right adrenal gland is large measuring 2.02 cm at the cranial pole, 0.73 cm at the caudal pole, and 4.01 cm in length. It is observed in its normal position between the cranial aspect of the right kidney and the caudal vena cava. It is abnormal in that it is large and the cranial pole is significantly increased in size. There is no evidence of vascular invasion visualized.

HOSPITAL NAME

Central Broward AH

Spleen

The spleen is subjectively normal in size, echotexture is homogenous, and the splenic capsule is smooth with no irregularities. The blood flow through the hilus and splenic parenchyma appears normal. No focal parenchymal abnormalities are visualized.

REFERRING VET

Dr. Janeen Lezcano

Liver

The liver is subjectively normal in size, and echogenicity with smooth peripheral margins. The parenchyma is heterogenous in echotexture with subtle, indistinct focal mottling. The visible portions of the vasculature and biliary tract appear normal. No focal nodules or cystic lesions are observed.

INVOICE

40932

DATE

8/31/22



PATIENT

Jake Sanchez

The gallbladder lumen is moderately distended. The wall of the gall bladder is not thickened and has a smooth mucosal surface. Luminal contents are mild and primarily anechoic. The cystic and common bile ducts are normal/not visible.

SPECIES

Canine

Gastrointestinal

The stomach contains minimal luminal contents. It measures at a normal thickness of <0.7cm with some variability due to the presence of rugal folds. The distinction of the gastric wall layers is adequate and there is no impression of reduced peristaltic activity. No masses or focal lesions were observed.

BREED

Golden Retriever

The visualized areas of duodenum, jejunum and ileum have a relatively uniform diameter with minimal fluid distension. Wall thickness is normal. Bowel loops follow a curvilinear path with distinct wall layering maintaining the typical 1:3 muscularis:mucosa layer ratio. The duodenum measured as normal (between 0.3-0.5cm in wall thickness) and the jejunum measured as normal (between 0.2-0.47cm.)

SEX

Neutered Male

Visualized peristalsis appears appropriate. There were no focal lesions consistent with obstruction or a mass effect observed.

AGE

12 Years

The ileocecal junction was visualized and exhibited normal intact wall layering and is subjectively of normal thickness. Sections of colon are visualized with formed fecal material and gas shadowing distally. There is no observed focal or generalized colon wall thickening or loss of layering.

Pancreas

The pancreas is normal and isoechoic to surrounding mesentery. There is no evidence of nodules or cystic lesions. There is no evidence of regional mesenteric inflammation or fluid.

WEIGHT

61 Pounds

Free Abdomen

Evaluation of the peritoneal cavity did not reveal any evidence of effusion, or subjective lymphadenomegaly. The Medial iliac nodes appear normal and there was no evidence of a caudal aortic thrombus at the bifurcation. The omentum is of normal uniform echogenicity.

INTERPRETED BY

Kathleen Sennello DVM,
MS, Diplomate ACVIM
(Small Animal Internal
Medicine)

ULTRASONOGRAPHIC FINDINGS

- Large right adrenal gland - Right adrenomegaly could be consistent with neoplasia (e.g., adenoma, carcinoma, pheochromocytoma), hyperplasia, inflammation, other.
- Heterogeneous liver - The diffuse hepatic changes are non-specific and could be consistent with vacuolar hepatopathy, nodular hyperplasia, inflammatory/immune-mediated disease, fibrosis, extramedullary hematopoiesis, toxic hepatopathy (e.g., copper), infiltrative neoplasia (less likely) or other hepatopathy.

IMAGING PERFORMED BY

Dr. Megan Cassels-Conway

HOSPITAL NAME

Central Broward AH

INTERPRETATION OF THE FINDINGS & FURTHER RECOMMENDATIONS

There is an enlargement of the cranial pole of the right adrenal gland. This is most consistent with a small adrenal mass. There does not appear to be any evidence of vascular invasion visualized, but unfortunately this is still possible. These masses can be benign or malignant and can secrete or be non-active. Options moving forward include:

REFERRING VET

Dr. Janeen Lezcano

- If signs of cushings are present, consider adrenal function testing. I prefer an ACTH stimulation test combined with an adrenal panel to the University of Tennessee's endocrine lab to look for atypical adrenal hormones as well as cortisol. (other testing can suffice)
- If adrenal dependent cushings is suspected and supported by adrenal function testing consider medical therapy with lysodren or trilostane or consider surgical removal (recommend referral

INVOICE

40932

DATE

8/31/22



PATIENT

Jake Sanchez

to a board certified veterinary surgeon and possible pre op CT)

- Recommend blood pressure evaluation-if hypertensive consider testing catecholamine levels for a possible pheochromocytoma

SPECIES

Canine

- If no symptoms of cushings are present, consider either referral for surgery or continued monitoring with ultrasound (in 3-4 months).

BREED

Golden Retriever

- Many of these nodules can be benign and incidental in nature, unfortunately that is difficult to determine with a single ultrasound.

SEX

Neutered Male

The liver is somewhat heterogeneous. I suspect this is consistent with a vacuolar hepatopathy. Consider pre- and post-prandial bile acids to make sure there is no significant issues with liver function.

Recommend three view thoracic radiographs to evaluate for possible concurrent thoracic disease/involvement.

AGE

12 Years

WEIGHT

61 Pounds

INTERPRETED BY

Kathleen Sennello DVM,
MS, Diplomate ACVIM
(Small Animal Internal
Medicine)

IMAGING PERFORMED BY

Dr. Megan Cassels-
Conway

HOSPITAL NAME

Central Broward AH

REFERRING VET

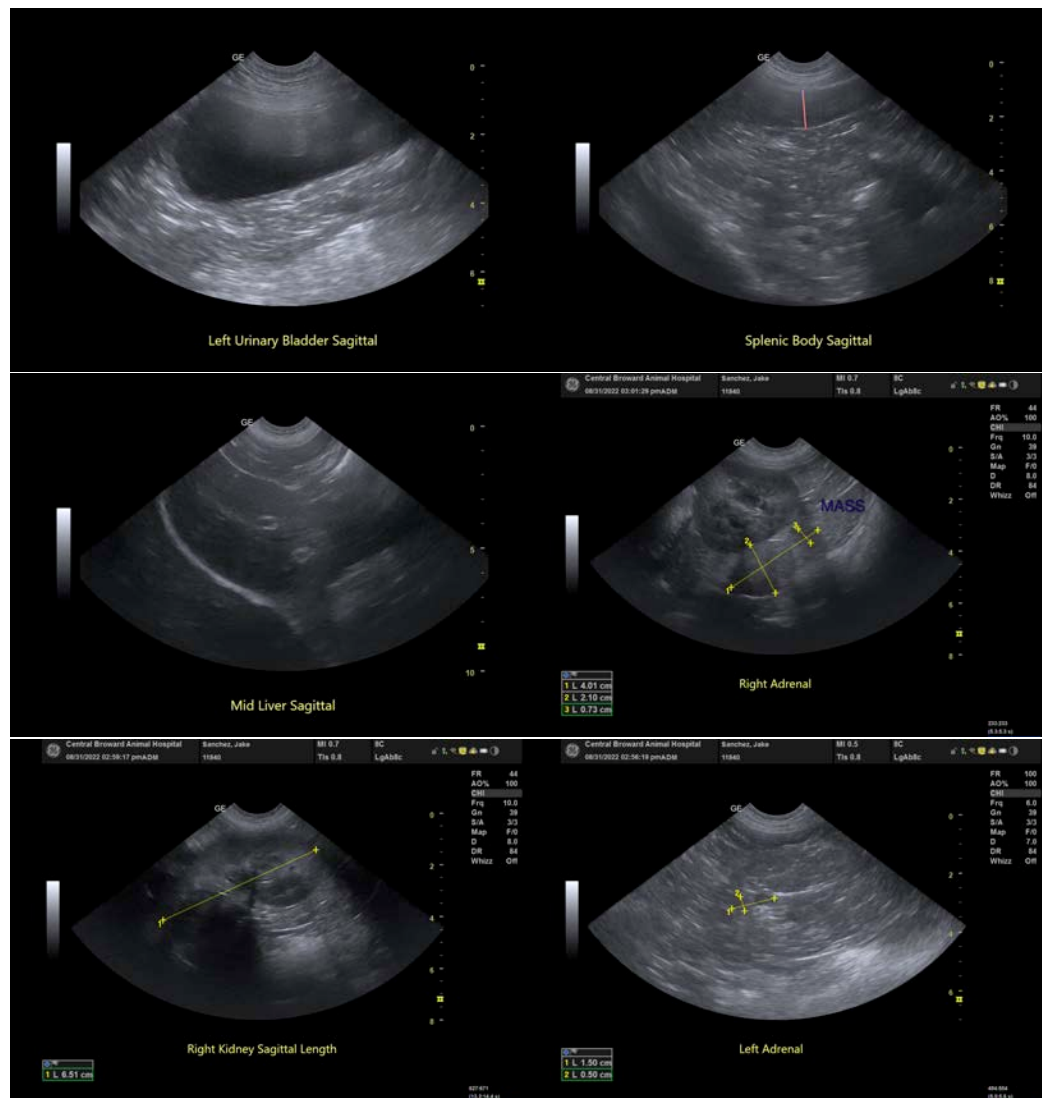
Dr. Janeen Lezcano

INVOICE

40932

DATE

8/31/22





PATIENT

Jake Sanchez

SPECIES

Canine

BREED

Golden Retriever

SEX

Neutered Male

AGE

12 Years

WEIGHT

61 Pounds

INTERPRETED BY

Kathleen Sennello DVM,
MS, Diplomate ACVIM
(Small Animal Internal
Medicine)

**IMAGING
PERFORMED BY**

Dr. Megan Cassels-
Conway

HOSPITAL NAME

Central Broward AH

REFERRING VET

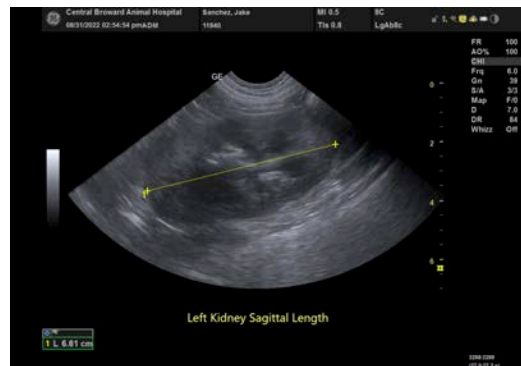
Dr. Janeen Lezcano

INVOICE

40932

DATE

8/31/22



The information and recommendations provided are based on the images presented by the referring veterinarian/sonographer. No evaluation can be communicated regarding pathology that was not visible in the image/video clips provided.

Thank you for this referral. If the clinical or image interpretation does not parallel your findings or if I can be of any further assistance please contact me.

Kathleen Sennello DVM,MS, Diplomate ACVIM (Small animal Internal Medicine)

kathleen.sennello@sonopath.com