



**PATIENT PRESENTING CLINICAL SIGNS**

Elfie Yu  
anorexia, diarrhea, vomiting, hx of hematuria, Meds: mirtazapine, fortiflora, Eradia metronidazole, cerenia, buprenorphine. Still not eating well with appetite stimulants.  
Abnormal PE/Chem/CBC/UA Results: please see attached rads and bloodwork.

**SPECIES**

Feline

**ULTRASONOGRAPHIC EXAMINATION OF THE ABDOMEN**

**BREED**

Ragdoll

**Urinary System**

The urinary bladder is moderately distended with mild primarily suspended echogenic debris and some dependent shadowing/sandy debris present. The Bladder wall, trigone, ureteral papillae and visible urethra (to a depth of 2cm) appear normal with no evidence of wall thickening, mucosal irregularities, masses or calculi. Echogenic debris of this type can be associated with small crystals, sandy debris or small calculi. Correlate findings with abdominal radiographs, urinalysis and culture.

**SEX**

Neutered Male

The left kidney is normal in size (3.01 cm) and irregular in shape. Overall echogenicity is normal with adequate corticomedullary distinction and a typical 1:3 cortex:medulla ratio. There is an ill-defined hyperechoic mass effect/lesion at the caudal pole of the kidney measuring approximately 2.25 cm x 1.87 cm. It appears to extend beyond the caudal pole of the left kidney, but the parenchyma in that area is also hyperechoic and mottled. The kidney itself appears blunted and squared off in this region. There is no evidence of perinephric effusion. There is no evidence of pyelectasia or hydroureter. Small nephroliths are evident, and the appearance of the caudal pole could be somewhat consistent with an infarct and secondary mass effect. Renal vasculature appears normal.

**AGE**

3.5 Years

**WEIGHT**

4.34 kg

The right kidney has a normal shape and size (3.84 cm). Overall echogenicity is normal with adequate corticomedullary distinction and a typical 1:3 cortex:medulla ratio. There is no evidence of focal perinephric inflammation or effusion. There is no evidence of pyelectasia, nephroliths, infarcts or hydroureter. Renal vasculature is normal.

**INTERPRETED BY**

Eric Lindquist, DMV

DABVP, Cert. IVUSS

**Adrenal Glands**

The left adrenal gland is normal in size measuring 0.34 cm at the caudal pole. It is observed in its normal position cranial to the left renal artery. It is normal in appearance (uniformly hypoechoic) and shape with no evidence of a mass effect.

**IMAGING PERFORMED BY**

Crystal Hill

The right adrenal gland is normal in size measuring 0.39 cm at the caudal pole. It is observed in its normal position between the cranial aspect of the right kidney and the caudal vena cava. It is normal in appearance (uniformly hypoechoic) and shape with no evidence of a mass effect.

**HOSPITAL NAME**

Oxford County VC

**Spleen**

The spleen is borderline large (1.0 cm), echotexture is homogenous, and the splenic capsule is smooth with no irregularities. The blood flow through the hilus and splenic parenchyma appears normal. No focal parenchymal abnormalities are visualized.

**REFERRING VET**

Dr. Halfon/Bridge

**Liver**

**INVOICE**

40907

The liver is subjectively normal in size, and echogenicity with smooth peripheral margins. The parenchyma is homogenous echotexture. The visible portions of the vasculature and biliary tract appear normal. No focal nodules or cystic lesions are observed.

**DATE**

8/31/22

The gallbladder lumen is moderately distended. The wall of the gall bladder is not thickened and has a smooth mucosal surface. Luminal contents are mild and primarily anechoic. The cystic and common bile ducts are normal/not visible.



**PATIENT**

***Gastrointestinal***

Elfie Yu

The stomach contains moderate shadowing debris. It measures at a normal thickness of <0.36cm with some variability due to the presence of rugal folds. The distinction of the gastric wall layers is adequate and there is no impression of reduced peristaltic activity. No masses or focal lesions were observed.

**SPECIES**

Feline

The visualized areas of duodenum, jejunum and ileum have a relatively uniform diameter with minimal fluid distension. Wall thickness is normal. Bowel loops follow a curvilinear path with distinct wall layering maintaining the typical 1:3 muscularis:mucosa layer ratio. Jejunum wall measures 0.20 cm.

**BREED**

Ragdoll

Visualized peristalsis appears appropriate. There were no focal lesions consistent with obstruction or a mass effect observed.

**SEX**

Neutered Male

The ileocecal junction was visualized and exhibited normal intact wall layering and is subjectively of normal thickness. Sections of colon are visualized with formed fecal material and gas shadowing distally. There is no observed focal or generalized colon wall thickening or loss of layering.

**AGE**

3.5 Years

***Pancreas***

The pancreas is normal and isoechoic to surrounding mesentery. There is no evidence of nodules or cystic lesions. There is no evidence of regional mesenteric inflammation or fluid.

**WEIGHT**

4.34 kg

***Free Abdomen***

Evaluation of the peritoneal cavity did not reveal any evidence of effusion. There are occasional prominent mesenteric lymph nodes measuring 0.48, 0.32, 0.27 cm. The omentum is slightly hyperechoic around the left kidney.

**ULTRASONOGRAPHIC FINDINGS**

**INTERPRETED BY**

Eric Lindquist, DMV

DABVP, Cert. IVUSS

**IMAGING PERFORMED BY**

Crystal Hill

**HOSPITAL NAME**

Oxford County VC

**REFERRING VET**

Dr. Halfon/Bridge

- Hyperechoic, ill-defined mass effect at the caudal pole of the left kidney – This could represent a true mass effect (benign or neoplastic tumor), or could represent an inflammatory lesion (granuloma, etc.). The area also appears infarcted.
- Hyperechoic shadowing debris in the dependent portion of the urinary bladder – These findings are consistent with small stones/sandy debris. Recommend urinalysis and culture.
- Moderate shadowing ingesta within the gastric lumen – Correlate with feeding history. If this patient was adequately fasted, consider differentials such as delayed gastric emptying, ingested foreign material, hairballs, etc.
- Mildly mesenteric lymphadenopathy – The prominent abdominal lymph nodes are most consistent with reactive lymphadenitis or lymphoid hyperplasia. Neoplastic infiltration is considered less likely.
- Subjectively large spleen – The spleen appears relatively normal other than that it is large. If round cell neoplasia is of concern, consider a fine needle aspirate.

**INTERPRETATION OF THE FINDINGS & FURTHER RECOMMENDATIONS**

**INVOICE**

40907

**DATE**

8/31/22

There is an atypical ill-defined hyperechoic lesion towards the caudal pole of the left kidney. The nature of this lesion is unclear. It could be a true mass effect or an inflammatory lesion. Recommend a fine needle aspirate of this area provided blood pressure and coagulation parameters are normal.

Additionally, there is dependent mineralized debris visualized within the urinary bladder. This is likely sandy debris and small stones. Recommend urinalysis and culture. Consider a liver function test to rule out a portosystemic shunt if there is any concern clinically for a shunt. No evidence of a shunting vessel



**PATIENT**

Elfie Yu

is seen on today's exam, but they can sometimes be small and difficult to clearly visualized.

**SPECIES**

Feline

There is a small amount of shadowing material within the gastric lumen. Correlate with feeding history, medications, etc. If this patient was significantly fasted, consider the possibilities of ingested foreign material, hairballs, etc.

Recommend three view thoracic radiographs to evaluate for possible concurrent thoracic disease/involvement.

**BREED**

Ragdoll

**SEX**

Neutered Male

**AGE**

3.5 Years

**WEIGHT**

4.34 kg

**INTERPRETED BY**

Eric Lindquist, DMV  
DABVP, Cert. IVUSS

**IMAGING PERFORMED BY**

Crystal Hill

**HOSPITAL NAME**

Oxford County VC

**REFERRING VET**

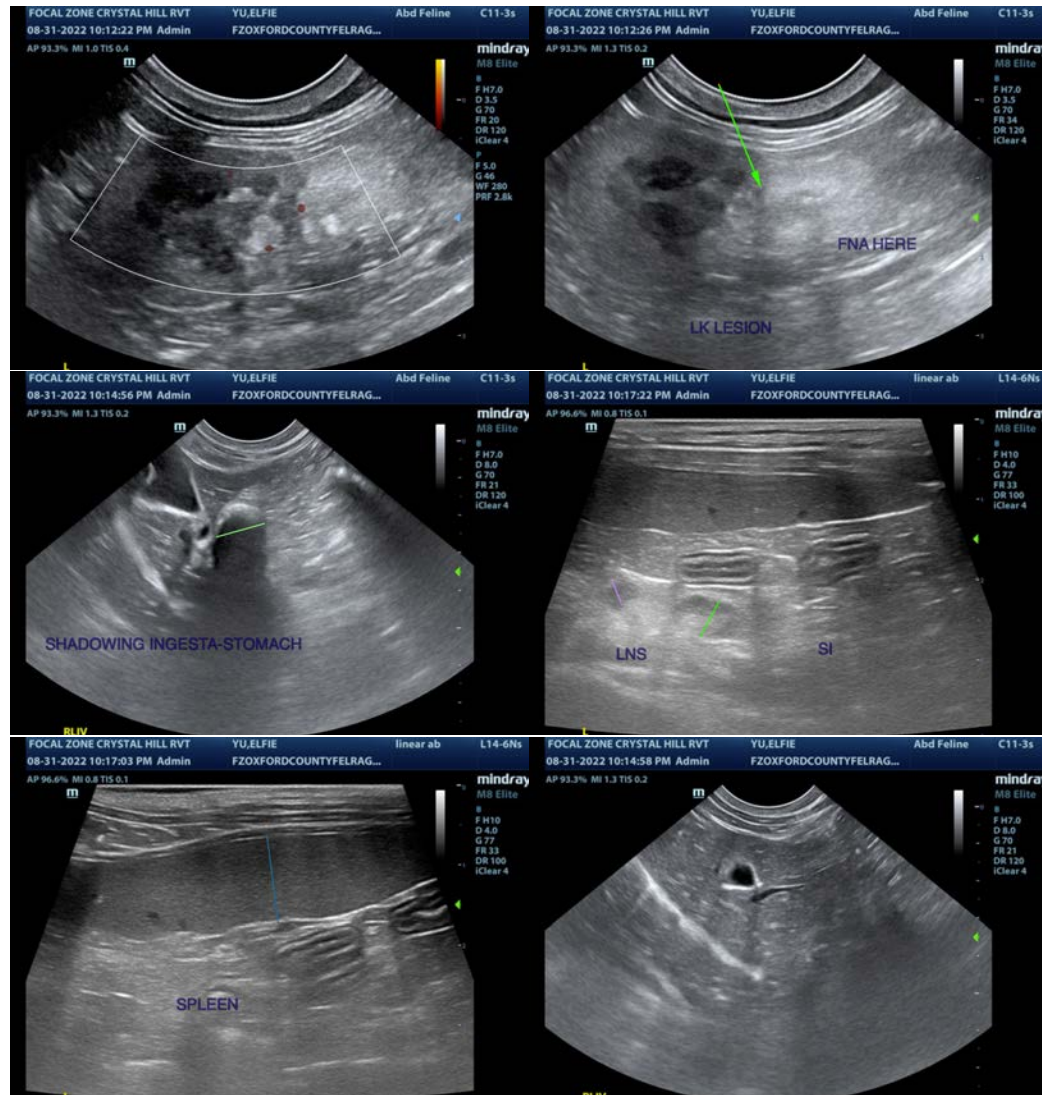
Dr. Halfon/Bridge

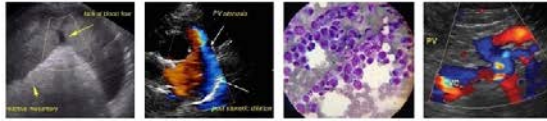
**INVOICE**

40907

**DATE**

8/31/22





**PATIENT**

Elfie Yu

**SPECIES**

Feline

**BREED**

Ragdoll

**SEX**

Neutered Male

**AGE**

3.5 Years

**WEIGHT**

4.34 kg

**INTERPRETED BY**

Eric Lindquist, DMV  
DABVP, Cert. IVUSS

**IMAGING PERFORMED BY**

Crystal Hill

**HOSPITAL NAME**

Oxford County VC

**REFERRING VET**

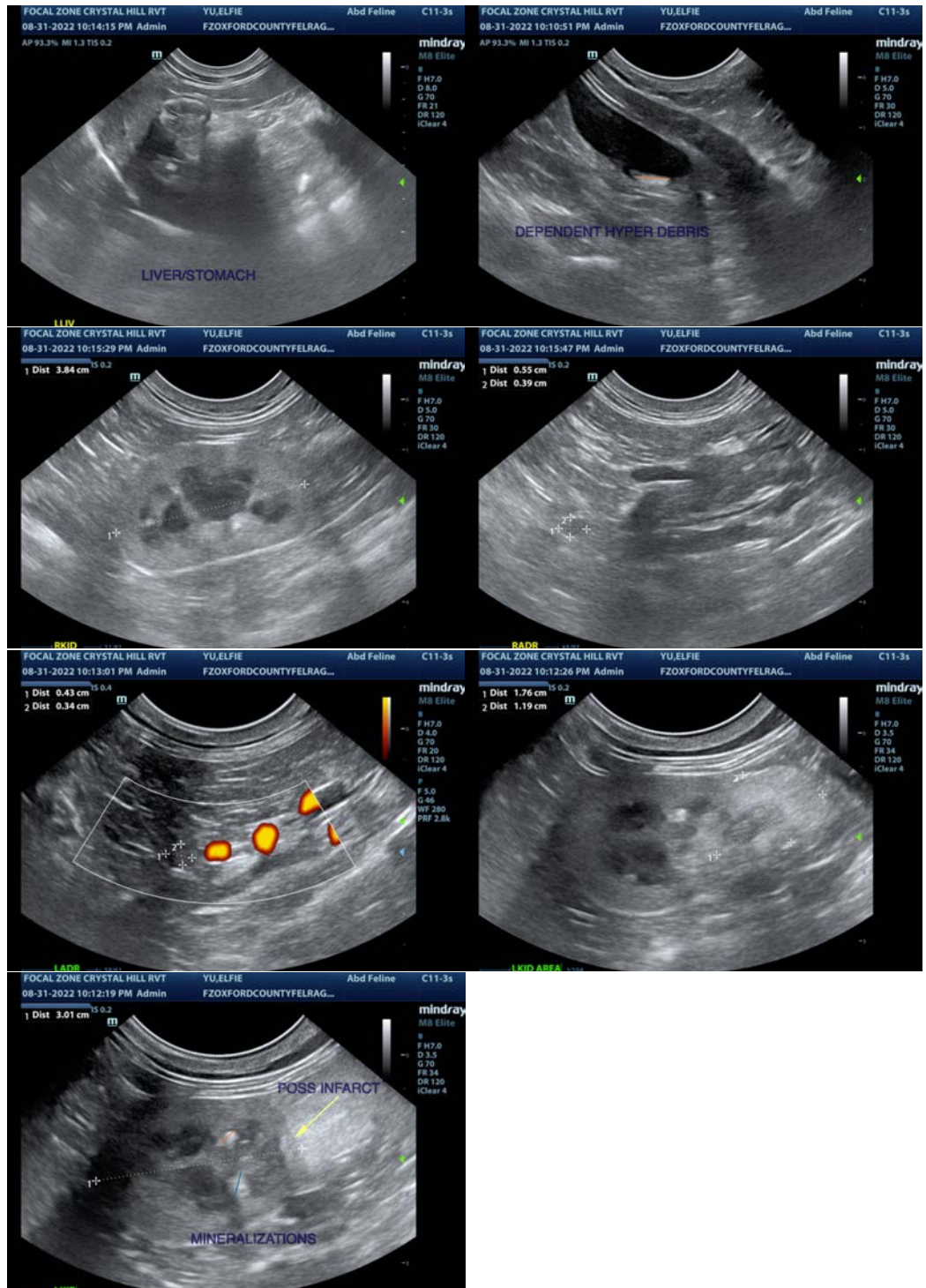
Dr. Halfon/Bridge

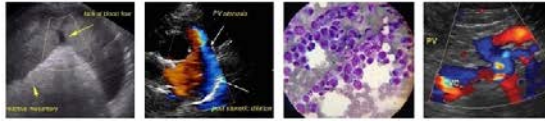
**INVOICE**

40907

**DATE**

8/31/22





**PATIENT**

Elfie Yu

The information and recommendations provided are based on the images presented by the referring veterinarian/sonographer. No evaluation can be communicated regarding pathology that was not visible in the image/video clips provided.

**SPECIES**

Feline

Thank you for this referral. If the clinical or image interpretation does not parallel your findings or if I can be of any further assistance please contact me.

Kathleen Sennello DVM,MS, Diplomate ACVIM (Small animal Internal Medicine)

kathleen.sennello@sonopath.com

**BREED**

Ragdoll

**SEX**

Neutered Male

**AGE**

3.5 Years

**WEIGHT**

4.34 kg

**INTERPRETED BY**

Eric Lindquist, DMV

DABVP, Cert. IVUSS

**IMAGING PERFORMED BY**

Crystal Hill

**HOSPITAL NAME**

Oxford County VC

**REFERRING VET**

Dr. Halfon/Bridge

**INVOICE**

40907

**DATE**

8/31/22