



**PATIENT**

Diana Feierstein

**SPECIES**

Canine

**BREED**

Silky Terrier

**SEX**

Spayed Female

**AGE**

11 Years

**WEIGHT**

13.5 Pounds

**INTERPRETED BY**

Kathleen Sennello DVM,  
MS, Diplomate ACVIM  
(Small Animal Internal  
Medicine)

**IMAGING  
PERFORMED BY**

Dr. Megan Cassels-  
Conway

**HOSPITAL NAME**

Central Broward AH

**REFERRING VET**

Dr. Janeen Lezcano

**INVOICE**

40903

**DATE**

8/31/22

**PRESENTING CLINICAL SIGNS**

P has hx of chronic ALP elevation, hypercalcemia and recent organomegaly (spleen vs liver).  
Abnormal PE/Chem/CBC/UA Results: 7/2022: CBC: plt ct: 466H; Chem: ALP: 850H, Ca: 11.6H, T4: 1.1 UA: SG: 1.014, 2+ prot, quiet sediment 1/2022: CBC: plt ct: 433H, Chem: ALP: 934H, Ca: 12.4H, choles: 336H T4: 1.9, UA: SG: 1.009, 1+ prot, quiet sediment 8/2021: Malignancy panel: PTH: 14.1H, iCa: 1.42, PTH rp: 0 10/2020: AUS w Sonopath: hepatopathy; gall bladder sediment, splenic pathology, uroliths, urinary bladder sediment, enteropathy

**ULTRASONOGRAPHIC EXAMINATION OF THE ABDOMEN**

**Urinary System**

The urinary bladder is moderately distended with anechoic urine. The Bladder wall, trigone, ureteral papillae and visible urethra (to a depth of 2cm) appear normal with no evidence of wall thickening, mucosal irregularities, masses or cystic calculi.

The left kidney has a normal shape and size (4.69 cm). Overall echogenicity is normal with adequate corticomedullary distinction and a typical 1:3 cortex:medulla ratio. There is no evidence of focal perinephric inflammation or effusion. There is no evidence of pyelectasia, nephroliths, infarcts or hydroureter. Renal vasculature is normal.

The right kidney has a normal shape and size (4.55 cm) with a small 0.45 cm non-obstructive nephrolith. Overall echogenicity is normal with adequate corticomedullary distinction and a typical 1:3 cortex:medulla ratio. There is no evidence of focal perinephric inflammation or effusion. There is no evidence of pyelectasia, infarcts or hydroureter. Renal vasculature is normal.

**Adrenal Glands**

The left adrenal gland is normal in size measuring 0.64 cm at the caudal pole. It is observed in its normal position cranial to the left renal artery. It is normal in appearance (uniformly hypoechoic) and shape with no evidence of a mass effect.

The right adrenal gland is normal in size measuring 0.47 cm at the caudal pole. It is observed in its normal position between the cranial aspect of the right kidney and the caudal vena cava. It is normal in appearance (uniformly hypoechoic) and shape with no evidence of a mass effect.

**Spleen**

The spleen is subjectively normal in size, echotexture is homogenous, and the splenic capsule is smooth with no irregularities. The blood flow through the hilus and splenic parenchyma appears normal. No focal parenchymal abnormalities are visualized.

**Liver**

The liver is large with smooth peripheral margins. The parenchyma is hyperechoic and homogenous in echotexture. The visible portions of the vasculature and biliary tract appear normal. No focal nodules or cystic lesions are observed.

The gall bladder lumen is moderately distended. The wall of the gall bladder is not thickened and has a smooth mucosal surface. There is a moderate amount of non-organized echogenic debris. The cystic and common bile ducts are normal/not visible.



**PATIENT**

Diana Feierstein

**Gastrointestinal**

The stomach contains minimal luminal contents. It measures at a normal thickness of <0.7cm with some variability due to the presence of rugal folds. The distinction of the gastric wall layers is adequate and there is no impression of reduced peristaltic activity. No masses or focal lesions were observed.

**SPECIES**

Canine

The visualized areas of duodenum, jejunum and ileum have a relatively uniform diameter with minimal fluid distension. Wall thickness is normal. Bowel loops follow a curvilinear path with distinct wall layering maintaining the typical 1:3 muscularis:mucosa layer ratio. Duodenum wall measures 0.31 cm. Jejunum wall measures 0.27 cm. Visualized peristalsis appears appropriate. There were no focal lesions consistent with obstruction or a mass effect observed.

**BREED**

Silky Terrier

The ileocecal junction was visualized and exhibited normal intact wall layering and is subjectively of normal thickness. Sections of colon are visualized with formed fecal material and gas shadowing distally. There is no observed focal or generalized colon wall thickening or loss of layering.

**SEX**

Spayed Female

**Pancreas**

The pancreas is normal and isoechoic to surrounding mesentery. There is no evidence of nodules or cystic lesions. There is no evidence of regional mesenteric inflammation or fluid.

**AGE**

11 Years

**Free Abdomen**

Evaluation of the peritoneal cavity did not reveal any evidence of effusion, or subjective lymphadenomegaly. The Medial iliac nodes appear normal and there was no evidence of a caudal aortic thrombus at the bifurcation. The omentum is of normal uniform echogenicity.

**WEIGHT**

13.5 Pounds

**ULTRASONOGRAPHIC FINDINGS**

**INTERPRETED BY**

Kathleen Sennello DVM,  
MS, Diplomate ACVIM  
(Small Animal Internal  
Medicine)

- Large, hyperechoic liver – The diffuse hepatic changes are non-specific and can be seen with vacuolar hepatopathy, reactive change, nodular hyperplasia or, less likely, inflammatory/immune-mediated disease, infiltrative neoplasia, or other hepatopathy.
- Moderate gallbladder debris – The significance of the aggregated gallbladder debris is unclear. This could represent an early mucocele, cholestasis, or may be secondary to fasting but seems unlikely to be causing a current issue. Recommend continued monitoring.
- Small non-obstructive nephrolith visualized in the right kidney – A hyperechoic foci is visualized in the kidney most consistent with a nephrolith. There is no current evidence of obstructive disease. Correlate findings with abdominal radiographs, urinalysis, and culture. Continued monitoring is warranted for progression/obstruction.

**IMAGING PERFORMED BY**

Dr. Megan Cassels-Conway

**HOSPITAL NAME**

Central Broward AH

**INTERPRETATION OF THE FINDINGS & FURTHER RECOMMENDATIONS**

No focal lesions are visualized in the liver to explain the elevation in ALP reported. An elevation in ALP is a common finding in general. However, causes of ALP elevation fall into 3 primary categories: Induction phenomena, biliary disease, and primary liver disorders.

**REFERRING VET**

Dr. Janeen Lezcano

- Induction phenomena are the most common cause for an elevation in ALP. These are systemic illnesses that 'turn on' the liver enzyme. Causes of this include Cushing's disease, dental disease, arthritis, and numerous others. In many cases the exact cause is unclear but as long as ultrasound and bile acids tests are normal most patients do not have progressive changes in their liver. While liver biopsy is not routinely performed, vacuolar hepatopathy, is noted on most biopsies. This is often non-progressive but in rare cases can be more severe and lead to liver failure.

**INVOICE**

40903

**DATE**

8/31/22



**PATIENT**

Diana Feierstein

- If signs of cushings disease are present recommend endocrine function testing to evaluate for cushings disease.

**SPECIES**

Canine

- Consider fine needle aspirate to rule out round cell neoplasia -if this is a concern.
- If a cause for the ALP elevation is not identified: I recommend recheck general blood work every 6 months, ultrasound once per year, and bile acids test every 1-2 years based on other results. If the ALP continues to climb a biopsy could be considered.

**BREED**

Silky Terrier

- Consider long term use of denamarin, and monitoring for the signs of cushings developing.

**SEX**

Spayed Female

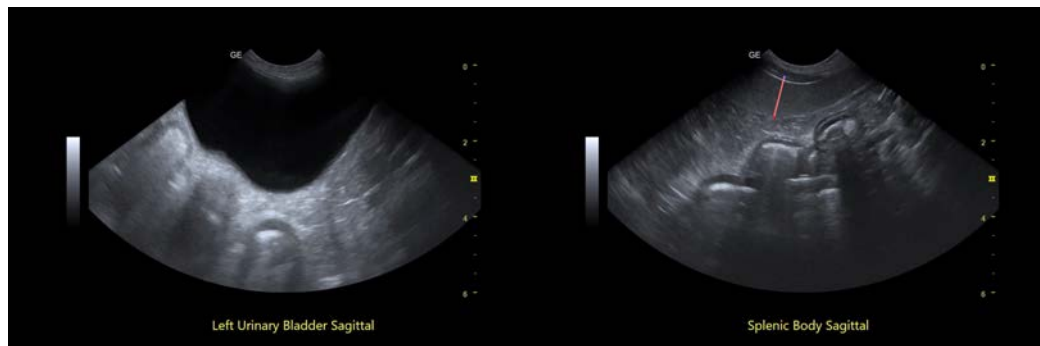
- A primary vacuolar hepatopathy can be breed related and is seen in Scottish Terriers, Schnauzers, Cocker spaniels etc..

**AGE**

11 Years

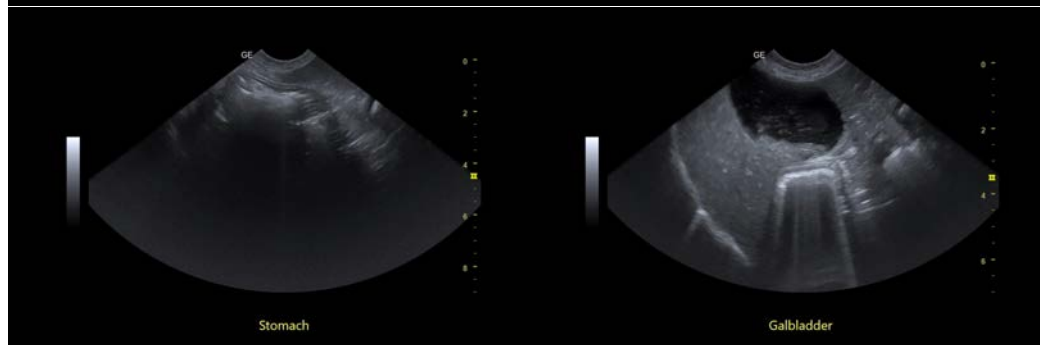
**WEIGHT**

13.5 Pounds



**INTERPRETED BY**

Kathleen Sennello DVM,  
MS, Diplomate ACVIM  
(Small Animal Internal  
Medicine)

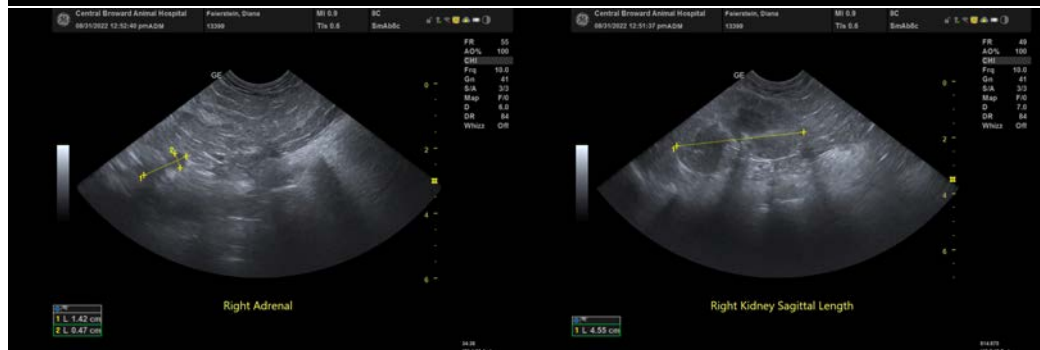


**IMAGING PERFORMED BY**

Dr. Megan Cassels-  
Conway

**HOSPITAL NAME**

Central Broward AH



**REFERRING VET**

Dr. Janeen Lezcano

**INVOICE**

40903

**DATE**

8/31/22



**PATIENT**

Diana Feierstein

**SPECIES**

Canine

**BREED**

Silky Terrier

**SEX**

Spayed Female

**AGE**

11 Years

**WEIGHT**

13.5 Pounds

**INTERPRETED BY**

Kathleen Sennello DVM,  
MS, Diplomate ACVIM  
(Small Animal Internal  
Medicine)

**IMAGING  
PERFORMED BY**

Dr. Megan Cassels-  
Conway

**HOSPITAL NAME**

Central Broward AH

**REFERRING VET**

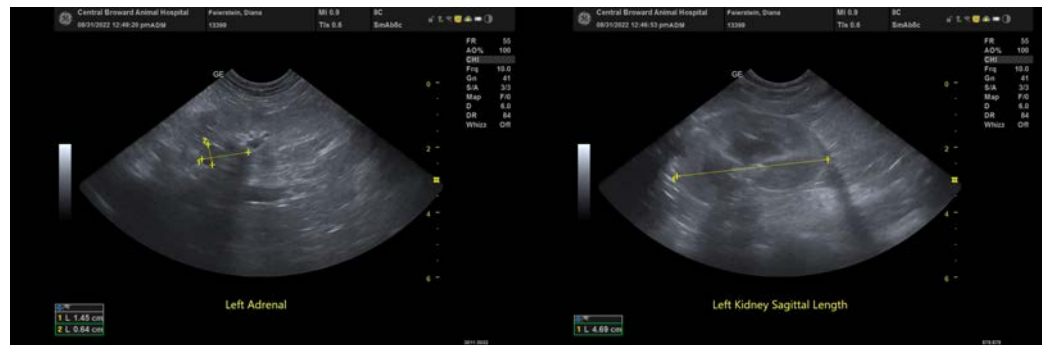
Dr. Janeen Lezcano

**INVOICE**

40903

**DATE**

8/31/22



The information and recommendations provided are based on the images presented by the referring veterinarian/sonographer. No evaluation can be communicated regarding pathology that was not visible in the image/video clips provided.

Thank you for this referral. If the clinical or image interpretation does not parallel your findings or if I can be of any further assistance please contact me.

Kathleen Sennello DVM,MS, Diplomate ACVIM (Small animal Internal Medicine)

kathleen.sennello@sonopath.com