



PATIENT

Charlie Sommer

SPECIES

Feline

BREED

DSH

SEX

Neutered Male

AGE

7 Years

WEIGHT

10 Pounds

INTERPRETED BY

Kathleen Sennello DVM,
MS, Diplomate ACVIM
(Small Animal Internal
Medicine)

**IMAGING
PERFORMED BY**

Shari Reffi, CVT

HOSPITAL NAME

Newton Vet Hospital

REFERRING VET

Dr. Barron

INVOICE

40877

DATE

8/31/22

PRESENTING CLINICAL SIGNS

Bruised fat pads, not eating. Hx liver/splenic dz per rDVM. Current meds: Denamarin, Ursodiol
Abnormal PE/Chem/CBC/UA Results: Chol 281, ALT 228, ALP 112, GGT 10, Tbil 0.5, Neutrophilia

ULTRASONOGRAPHIC EXAMINATION OF THE ABDOMEN

Urinary System

The urinary bladder is moderately distended with anechoic urine. The Bladder wall, trigone, ureteral papillae and visible urethra (to a depth of 2cm) appear normal with no evidence of wall thickening, mucosal irregularities, masses or cystic calculi.

The left kidney has a normal shape and size (4.35 cm). Overall echogenicity is normal with adequate corticomedullary distinction and a typical 1:3 cortex:medulla ratio. There is no evidence of focal perinephric inflammation or effusion. There is no evidence of pyelectasia, nephroliths, infarcts or hydroureter. Renal vasculature is normal.

The right kidney has a normal shape and size (3.71 cm). Overall echogenicity is normal with adequate corticomedullary distinction and a typical 1:3 cortex:medulla ratio. There is no evidence of focal perinephric inflammation or effusion. There is no evidence of pyelectasia, nephroliths, infarcts or hydroureter. Renal vasculature is normal.

Adrenal Glands

The left adrenal gland is normal in size measuring 0.59 cm at the caudal pole. It is observed in its normal position cranial to the left renal artery. It is normal in appearance (uniformly hypoechoic) and shape with no evidence of a mass effect.

The region of the right adrenal (between right cranial kidney and vena cava) is unremarkable, but the adrenal is not distinctly visualized. No evidence of a mass effect.

Spleen

The spleen is large (1.23 cm in width at the level of the hilus), hypoechoic and mildly mottled. The blood flow through the hilus and splenic parenchyma appears normal. No focal parenchymal abnormalities are visualized.

Liver

The liver is subjectively normal in size, and echogenicity with smooth peripheral margins. The parenchyma is heterogenous in echotexture with subtle, indistinct focal mottling. The visible portions of the vasculature and biliary tract appear normal. No focal nodules or cystic lesions are observed.

The gallbladder lumen is moderately distended. The wall of the gall bladder is not thickened and has a smooth mucosal surface. Luminal contents are mild and primarily anechoic. The cystic and common bile ducts are normal/not visible.

Gastrointestinal

The stomach contains minimal luminal contents. It measures at a normal thickness of <0.36cm with some variability due to the presence of rugal folds. The distinction of the gastric wall layers is adequate and there is no impression of reduced peristaltic activity. No masses or focal lesions were observed.



PATIENT

Charlie Sommer

The visualized areas of duodenum, jejunum and ileum have a relatively uniform diameter with minimal fluid distension. Wall thickness is normal. Jejunum wall measured 0.26 cm. Visualized peristalsis appears appropriate. There were no focal lesions consistent with obstruction or a mass effect observed.

SPECIES

Feline

The area of the ileocecal junction was visualized. There appears to be generalized inflammation around the area of the ileocecal junction, and some focal indistinct hypoechoic tissue measuring approximately 1.61 cm. This is associated with an area of dilated bowel with hypoechoic fluid debris suspicious for the cecum. Findings are concerning for cecal distention and inflammation +/- a mass effect.

BREED

Pancreas

DSH

The pancreas is prominent and hypoechoic as compared to the surrounding isoechoic mesentery. There is no evidence of nodules or cystic lesions. There is no evidence of regional mesenteric inflammation or fluid.

SEX

Free Abdomen

Neutered Male

Evaluation of the peritoneal cavity did not reveal any evidence of effusion. There are rare enlarged hypoechoic mesenteric lymph nodes. One such lymph node measures 0.71 cm. The omentum is generally hyperechoic in the region around the ileocecal junction.

AGE

7 Years

Other

A brief view of the heart was submitted. No significant pericardial effusion was seen.

WEIGHT

10 Pounds

ULTRASONOGRAPHIC FINDINGS

- Large, hypoechoic, mottled spleen – The diffuse splenic changes are non-specific and could be consistent with lymphoid hyperplasia, extramedullary hematopoiesis, infiltrative neoplasia, inflammation, other. Cytology or histopathology would be necessary to get a definitive diagnosis.
- Hypoechoic, prominent pancreas – The pancreatic changes are most consistent with mild pancreatitis or a recent episode of pancreatic inflammation.
- Heterogeneous liver – Hepatic changes are non-specific and could be consistent with inflammation/infection (cholangiohepatitis), infiltrative neoplasia, lipidosis or other hepatopathy.
- Prominent, fluid-filled cecum with associated inflammation and abnormal tissue – This could be consistent with typhlitis and associated inflammatory tissue, or there could be an early mass effect.
- Enlarged mesenteric lymph nodes – The prominent abdominal lymph nodes are most consistent with reactive lymphadenitis or lymphoid hyperplasia. Neoplastic infiltration is considered less likely.

INTERPRETED BY

Kathleen Sennello DVM,
MS, Diplomate ACVIM
(Small Animal Internal
Medicine)

IMAGING PERFORMED BY

Shari Reffi, CVT

HOSPITAL NAME

Newton Vet Hospital

REFERRING VET

Dr. Barron

INTERPRETATION OF THE FINDINGS & FURTHER RECOMMENDATIONS

INVOICE

The spleen appears large and hypoechoic with some scalloped edges. Recommend a fine needle aspirate to look for evidence of round cell neoplasia.

40877

The liver is heterogeneous. No focal liver lesions were observed. This is a non-specific finding. Options for further evaluation include:

DATE

8/31/22



PATIENT

Charlie Sommer

- Consider close evaluation of history for possible toxic changes examine medications, diet, dietary indiscretion etc..
- Recommend thyroid evaluation (if not already done)

SPECIES

Feline

- If not already done consider pre and post prandial bile acids to evaluate liver function
- Consider fine needle aspirate if round cell neoplasia is on your differential list (25 g needle, normal coags)

BREED

DSH

- If cytology is not helpful and there is no response to therapy, consider liver biopsy with samples obtained for histopathology and culture.

SEX

Neutered Male

- If triaditis is suspected (chronic GI signs, concurrent pancreatic changes on US) consider therapy for cholangiohepatitis (fluids, ursodiol, probiotics, +/- steroids/antibiotics), testing for pancreatitis and evaluation for IBD (GI panel to Texas A&M GI lab)

AGE

7 Years

The area of the colon is prominent with hyperechoic tissue surrounding. Additionally, there is a fluid filled structure that resembles a fluid dilated cecum and some irregular hypoechoic tissue. This could represent inflammation in the area or an early mass lesion. Additionally, there is non-formed feces throughout the colon. Recommend treatment for large bowel diarrhea, and if cytology of the spleen is not helpful, you could consider a fine needle aspirate of the abnormal tissue adjacent to the cecum, and a mesenteric lymph node.

WEIGHT

10 Pounds

Recommend three view thoracic radiographs to evaluate for possible concurrent thoracic disease/involvement.

INTERPRETED BY

Kathleen Sennello DVM,
MS, Diplomate ACVIM
(Small Animal Internal
Medicine)

IMAGING PERFORMED BY

Shari Reffi, CVT

HOSPITAL NAME

Newton Vet Hospital

REFERRING VET

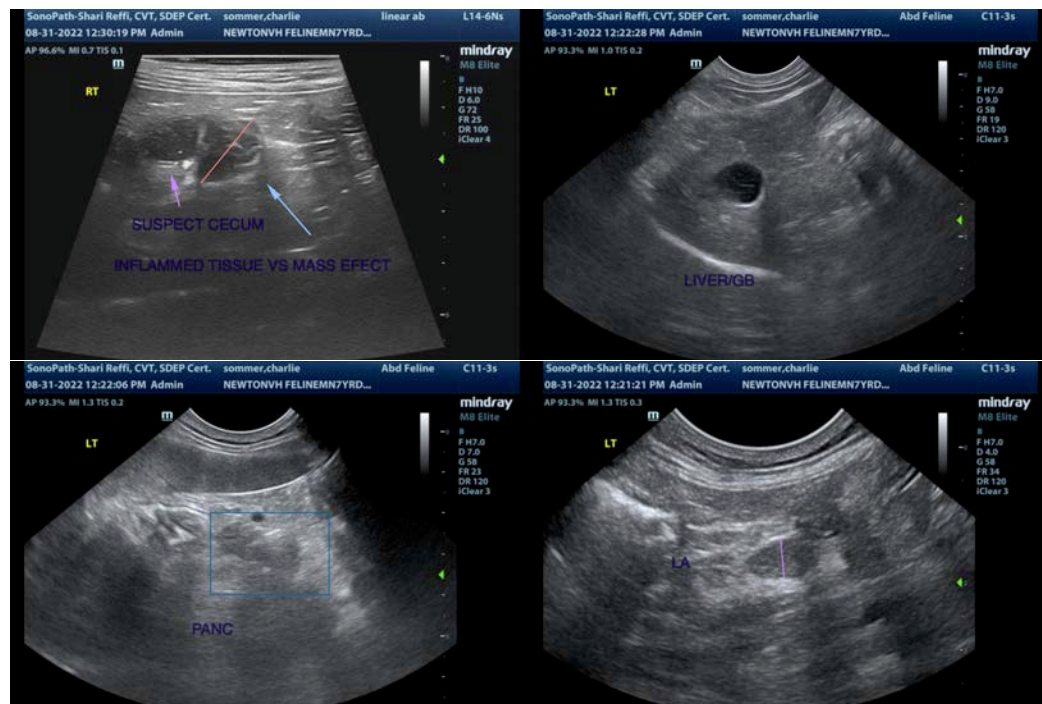
Dr. Barron

INVOICE

40877

DATE

8/31/22





PATIENT

Charlie Sommer

SPECIES

Feline

BREED

DSH

SEX

Neutered Male

AGE

7 Years

WEIGHT

10 Pounds

INTERPRETED BY

Kathleen Sennello DVM,
MS, Diplomate ACVIM
(Small Animal Internal
Medicine)

**IMAGING
PERFORMED BY**

Shari Reffi, CVT

HOSPITAL NAME

Newton Vet Hospital

REFERRING VET

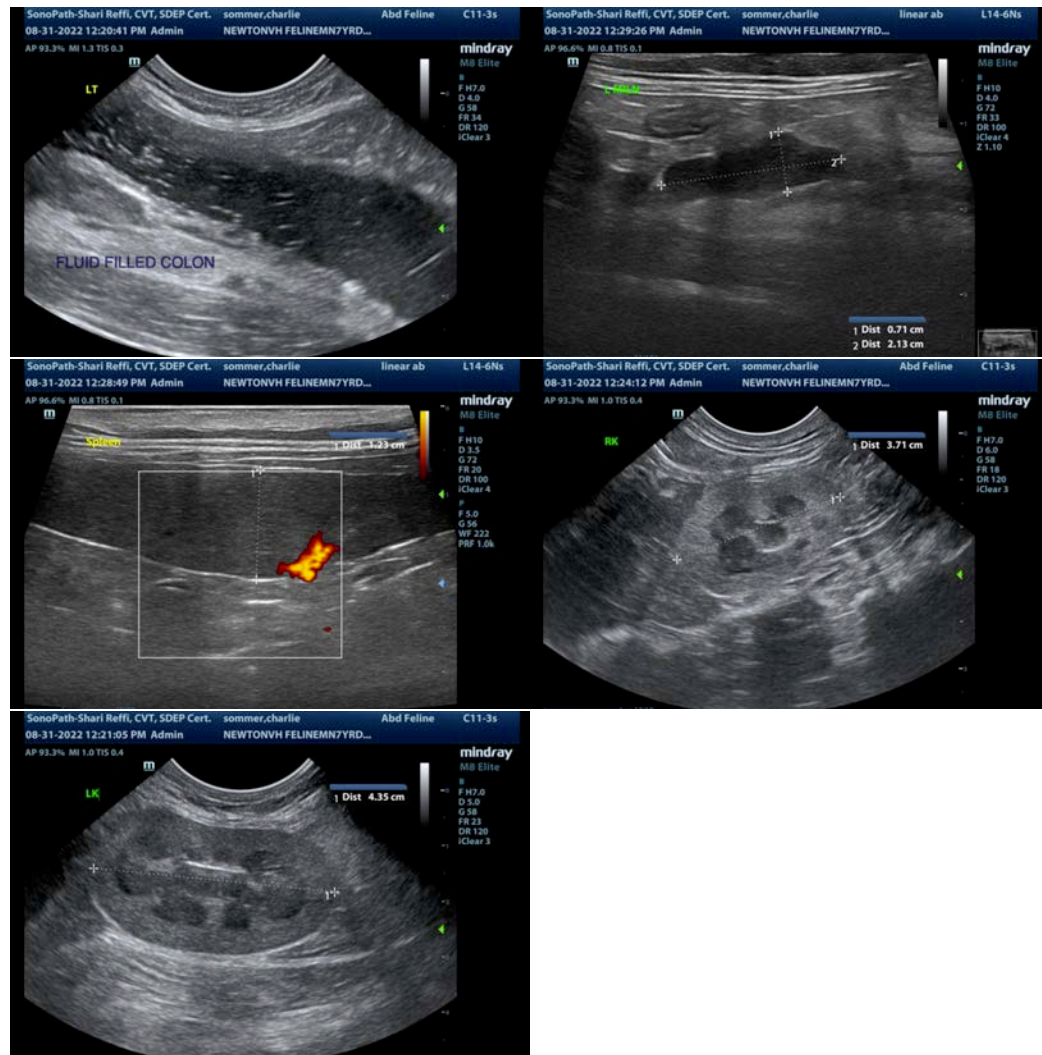
Dr. Barron

INVOICE

40877

DATE

8/31/22



The information and recommendations provided are based on the images presented by the referring veterinarian/sonographer. No evaluation can be communicated regarding pathology that was not visible in the image/video clips provided.

Thank you for this referral. If the clinical or image interpretation does not parallel your findings or if I can be of any further assistance please contact me.

Kathleen Sennello DVM,MS, Diplomate ACVIM (Small animal Internal Medicine)

kathleen.sennello@sonopath.com