



PATIENT

Ziggy Zimmerman

SPECIES

Canine

BREED

Bichon Frise

SEX

Neutered male

AGE

11 years

WEIGHT

13 lbs

INTERPRETED BY

Kathleen Sennello
DVM, MS, Diplomate
ACVIM (Small Animal
Internal Medicine)

IMAGING PERFORMED BY

Dr. Mengine

HOSPITAL NAME

Stoney Creek VH

REFERRING VET

Dr. Mengine

INVOICE

91578

DATE

8/31/21

PRESENTING CLINICAL SIGNS

History: Two week history of intermittent R-sided neck pain. Improved with carprofen, but then developed diarrhea. Carprofen was stopped and bloodwork was checked - ALT 360, ALP 476, GGT 46, TBili 0.4, else normal CBC/ Chem, negative 4dx and fecal.

ULTRASONOGRAPHIC EXAMINATION OF THE ABDOMEN

Urinary System

The urinary bladder is moderately distended with anechoic urine. The Bladder wall, trigone, ureteral papillae and visible urethra (to a depth of 2cm) appear normal with no evidence of wall thickening, mucosal irregularities, masses or cystic calculi.

The prostate is normal in size (0.7 cm) and shape for this neutered male dog. The parenchyma is homogenous and the external margins are smooth. The prostatic urethra appears normal with no evidence of irregularity, invasion, mass effect or calculi.

The left kidney has a normal shape and size (4.68 cm). Overall echogenicity is slightly hyperechoic with poor corticomedullary distinction and a typical 1:3 cortex:medulla ratio. There is no evidence of perinephric inflammation or effusion. The left kidney has non-obstructive nephroliths measuring 0.42 cm and 0.22 cm. There is no evidence of pyelectasia, infarcts or hydroureter. Renal vasculature is normal.

The right kidney has a normal shape and size (4.72 cm). Overall echogenicity is slightly hyperechoic with poor corticomedullary distinction and a typical 1:3 cortex:medulla ratio. There is no evidence of perinephric inflammation or effusion. Non-obstructive nephroliths were noted. There is no evidence of pyelectasia, infarcts or hydroureter. Renal vasculature is normal.

Adrenal Glands

The left adrenal gland is large in size measuring 0.61 cm at the cranial pole and 1.19 cm at the caudal pole and 2.25 cm in length. It is observed in its normal position cranial to the left renal artery. It is irregular in appearance with an enlarged caudal pole, but uniformly hypoechoic. This is consistent with a caudal adrenal nodule.

The right adrenal gland is normal in size measuring 0.62 cm at the cranial pole, 0.44 cm at the caudal pole and 1.8 cm in length. It is observed in its normal position between the cranial aspect of the right kidney and the caudal vena cava. It is normal in appearance (uniformly hypoechoic) and shape with no evidence of a mass effect.

Spleen

The spleen is subjectively normal in size The spleen echotexture is heterogenous and mottled, the splenic capsule is smooth with no irregularities. The blood flow through the hilus and splenic parenchyma appears normal. No focal parenchymal abnormalities are visualized.



PATIENT

Liver

Ziggy Zimmerman

SPECIES

Canine

BREED

Bichon Frise

SEX

Neutered male

AGE

11 years

WEIGHT

13 lbs

The liver is subjectively normal in size, and echogenicity with very irregular peripheral margins. The visible portions of the vasculature and biliary tract appear normal. There are diffuse, irregular, hyperechoic and hypoechoic nodules visualized within the parenchyma deforming the margins. There is a hyperechoic nodule that measured 1.89 cm visualized in the periphery on the left side of the liver. The gallbladder lumen is moderately distended. The wall of the gall bladder is not thickened and has a smooth mucosal surface. Luminal contents are primarily anechoic. The cystic and common bile ducts are normal/not visible.

Gastrointestinal

The stomach contains minimal luminal contents. It measures at a normal thickness of <0.7cm with some variability due to the presence of rugal folds. The distinction of the gastric wall layers is adequate and there is no impression of reduced peristaltic activity. No masses or focal lesions were observed.

The visualized areas of duodenum, jejunum and ileum have a relatively uniform diameter with minimal fluid distension. Wall thickness is normal. Bowel loops follow a curvilinear path with distinct wall layering maintaining the typical 1:3 muscularis:mucosa layer ratio. The duodenum measured as normal (0.36 cm) and the jejunum measured as normal (0.29 cm). Visualized peristalsis appears appropriate. There were no focal lesions consistent with obstruction or a mass effect observed.

The ileocecal junction was visualized and exhibited normal intact wall layering and is subjectively of normal thickness. Sections of colon are visualized with formed fecal material and gas shadowing distally. There is no observed focal or generalized colon wall thickening or loss of layering.

INTERPRETED BY

Kathleen Sennello
DVM, MS, Diplomate
ACVIM (Small Animal
Internal Medicine)

Pancreas

The pancreas is normal and isoechoic to surrounding mesentery. There is no evidence of nodules or cystic lesions. There is no evidence of regional mesenteric inflammation or fluid.

IMAGING PERFORMED BY

Dr. Mengine

Free Abdomen

Evaluation of the peritoneal cavity did not reveal any evidence of effusion, or subjective lymphadenomegaly. The Medial iliac nodes appear normal and there was no evidence of a caudal aortic thrombus at the bifurcation. The omentum is of normal uniform echogenicity.

HOSPITAL NAME

Stoney Creek VH

ULTRASONOGRAPHIC FINDINGS

REFERRING VET

Dr. Mengine

PRIMARY FINDINGS:

- Irregular nodular liver. The diffuse hepatic changes are non-specific and may be consistent with benign change such as nodular hyperplasia, regenerative nodules, etc. It may also be consistent with a primary neoplastic process.
- Nodule in the caudal pole of the left adrenal gland. Adrenomegaly could be consistent with neoplasia (e.g., adenoma, carcinoma, pheochromocytoma), hyperplasia, inflammation, other.

INVOICE

91578

DATE

8/31/21



PATIENT

Ziggy Zimmerman

SPECIES

Canine

BREED

Bichon Frise

SEX

Neutered male

AGE

11 years

WEIGHT

13 lbs

INTERPRETED BY

Kathleen Sennello
DVM, MS, Diplomate
ACVIM (Small Animal
Internal Medicine)

IMAGING PERFORMED BY

Dr. Mengine

HOSPITAL NAME

Stoney Creek VH

REFERRING VET

Dr. Mengine

INVOICE

91578

DATE

8/31/21

SECONDARY FINDINGS:

- Mildly mottled spleen. The diffuse splenic changes are non-specific and could be consistent with lymphoid hyperplasia, extramedullary hematopoiesis, infiltrative neoplasia, inflammation, other. Cytology or histopathology would be necessary to get a definitive diagnosis.
- Decreased corticomedullary distinction in both kidneys with non-obstructive nephroliths. Mild loss of corticomedullary distinction in both kidneys could be consistent with chronic degenerative disease or interstitial nephrosis. The hyperechoic mineralized foci observed at the corticomedullary junction of the left/right kidney are consistent with small, non-obstructive nephroliths.

INTERPRETATION OF THE FINDINGS & FURTHER RECOMMENDATIONS

The liver appears diffusely nodular. This could be consistent with benign or cancerous change. Due to the lack of chronic symptoms I suspect that this is less likely a neoplastic change. I recommend a liver function test and FNA of the liver (there is a nodule on the left side of the liver at the periphery, which should be reachable). If liver function is abnormal a biopsy may be necessary to obtain more information.

Additionally, there is a nodule on the left adrenal gland. There is no obvious evidence of clear vascular invasion, but this cannot be 100% ruled out. These nodules can be benign or malignant and can secrete hormones or be non-active. Options moving forward include:

- If signs of Cushing's are present, consider adrenal function testing. I prefer an ACTH stimulation test combined with an adrenal panel to the University of Tennessee's endocrine lab to look for atypical adrenal hormones as well as cortisol. (other testing can suffice)
- If adrenal dependent Cushing's is suspected and supported by adrenal function testing consider medical therapy with Lysodren or Trilostane or consider surgical removal (recommend referral to a board certified veterinary surgeon and possible pre op CT)
- Recommend blood pressure evaluation-if hypertensive consider testing catecholamine levels for a possible pheochromocytoma
- If no symptoms of Cushing's are present, consider either referral for surgery or continued monitoring with ultrasound (in 3-4 months).
- Many of these nodules can be benign and incidental in nature, unfortunately that is difficult to determine with a single ultrasound.

If an abdominal CT was performed you can get more information about the liver and left adrenal gland and consider surgical planning for biopsies and adrenalectomy.

I am hoping that the diarrhea reported is transient and associated with the recent NSAID. I recommend a probiotic bland diet and possibly GI protectants. If diarrhea persists you can consider obtaining small intestinal biopsies.



PATIENT

Ziggy Zimmerman

SPECIES

Canine

BREED

Bichon Frise

SEX

Neutered male

AGE

11 years

WEIGHT

13 lbs

INTERPRETED BY

Kathleen Sennello
DVM, MS, Diplomate
ACVIM (Small Animal
Internal Medicine)

IMAGING PERFORMED BY

Dr. Mengine

HOSPITAL NAME

Stoney Creek VH

REFERRING VET

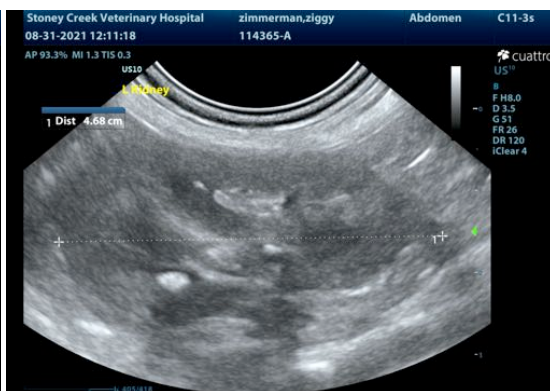
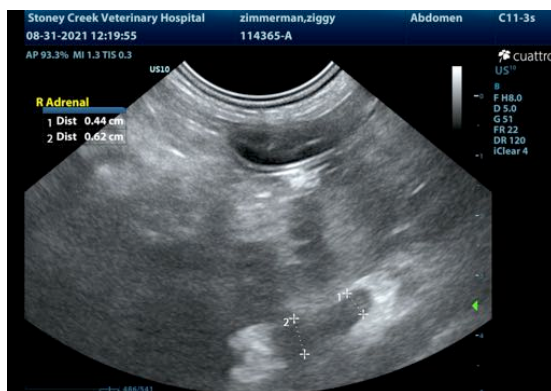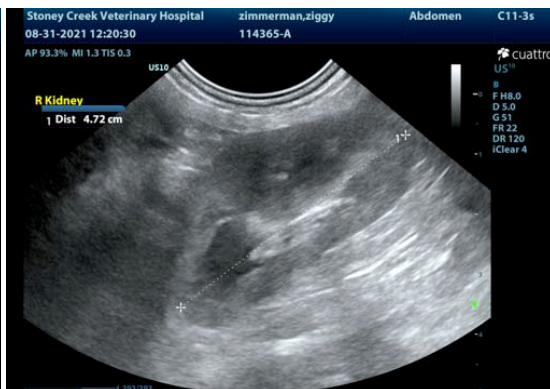
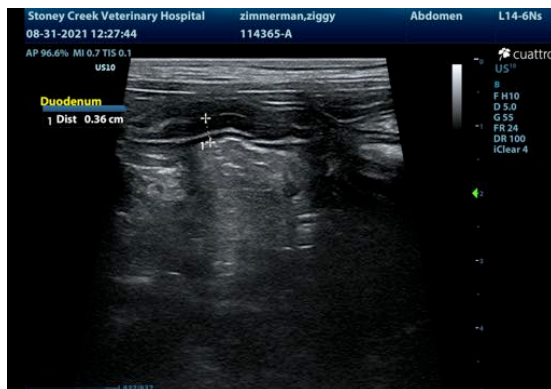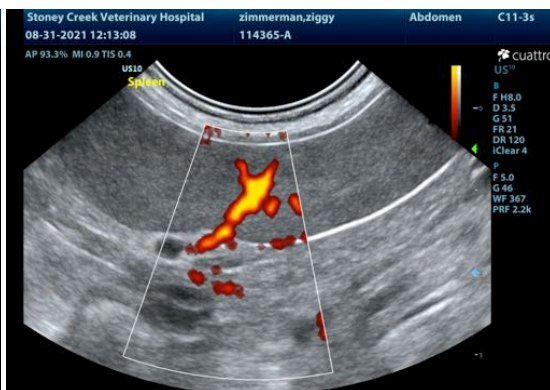
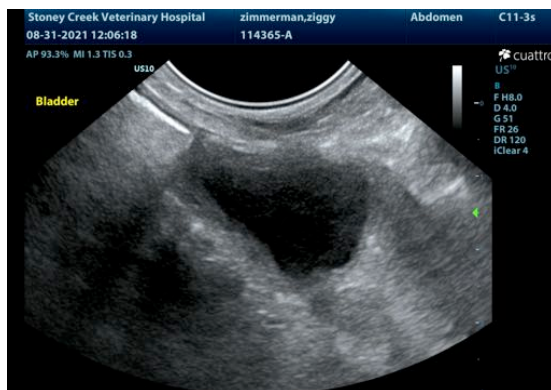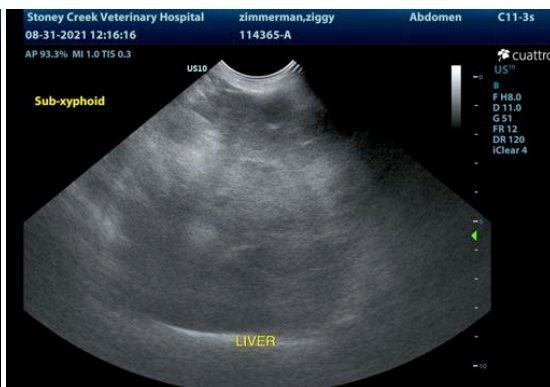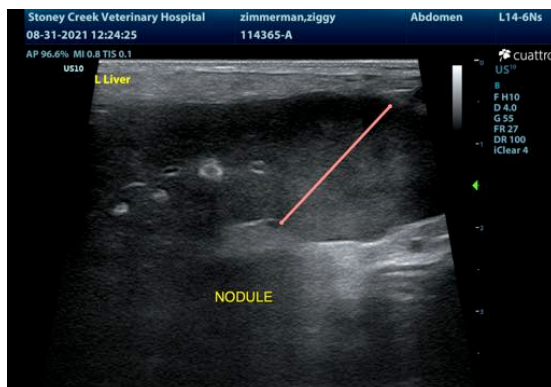
Dr. Mengine

INVOICE

91578

DATE

8/31/21





PATIENT

Ziggy Zimmerman

SPECIES

Canine

BREED

Bichon Frise

SEX

Neutered male

AGE

11 years

WEIGHT

13 lbs

INTERPRETED BY

Kathleen Sennello
DVM, MS, Diplomate
ACVIM (Small Animal
Internal Medicine)

**IMAGING
PERFORMED BY**

Dr. Mengine

HOSPITAL NAME

Stoney Creek VH

REFERRING VET

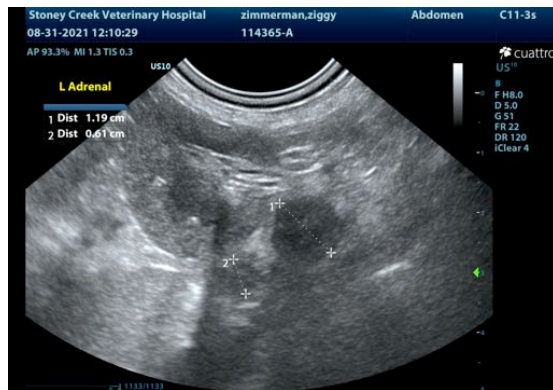Dr. Mengine

INVOICE

91578

DATE

8/31/21



The information and recommendations provided are based on the images presented by the referring veterinarian. No evaluation can be communicated regarding pathology that was not visible in the image/video clips provided.

Thank you for this referral. If the clinical or image interpretation does not parallel your findings or if I can be of any further assistance please contact me.

Kathleen Sennello DVM,MS, Diplomate ACVIM (Small animal Internal Medicine)
kathleen.sennello@sonopath.com