



**PATIENT**

Violet Schwarz

**SPECIES**

Canine

**BREED**

Maltese

**SEX**

Spayed Female

**AGE**

8 years

**WEIGHT**

8.8 lbs

**PRESENTING CLINICAL SIGNS**

History: P is rapidly losing weight per o. Bowel movements are more frequent now. No change in consistency. Hair thinning and collarettes diffusely, thin skin and chronic ear infection. O reports also pu/pd. On Pe Has a heart murmur, and enlarged prescapular lnn. Gr 4 tartar.

Abnormal PE/Chem/CBC/UA Results: fecal- nps, Cbc-monocytosis 966h, Alt- 123 H, Alp- 157 H Cholesterol Low 87 T4-0.9 u/a pending chest xrays- no obvious mets noted, diffuse bronchial pattern

**ULTRASONOGRAPHIC EXAMINATION OF THE ABDOMEN**

**Urinary System**

The urinary bladder is moderately distended with anechoic urine. The Bladder wall, trigone, ureteral papillae and visible urethra (to a depth of 2cm) appear normal with no evidence of wall thickening, mucosal irregularities, masses or cystic calculi.

The left kidney has a normal shape and size (3.7 cm). Overall echogenicity is slightly hyperechoic with poor corticomedullary distinction and a typical 1:3 cortex:medulla ratio. There is no evidence of perinephric inflammation or effusion. There is no evidence of pyelectasia, nephroliths, infarcts or hydroureter. Renal vasculature is normal.

The right kidney has a normal shape and size (3.51 cm). Overall echogenicity is slightly hyperechoic with poor corticomedullary distinction and a typical 1:3 cortex:medulla ratio. There is no evidence of perinephric inflammation or effusion. There is no evidence of pyelectasia, nephroliths, infarcts or hydroureter. Renal vasculature is normal.

**Adrenal Glands**

The left adrenal gland is normal in size measuring 0.43 cm at the caudal pole It is observed in its normal position cranial to the left renal artery. It is normal in appearance (uniformly hypoechoic) and shape with no evidence of a mass effect.

The right adrenal gland is normal in size measuring 0.38 cm at the caudal pole It is observed in its normal position between the cranial aspect of the right kidney and the caudal vena cava. It is normal in appearance (uniformly hypoechoic) and shape with no evidence of a mass effect.

**Spleen**

The spleen is subjectively normal in size, echotexture is homogenous, and the splenic capsule is smooth with no irregularities. The blood flow through the hilus and splenic parenchyma appears normal. No focal parenchymal abnormalities are visualized.

**Liver**

The liver is normal to small in size, and echogenicity with smooth peripheral margins. The parenchyma is homogenous echotexture. The visible portions of the vasculature and biliary tract appear normal. No focal nodules or cystic lesions are observed. The gallbladder lumen is moderately distended. The wall of the gall bladder is not thickened and has a smooth mucosal surface. Luminal contents are primarily anechoic. The cystic and common bile ducts are normal/not visible.

**INTERPRETED BY**

Kathleen Sennello  
DVM, MS, Diplomate  
ACVIM (Small Animal  
Internal Medicine)

**IMAGING PERFORMED BY**

Dr. Cassel Conways

**HOSPITAL NAME**

Central Broward AH

**REFERRING VET**

Dr. Oms

**INVOICE**

91577

**DATE**

8/31/21



**PATIENT**

**Gastrointestinal**

Violet Schwarz

The stomach contains minimal luminal contents. It measures at a normal thickness of <0.7cm with some variability due to the presence of rugal folds. The distinction of the gastric wall layers is adequate and there is no impression of reduced peristaltic activity. No masses or focal lesions were observed.

**SPECIES**

Canine

The visualized areas of duodenum, jejunum and ileum have a uniform diameter with minimal fluid distension. Wall appears subjectively, mildly increased. Bowel loops follow a typical curvilinear path with distinct wall layering. The duodenum measured 0.35 cm and the jejunum measured 0.31 cm, 0.27 cm and 0.34 cm. Visualized peristalsis appears appropriate. There were no focal lesions consistent with obstruction or a mass effect observed. Mild mucosal speckling was observed.

**BREED**

Maltese

The ileocecal junction was visualized and exhibited normal intact wall layering and is subjectively of normal thickness. Sections of colon are visualized with liquid fecal material and gas shadowing distally. There is no observed focal or generalized colon wall thickening or loss of layering.

**SEX**

Spayed Female

**Pancreas**

**AGE**

8 years

The pancreas is prominent and hypoechoic as compared to the surrounding isoechoic mesentery. There is no evidence of nodules or cystic lesions. There is no evidence of regional mesenteric inflammation or fluid.

**WEIGHT**

8.8 lbs

**Free Abdomen**

Evaluation of the peritoneal cavity did not reveal any evidence of effusion, or subjective lymphadenomegaly. The Medial iliac nodes appear normal and there was no evidence of a caudal aortic thrombus at the bifurcation. The omentum is of normal uniform echogenicity.

**INTERPRETED BY**

Kathleen Sennello  
DVM, MS, Diplomate  
ACVIM (Small Animal  
Internal Medicine)

**ULTRASONOGRAPHIC FINDINGS**

**PRIMARY FINDINGS:**

- Mild mucosal speckling of the duodenum. Bright mucosal speckling has been proposed to represent dilated lacteals or focal accumulation of mucus, cellular debris etc.. in the mucosal crypts of the small intestine. This is very mild, but can sometimes be seen with dilated lymphatic/lymphangectasia.

**SECONDARY FINDINGS:**

- Decreased corticomedullary distinction in both kidneys. Mild loss of corticomedullary distinction in both kidneys could be consistent with chronic degenerative disease or interstitial nephrosis.
- Prominent, hypoechoic pancreas. The pancreatic changes are most consistent with age-related parenchymal remodeling, potentially secondary to a prior inflammatory episode, early fibrosis or chronic pancreatitis.
- Borderline, small liver. The significance of this is unclear.

**IMAGING PERFORMED BY**

Dr. Cassel Conways

**HOSPITAL NAME**

Central Broward AH

**REFERRING VET**

Dr. Oms

**INVOICE**

91577

**DATE**

8/31/21



**PATIENT**

Violet Schwarz

**SPECIES**

Canine

**BREED**

Maltese

**SEX**

Spayed Female

**INTERPRETATION OF THE FINDINGS & FURTHER RECOMMENDATIONS**

The changes observed on today's scan were relatively mild and non-specific. There were no obvious lesions responsible for the weight loss were observed. There is mild mucosal speckling to the duodenum. This can be an incidental finding, but could also be an indicator of small intestinal disease. I recommend a GI panel with a quantitative PLI, B12 and folate to get more information about the pancreas and GI tract. Additionally the liver was subjectively small. An obvious shunt was not visualized, but consider a liver function test. If the bile acids are elevated I would consider a CT scan to better visualize the vasculature.

My primary concern would be that of small intestinal disease causing malabsorption and a decrease in appetite. Consider a low-fat or hydrolyzed protein diet, probiotics and if diarrhea persists consider obtaining small intestinal biopsies (particularly if GI panel indicates underlying small intestinal disease.

I recommend urinalysis, culture and blood pressure evaluation. If azotemia is not present, then the changes are likely consistent with age related renal disease. I recommend FNA of reported enlarged peripheral lymph node.

**AGE**

8 years

**WEIGHT**

8.8 lbs

**INTERPRETED BY**

Kathleen Sennello  
DVM, MS, Diplomate  
ACVIM (Small Animal  
Internal Medicine)

**IMAGING PERFORMED BY**

Dr. Cassel Conways

**HOSPITAL NAME**

Central Broward AH

**REFERRING VET**

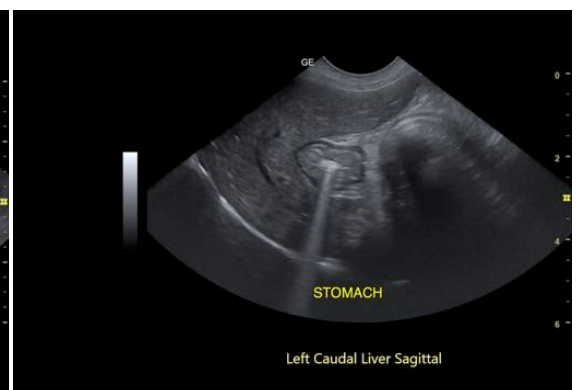
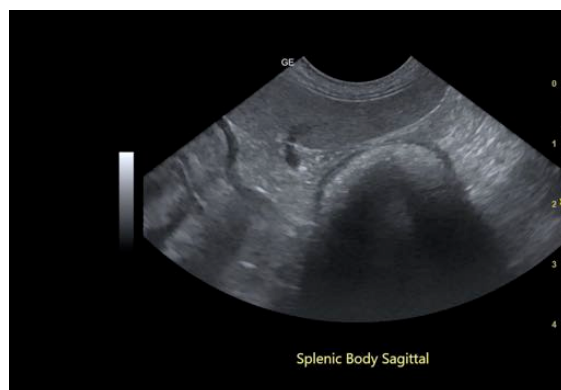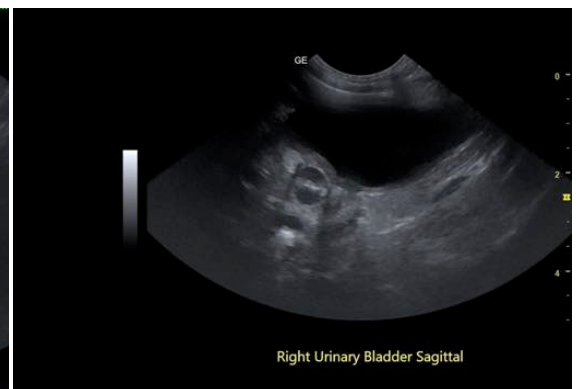
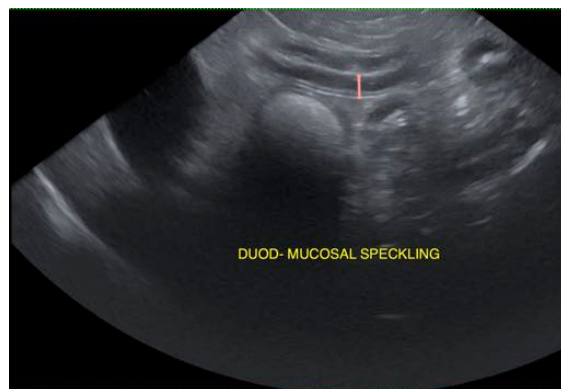
Dr. Oms

**INVOICE**

91577

**DATE**

8/31/21





**PATIENT**

Violet Schwarz

**SPECIES**

Canine

**BREED**

Maltese

**SEX**

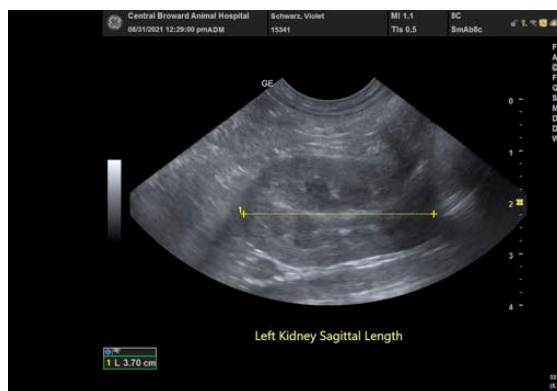
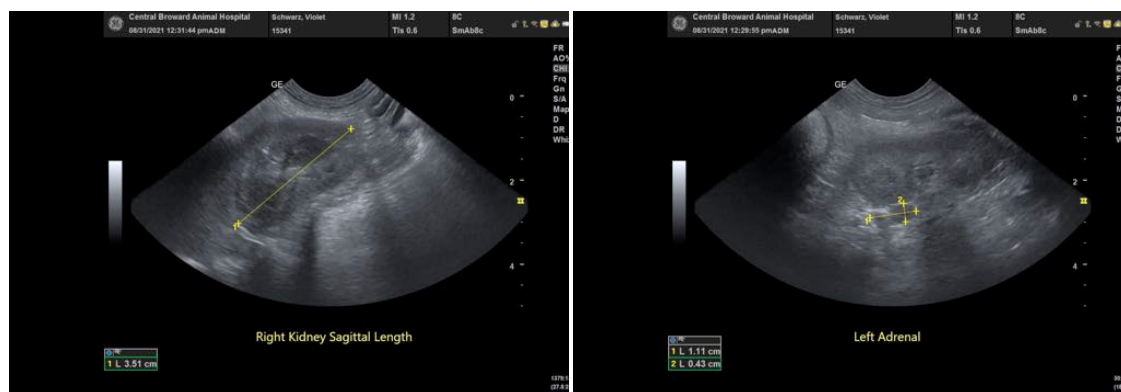
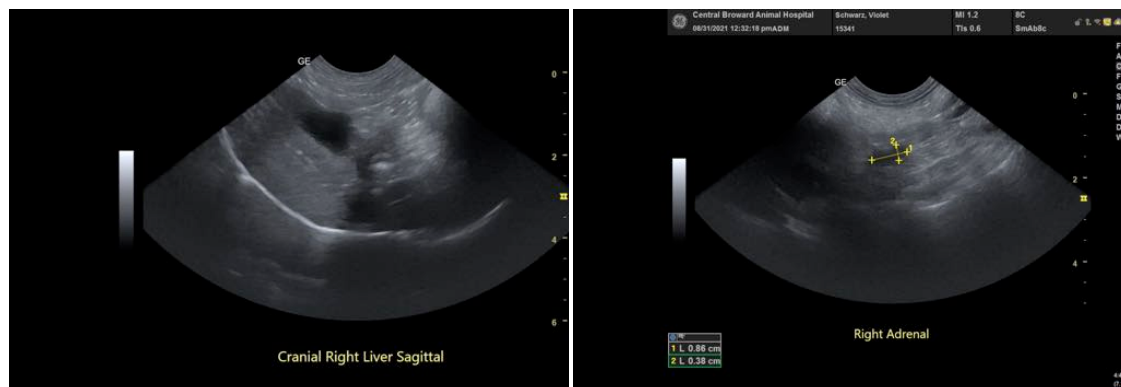
Spayed Female

**AGE**

8 years

**WEIGHT**

8.8 lbs



**INTERPRETED BY**

Kathleen Sennello  
DVM, MS, Diplomate  
ACVIM (Small Animal  
Internal Medicine)

**IMAGING PERFORMED BY**

Dr. Cassel Conways

**HOSPITAL NAME**

Central Broward AH

**REFERRING VET**

Dr. Oms

**INVOICE**

91577

**DATE**

8/31/21

The information and recommendations provided are based on the images presented by the referring veterinarian. No evaluation can be communicated regarding pathology that was not visible in the image/video clips provided.

Thank you for this referral. If the clinical or image interpretation does not parallel your findings or if I can be of any further assistance please contact me.

Kathleen Sennello DVM,MS, Diplomate ACVIM (Small animal Internal Medicine)  
kathleen.sennello@sonopath.com