



**DATE PRESENTING CLINICAL SIGNS**

8/31/21 Vomiting, Diarrhea.  
**PATIENT** History: Date: 08-29-2021 Notes: Owner partner went out of town Wednesday. Patient started having diarrhea Thursday morning. Thursday evening patient started vomiting. Patient is not eating and lethargic.

Nofuratu Ward Current Medications: Amp/Sulb (Unasyn) 1.5gm Injection (Per mL), Pantoprazole (Protonix) 40mg/vial Injection (Per mL), Gabapentin Tablets 50mg, Fenbendazole Suspension 100mg/mL  
Lab Results: Attached

**SPECIES** Date of Previous IntraPet Ultrasound: No previous  
Feline Sedation: not needed  
Stat Report: not requested

**BREED ULTRASONOGRAPHIC EXAMINATION OF THE ABDOMEN**

Sphynx

**SEX**

Neutered Male

**AGE**

9/23/20

**WEIGHT**

7.86 Pounds

**INTERPRETED BY**

Kathleen Sennello DVM,  
MS, Diplomate ACVIM  
(Small Animal Internal  
Medicine)

**HOSPITAL NAME**

Animal Emergency  
Hospital

**REFERRING VET**

Dr. Roper

**INVOICE**

25110

**Urinary System**

The urinary bladder is moderately distended with anechoic urine. The Bladder wall, trigone, ureteral papillae and visible urethra (to a depth of 2cm) appear normal with no evidence of wall thickening, mucosal irregularities, masses or cystic calculi.

The left kidney has a normal shape and size (4.01 cm). Overall echogenicity is normal with adequate corticomedullary distinction and a typical 1:3 cortex:medulla ratio. There is no evidence of perinephric inflammation or effusion. There is no evidence of pyelectasia, nephroliths, infarcts or hydroureter. Renal vasculature is normal.

The right kidney has a normal shape and size (3.9 cm). Overall echogenicity is normal with adequate corticomedullary distinction and a typical 1:3 cortex:medulla ratio. There is no evidence of perinephric inflammation or effusion. There is no evidence of pyelectasia, nephroliths, infarcts or hydroureter. Renal vasculature is normal.

**Adrenal Glands**

The region of left adrenal (Cranial to left renal artery) is unremarkable but the adrenal is not distinctly visualized. No evidence of a mass effect.

The region of the right adrenal (between right cranial kidney and vena cava) is unremarkable, but the adrenal is not distinctly visualized. No evidence of a mass effect.

**Spleen**

The spleen is subjectively normal in size, echotexture is homogenous, and the splenic capsule is smooth with no irregularities. The blood flow through the hilus and splenic parenchyma appears normal. No focal parenchymal abnormalities are visualized.

**Liver**

The liver is subjectively normal in size, and echogenicity with smooth peripheral margins. The parenchyma is homogenous echotexture. The visible portions of the vasculature and biliary tract appear normal. No focal nodules or cystic lesions are observed.

The gallbladder lumen is moderately distended. The wall of the gall bladder is not thickened and has a smooth mucosal surface. Luminal contents are primarily anechoic. The cystic and common bile ducts are normal/not visible.

### ***Gastrointestinal***

The stomach contains minimal luminal contents. It measures at a normal thickness of <0.7cm with some variability due to the presence of rugal folds. The distinction of the gastric wall layers is adequate and there is no impression of reduced peristaltic activity. No masses or focal lesions were observed.

The visualized areas of duodenum, jejunum and ileum have a relatively uniform diameter with minimal fluid distension. Wall thickness is normal. Bowel loops follow a curvilinear path with distinct wall layering maintaining the typical 1:3 muscularis:mucosa layer ratio. Jejunum wall measures 0.2 cm. Visualized peristalsis appears appropriate. There were no focal lesions consistent with obstruction or a mass effect observed.

The ileocecal junction was visualized and exhibited normal intact wall layering and is subjectively of normal thickness. Sections of colon are visualized with formed fecal material and gas shadowing distally. There is no observed focal or generalized colon wall thickening or loss of layering.

### ***Pancreas***

The pancreas is large and hypoechoic to surrounding mesentery. There is no evidence of nodules or cystic lesions. There is evidence of regional mesenteric inflammation. Consistent with moderate pancreatitis. The pancreatic duct measures 0.15 cm.

### ***Free Abdomen***

Evaluation of the peritoneal cavity did not reveal any evidence of effusion. There is a mild/moderate lymphadenomegaly present. Mesenteric lymph nodes are prominent and hypoechoic, measuring 0.5, 0.47 cm, particularly in the area of the ileocecal junction. The Medial iliac nodes appear normal and there was no evidence of a caudal aortic thrombus at the bifurcation. The omentum is generally of normal uniform echogenicity.

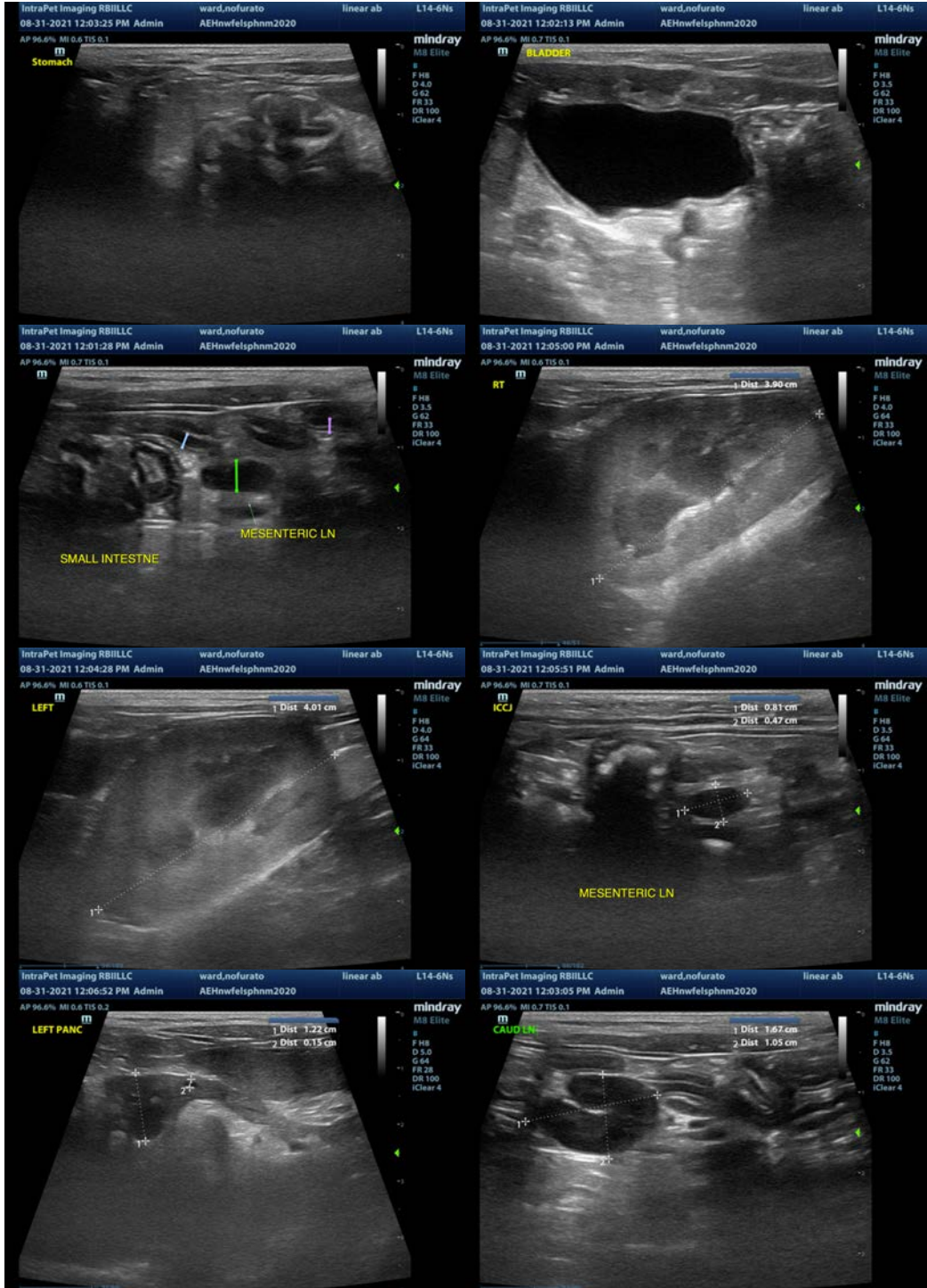
## **ULTRASONOGRAPHIC FINDINGS**

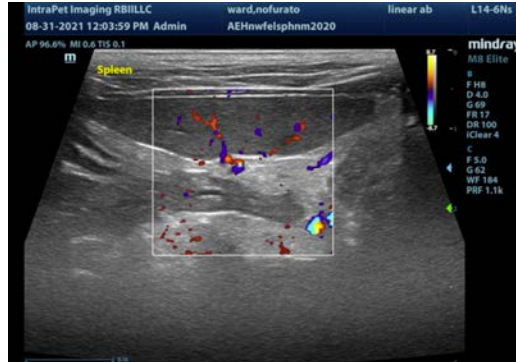- Prominent, hypoechoic pancreas with mildly dilated pancreatic duct – The pancreatic changes are most consistent with mild pancreatitis/pancreatic inflammation. Recommend fPLI testing and continued monitoring for improvement or possible development of a pancreatic abscess. Consider fine needle aspirate if not improving.
- Mild mesenteric lymphadenopathy – The prominent abdominal lymph nodes are most consistent with reactive lymphadenitis or lymphoid hyperplasia. Neoplastic infiltration is considered less likely. Prominent mesenteric lymph nodes can be a normal finding in normal, young animals.

## **INTERPRETATION OF THE FINDINGS & FURTHER RECOMMENDATIONS**

The ultrasonographic changes are relatively mild. The pancreas does appear very prominent and hypoechoic, most consistent with mild pancreatitis. Recommend a quantitative fPLI level with B12 and folate to Texas A&M University (GI panel) to further evaluate for pancreatic inflammation and underlying gastrointestinal disease. There are no overt changes observed in the GI tract, but the mesenteric lymph nodes are prominent. This can be a common finding in younger patients, but is likely reactive to small intestinal inflammation.

Consider treatment for acute gastroenteritis and pancreatitis. Correlate with abdominal radiographs, as ultrasound can be insensitive to picking up some types of foreign material in the GI tract. If the patient is not improving over time, consider further evaluation for causes of vomiting and diarrhea (dietary intolerance, bacterial overgrowth, parasites, etc.). Recommend starting a probiotic.





**The information and recommendations provided are based on the images presented by the referring veterinarian. No evaluation can be communicated regarding pathology that was not visible in the image/video clips provided.**

Thank you for this referral. If the clinical or image interpretation does not parallel your findings or if I can be of any further assistance please contact me.

Kathleen Sennello DVM,MS, Diplomate ACVIM (Small animal Internal Medicine)  
kathleen.sennello@sonopath.com