

**DATE**

8/31/21

**PRESENTING CLINICAL SIGNS**

Referral for Continued Care, Hemoabdomen, Vomiting.

History: Date: 08-28-2021 Notes: Thursday- looked bloated- had vomited/ having diarrhea; lethargic looked better on Friday- but still having diarrhea saw RDVM today- RDVM felt the abdomen was distended and took radiograph- concern about mass effect referred here had testicular cancer removed in 4/2021- per owner- bloodwork had been normal back then is eating and drinking no further vomiting still having diarrhea.

**PATIENT**

Cha Cha Ferguson

Lab Results: See above

Date of Previous IntraPet Ultrasound: No previous

Sedation: not needed

Stat Report: not requested

**SPECIES**

Canine

**BREED**

Yorkshire Terrier Mix

**ULTRASONOGRAPHIC EXAMINATION OF THE ABDOMEN****Urinary System**

The urinary bladder is moderately distended with anechoic urine. The Bladder wall, trigone, ureteral papillae and visible urethra (to a depth of 2cm) appear normal with no evidence of wall thickening, mucosal irregularities, masses or cystic calculi.

**SEX**

Neutered male

The visualized areas of prostate and surrounding tissue appear normal. Unfortunately, the prostate is not fully visualized likely due to its intrapelvic location. Correlate with rectal exam findings.

**AGE**

2010

The left kidney has a normal shape and size (3.79 cm). The left kidney is somewhat irregular with a cortical cyst that measured 0.4 cm. Overall echogenicity is slightly hyperechoic with poor corticomedullary distinction and a typical 1:3 cortex:medulla ratio. There is no evidence of perinephric inflammation or effusion. There is no evidence of pyelectasia, nephroliths, infarcts or hydroureter. Renal vasculature is normal.

**WEIGHT**

5.1 lbs

The right kidney has a normal shape and size (3.18 cm). Overall echogenicity is slightly hyperechoic with poor corticomedullary distinction and a typical 1:3 cortex:medulla ratio. There is no evidence of perinephric inflammation or effusion. There is no evidence of pyelectasia, nephroliths, infarcts or hydroureter. Renal vasculature is normal.

**INTERPRETED BY**

Kathleen Sennello  
 DVM, MS, Diplomate  
 ACVIM (Small Animal  
 Internal Medicine)

**Adrenal Glands**

The left adrenal gland is normal in size measuring 0.54 cm at the caudal pole It is observed in its normal position cranial to the left renal artery. It is normal in appearance (uniformly hypoechoic) and shape with no evidence of a mass effect.

**HOSPITAL NAME**Animal Emergency  
Hospital

The right adrenal gland is normal in size measuring 0.57 cm at the caudal pole It is observed in its normal position between the cranial aspect of the right kidney and the caudal vena cava. It is normal in appearance (uniformly hypoechoic) and shape with no evidence of a mass effect.

**REFERRING VET**

Dr. Willer

**Spleen**

The spleen is subjectively normal in size, echotexture is homogenous, and the splenic capsule is smooth with no irregularities. The blood flow through the hilus and splenic parenchyma appears normal. No focal parenchymal abnormalities are visualized.

**INVOICE**

91584

**Liver**

The liver is large in size with somewhat, hypoechoic echogenicity with very irregular, rounded, nodular margins. The parenchyma is severely heterogenous with a mottled, lacy echotexture. The visible portions of the vasculature and biliary tract appear normal. No focal nodules or cystic lesions are observed. The

gallbladder lumen is moderately distended. The wall of the gallbladder is prominent at 0.26 cm, but appears to have a normal, smooth mucosal surface. The cystic and common bile ducts are normal/not visible.

### ***Gastrointestinal***

The stomach contains minimal luminal contents. It measures at a normal thickness of <0.7cm with some variability due to the presence of rugal folds. The distinction of the gastric wall layers is adequate and there is no impression of reduced peristaltic activity. No masses or focal lesions were observed.

The visualized areas of duodenum, jejunum and ileum have a relatively uniform diameter with minimal fluid distension. Wall thickness is normal. Bowel loops follow a curvilinear path with distinct wall layering maintaining the typical 1:3 muscularis:mucosa layer ratio. The duodenum measured as normal (between 0.3-0.5cm in wall thickness) and the jejunum measured as normal (between 0.2-0.47cm.) Visualized peristalsis appears appropriate. There were no focal lesions consistent with obstruction or a mass effect observed.

The ileocecal junction was visualized and exhibited normal intact wall layering and is subjectively of normal thickness. Sections of colon are visualized with formed fecal material and gas shadowing distally. There is no observed focal or generalized colon wall thickening or loss of layering.

### ***Pancreas***

The pancreas is normal and isoechoic to surrounding mesentery. There is no evidence of nodules or cystic lesions. There is no evidence of regional mesenteric inflammation or fluid.

### ***Free Abdomen***

Evaluation of the peritoneal cavity revealed a scant amount of anechoic free fluid. There is a moderate/severe lymphadenopathy present (caudal abdominal lymph nodes are prominent and enlarged). A sublumbar lymph node measured 1.64 x 4.19 cm. A caudal mesenteric lymph node measured 2.46 cm. The omentum is of normal uniform echogenicity.

## **ULTRASONOGRAPHIC FINDINGS**

### **PRIMARY FINDINGS:**

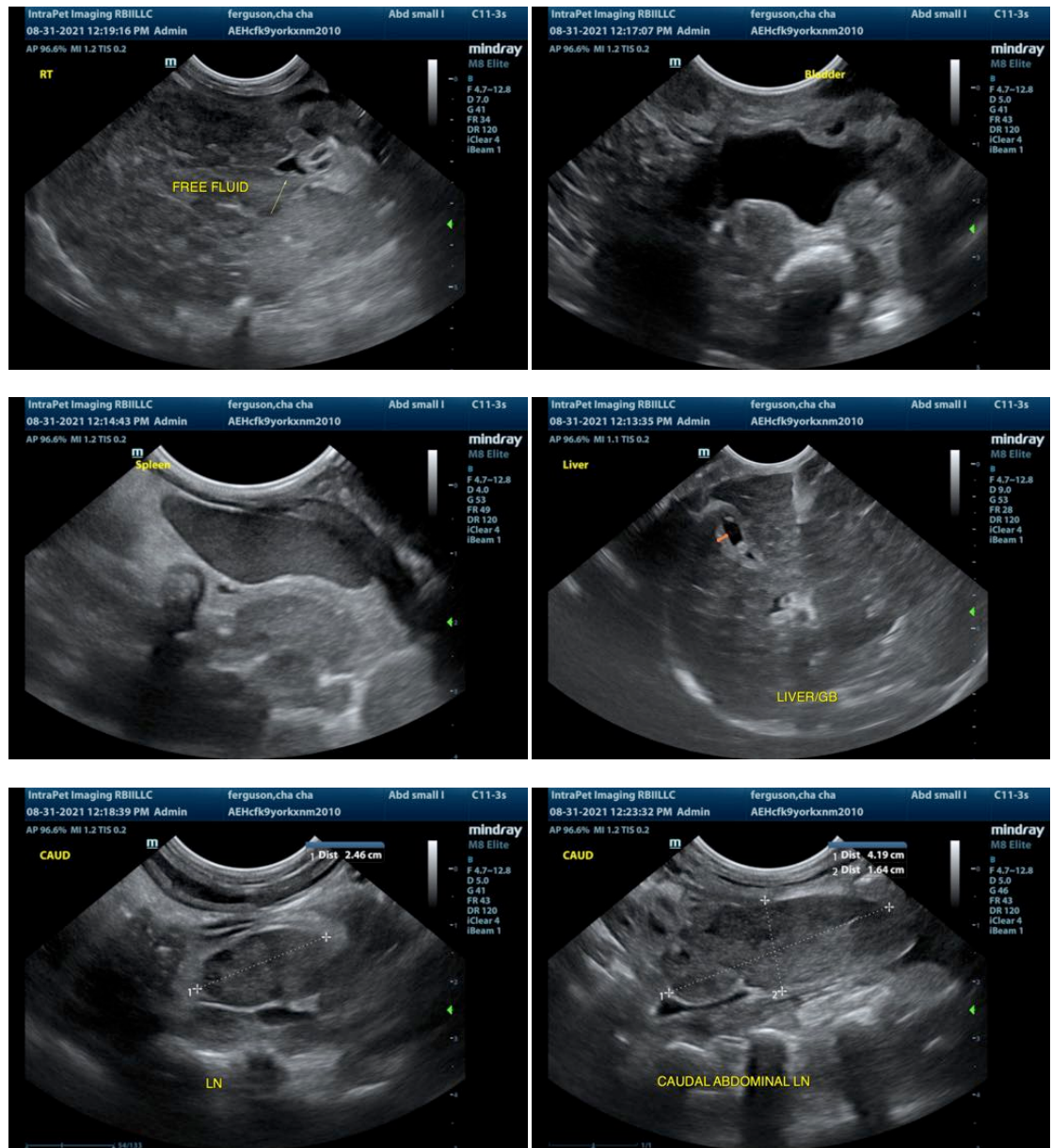
- Large, hypoechoic, nodular liver. The diffuse hepatic changes are non-specific and could be consistent with vacuolar hepatopathy, nodular hyperplasia, inflammatory/immune-mediated disease, fibrosis, extramedullary hematopoiesis, toxic hepatopathy (e.g., copper), infiltrative neoplasia (less likely) or other hepatopathy.
- Large caudal abdominal lymph nodes. The prominent abdominal lymph nodes are most consistent with reactive lymphadenitis or lymphoid hyperplasia. Neoplastic infiltration is considered less likely.

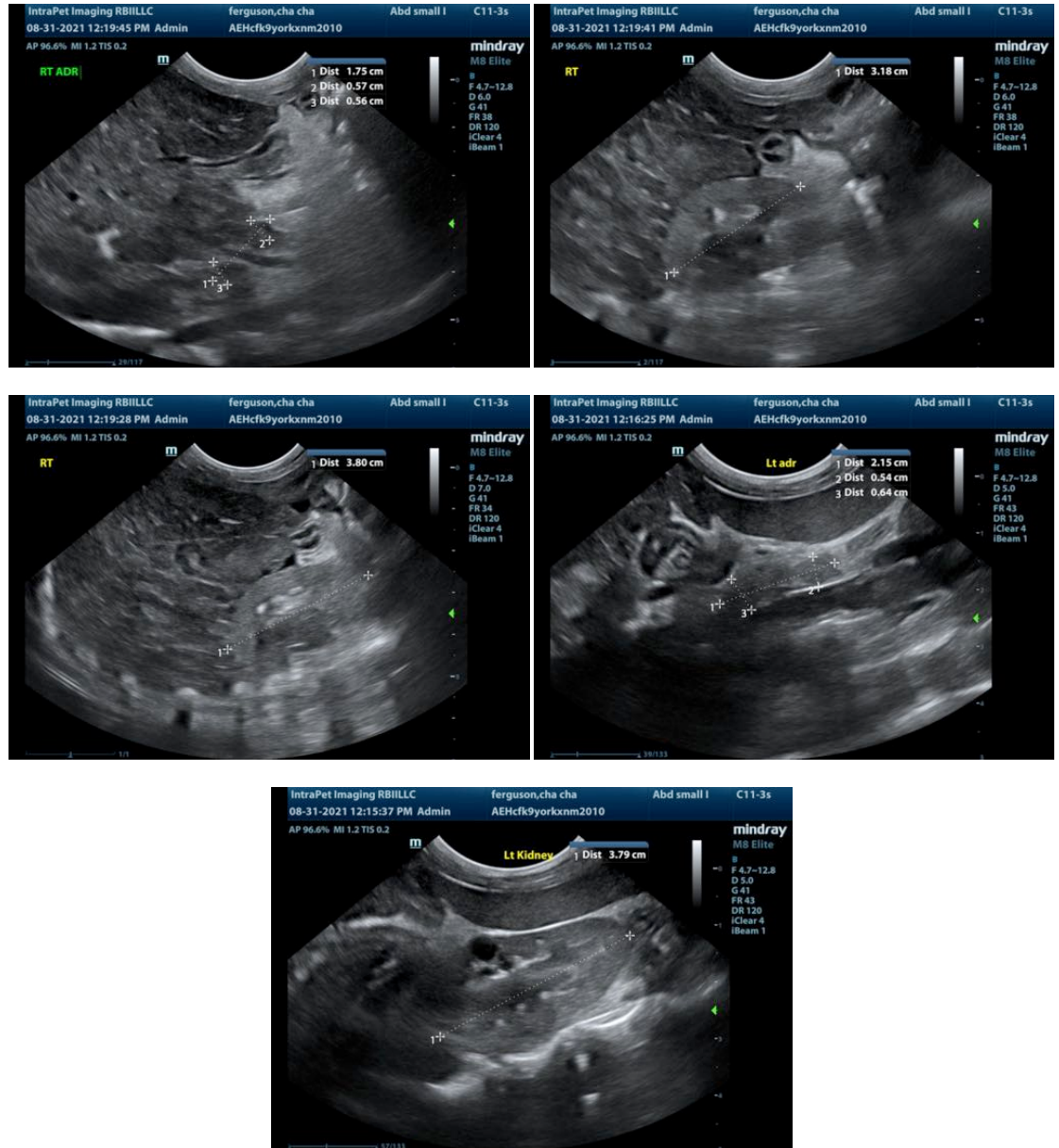
### **SECONDARY FINDINGS:**

- Decreased corticomedullary distinction in both kidneys. Mild loss of corticomedullary distinction in both kidneys could be consistent with chronic degenerative disease or interstitial nephrosis.
- Small volume of free abdominal fluid. This is possibly inflammatory/reactive. I recommend to continue to monitor and sampling if volume increases.

### INTERPRETATION OF THE FINDINGS & FURTHER RECOMMENDATIONS

The liver is very large and irregular. I recommend FNA and full blood work (CBC, chemistry panel, urinalysis +/- liver function test). Additionally there are large, prominent lymph nodes in the caudal abdomen. I am concerned that this could be related to the previous history of testicular cancer. I recommend FNA of caudal abdominal lymph node with care taken to avoid close vasculature. I recommend three view thoracic radiographs.





The information and recommendations provided are based on the images presented by the referring veterinarian. No evaluation can be communicated regarding pathology that was not visible in the image/video clips provided.

Thank you for this referral. If the clinical or image interpretation does not parallel your findings or if I can be of any further assistance please contact me.

Kathleen Sennello DVM,MS, Diplomate ACVIM (Small animal Internal Medicine)  
 kathleen.sennello@sonopath.com