



PATIENT

Harvey Binning

SPECIES

Canine

BREED

Mixed

SEX

Neutered Male

AGE

7.5 Years

WEIGHT

67 Pounds

INTERPRETED BY

Kathleen Sennello DVM,
MS, Diplomate ACVIM
(Small Animal Internal
Medicine)

IMAGING PERFORMED BY

Judy Schroeder

HOSPITAL NAME

Animal Health
Associates

REFERRING VET

Dr. Ashley N. Nadden

INVOICE

40863

DATE

8/30/22

PRESENTING CLINICAL SIGNS

Patient has a history of low T4 levels, that do not seem very responsive to thyroid supplement, elevated liver enzymes, and intermittent bouts of vomiting. Patient also has hx of pancreatitis.
Abnormal PE/Chem/CBC/UA Results: ALP 512 U/I ALT 148 U/I Amylase 1572 U/I T4 0.8 ug/dl (on 0.8 mg L-thyroxine bid) Electrolytes normal.

ULTRASONOGRAPHIC EXAMINATION OF THE ABDOMEN

Urinary System

The urinary bladder is moderately distended with anechoic urine. The Bladder wall, trigone, ureteral papillae and visible urethra (to a depth of 2cm) appear normal with no evidence of wall thickening, mucosal irregularities, masses or cystic calculi.

The prostate is normal in size (0.70 cm) and shape for this neutered male dog. The parenchyma is homogenous and the external margins are smooth. The prostatic urethra appears normal with no evidence of irregularity, invasion, mass effect or calculi.

The left kidney has a normal shape and size (6.84 cm). Overall echogenicity is normal with adequate corticomedullary distinction and a typical 1:3 cortex:medulla ratio. There is no evidence of focal perinephric inflammation or effusion. There is no evidence of pyelectasia, nephroliths, infarcts or hydroureter. Renal vasculature is normal.

The right kidney has a normal shape and size (7.16 cm). Overall echogenicity is normal with adequate corticomedullary distinction and a typical 1:3 cortex:medulla ratio. There is no evidence of focal perinephric inflammation or effusion. There is no evidence of pyelectasia, nephroliths, infarcts or hydroureter. Renal vasculature is normal.

Adrenal Glands

The left adrenal gland is normal in size measuring 0.54 cm at the caudal pole. It is observed in its normal position cranial to the left renal artery. It is normal in appearance (uniformly hypoechoic) and shape with no evidence of a mass effect.

The right adrenal gland is normal in size measuring 0.55 cm at the caudal pole. It is observed in its normal position between the cranial aspect of the right kidney and the caudal vena cava. It is normal in appearance (uniformly hypoechoic) and shape with no evidence of a mass effect.

Spleen

The spleen is subjectively normal in size, echotexture is homogenous, and the splenic capsule is smooth with no irregularities. The blood flow through the hilus and splenic parenchyma appears normal. No focal parenchymal abnormalities are visualized.

Liver

The liver is subjectively normal in size, and echogenicity with smooth peripheral margins. The parenchyma is heterogenous in echotexture with subtle, indistinct focal mottling. The visible portions of the vasculature and biliary tract appear normal. No focal nodules or cystic lesions are observed.

The gallbladder lumen is moderately distended. The wall of the gall bladder is not thickened and has a smooth mucosal surface. Luminal contents are mild and primarily anechoic. The cystic and common bile ducts are normal/not visible.



PATIENT

Harvey Binning

Gastrointestinal

The stomach contains moderate fluid. It measures at a normal thickness of <0.7cm with some variability due to the presence of rugal folds. The distinction of the gastric wall layers is adequate and there is no impression of reduced peristaltic activity. No masses or focal lesions were observed.

SPECIES

Canine

The visualized areas of duodenum, jejunum and ileum have a relatively uniform diameter with minimal fluid distension. Wall thickness is normal. Bowel loops follow a curvilinear path with distinct wall layering maintaining the typical 1:3 muscularis:mucosa layer ratio. Duodenum wall measured 0.53 cm. Jejunum wall measured 0.33 cm. Visualized peristalsis appears appropriate. There were no focal lesions consistent with obstruction or a mass effect observed.

BREED

Mixed

The ileocecal junction was visualized and exhibited normal intact wall layering and is subjectively of normal thickness. Sections of colon are visualized with formed fecal material and gas shadowing distally. There is no observed focal or generalized colon wall thickening or loss of layering.

SEX

Neutered Male

Pancreas

The pancreas is normal and isoechoic to surrounding mesentery. There is no evidence of nodules or cystic lesions. There is no evidence of regional mesenteric inflammation or fluid.

AGE

7.5 Years

Free Abdomen

Evaluation of the peritoneal cavity did not reveal any evidence of effusion, or subjective lymphadenomegaly. The Medial iliac nodes appear normal and there was no evidence of a caudal aortic thrombus at the bifurcation. The omentum is of normal uniform echogenicity.

WEIGHT

67 Pounds

ULTRASONOGRAPHIC FINDINGS

- Heterogeneous liver – The diffuse hepatic changes are non-specific and could be consistent with vacuolar hepatopathy, nodular hyperplasia, inflammatory/immune-mediated disease, fibrosis, extramedullary hematopoiesis, toxic hepatopathy (e.g., copper), infiltrative neoplasia (less likely) or other hepatopathy.

INTERPRETED BY

Kathleen Sennello DVM,
MS, Diplomate ACVIM
(Small Animal Internal
Medicine)

INTERPRETATION OF THE FINDINGS & FURTHER RECOMMENDATIONS

IMAGING PERFORMED BY

Judy Schroeder

No focal lesions are visualized associated with the liver. Enzyme elevations are mild, but consider a liver function test +/- a fine needle aspirate to further evaluate. If you feel exposure to Leptospirosis is a risk, you could consider testing for this as well.

HOSPITAL NAME

Animal Health
Associates

No lesions were visualized associated with the gastrointestinal tract, but you can still have GI disease without significant ultrasonographic lesions such as food allergy/dietary intolerance, IBD, GI parasites, etc. No significant pancreatic inflammation was noted at this time, but you could consider sending out a GI panel to Texas A&M for qualitative PLI, TLI, cobalamin and folate to further evaluate for underlying pancreatic or small intestinal disease.

REFERRING VET

Dr. Ashley N. Nadden

Additionally, consider underlying metabolic issues. Consider screening for Addison's disease and recommend obtaining 3-view thoracic radiographs.

INVOICE

40863

DATE

8/30/22



PATIENT

Harvey Binning

SPECIES

Canine

BREED

Mixed

SEX

Neutered Male

AGE

7.5 Years

WEIGHT

67 Pounds

INTERPRETED BY

Kathleen Sennello DVM,
MS, Diplomate ACVIM
(Small Animal Internal
Medicine)

**IMAGING
PERFORMED BY**

Judy Schroeder

HOSPITAL NAME

Animal Health
Associates

REFERRING VET

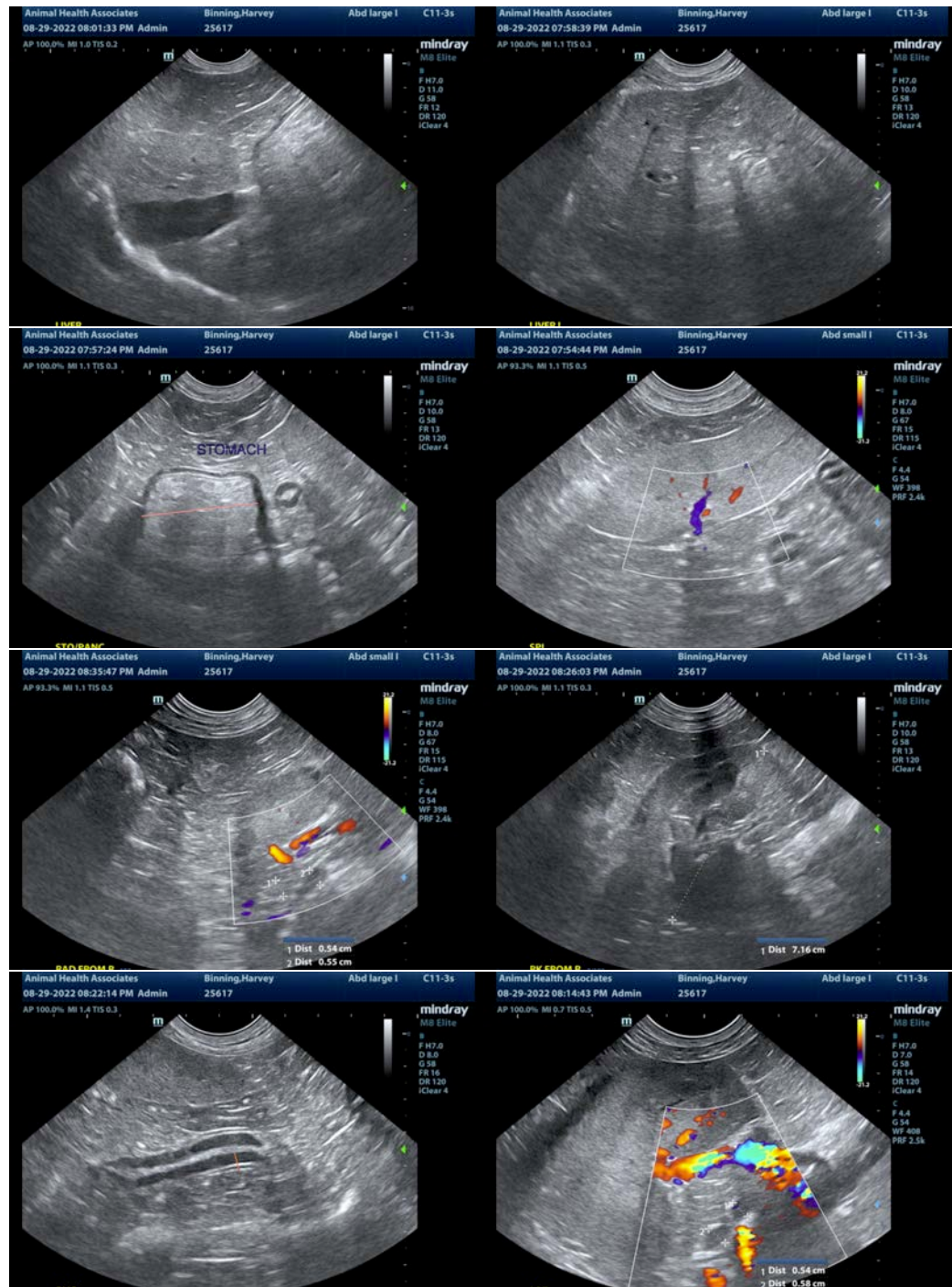
Dr. Ashley N. Nadden

INVOICE

40863

DATE

8/30/22





PATIENT

Harvey Binning

SPECIES

Canine

BREED

Mixed

SEX

Neutered Male

AGE

7.5 Years

WEIGHT

67 Pounds

INTERPRETED BY

Kathleen Sennello DVM,
MS, Diplomate ACVIM
(Small Animal Internal
Medicine)

**IMAGING
PERFORMED BY**

Judy Schroeder

HOSPITAL NAME

Animal Health
Associates

REFERRING VET

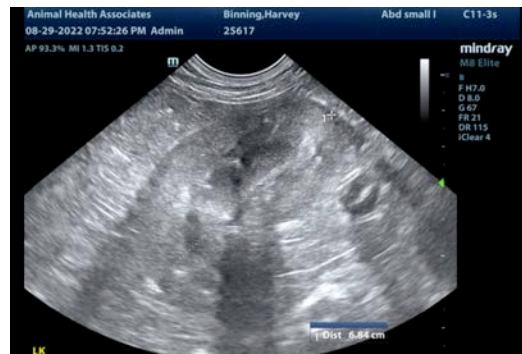Dr. Ashley N. Nadden

INVOICE

40863

DATE

8/30/22



The information and recommendations provided are based on the images presented by the referring veterinarian/sonographer. No evaluation can be communicated regarding pathology that was not visible in the image/video clips provided.

Thank you for this referral. If the clinical or image interpretation does not parallel your findings or if I can be of any further assistance please contact me.

Kathleen Sennello DVM,MS, Diplomate ACVIM (Small animal Internal Medicine)

kathleen.sennello@sonopath.com