



**PATIENT**

Molly Pekelder

**SPECIES**

Canine

**BREED**

Labrador Retriever

**SEX**

Female

**AGE**

19 Weeks

**WEIGHT**

36.5

**INTERPRETED BY**

Kathleen Sennello DVM,  
MS, Diplomate ACVIM  
(Small Animal Internal  
Medicine)

**IMAGING  
PERFORMED BY**

Velasco

**HOSPITAL NAME**

Bethany Family PC

**REFERRING VET**

Dr. Merrill

**INVOICE**

24990

**DATE**

8/27/21

**PRESENTING CLINICAL SIGNS**

Molly has repeat UTIs, even after culture and appropriate antibiotic therapy.  
Abnormal PE/Chem/CBC/UA Results: BUN/Crea are WNL (low) Mild anemia (35) Collection  
CYSTOCENTESIS Color YELLOW Clarity CLEAR Specific Gravity 1.017 pH 6.0 Urine Protein  
NEGATIVE Glucose NEGATIVE Ketones NEGATIVE Blood / Hemoglobin 2+ Bilirubin NEGATIVE  
Urobilinogen NORMAL White Blood Cells 6-10 Red Blood Cells >100 HPF Bacteria a b MARKED RODS  
>40/HPF Epithelial Cells RARE (0-1) Mucus PRESENT Casts NONE SEEN Crystals NONE SEEN tatus:  
FINAL Isolate 1: E. coli - >100,000 CFU per ml Isolate 1 MIC Cefotaxime S Amoxicillin R >=32  
Amoxicillin-Clavulanic Acid S 4 Cephalexin S 8 Cefpodoxime S 0.5 Cefovecin S 1 Ceftazidime S <=0.12  
Ceftiofur S <=1 Imipenem S <=0.25 Amikacin S <=2 Gentamicin S <=1 Ciprofloxacin S <=0.06  
Enrofloxacin S <=0.12 Marbofloxacin S <=0.5 Doxycycline S 1 Nitrofurantoin S <=16 Chloramphenicol S  
8 Trimethoprim/Sulphate S <=20

**ULTRASONOGRAPHIC EXAMINATION OF THE ABDOMEN**

**Urinary System**

The urinary bladder is moderately distended with anechoic urine. The Bladder wall, trigone, ureteral papillae and visible urethra (to a depth of 2cm) appear normal with no evidence of wall thickening, mucosal irregularities, masses or cystic calculi.

The left kidney has a normal shape and size (6.3 cm). Overall echogenicity is normal with adequate corticomedullary distinction and a typical 1:3 cortex:medulla ratio. There is no evidence of perinephric inflammation or effusion. There is no evidence of pyelectasia, nephroliths, infarcts or hydroureter. Renal vasculature is normal.

The right kidney has a normal shape and size (6.4 cm). Overall echogenicity is normal with adequate corticomedullary distinction and a typical 1:3 cortex:medulla ratio. There is no evidence of perinephric inflammation or effusion. There is no evidence of pyelectasia, nephroliths, infarcts or hydroureter. Renal vasculature is normal.

**Adrenal Glands**

The region of left adrenal (Cranial to left renal artery) is unremarkable but the adrenal is not distinctly visualized. No evidence of a mass effect.

The region of the right adrenal (between right cranial kidney and vena cava) is unremarkable, but the adrenal is not distinctly visualized. No evidence of a mass effect.

**Spleen**

The spleen is subjectively normal in size, echotexture is homogenous, and the splenic capsule is smooth with no irregularities. The blood flow through the hilus and splenic parenchyma appears normal. No focal parenchymal abnormalities are visualized.

**Liver**

The liver is subjectively normal in size, and echogenicity with smooth peripheral margins. The parenchyma is homogenous echotexture. The visible portions of the vasculature and biliary tract appear normal. No focal nodules or cystic lesions are observed.

The gallbladder lumen is moderately distended. The wall of the gall bladder is not thickened and has a smooth mucosal surface. Luminal contents are primarily anechoic. The cystic and common bile ducts are normal/not visible.



**PATIENT**

***Gastrointestinal***

Molly Pekelder

The stomach contains minimal luminal contents. It measures at a normal thickness of <0.7cm with some variability due to the presence of rugal folds. The distinction of the gastric wall layers is adequate and there is no impression of reduced peristaltic activity. No masses or focal lesions were observed.

**SPECIES**

Canine

The visualized areas of duodenum, jejunum and ileum have a relatively uniform diameter with minimal fluid distension. Wall thickness is normal. Bowel loops follow a curvilinear path with distinct wall layering maintaining the typical 1:3 muscularis:mucosa layer ratio. The duodenum measured as normal (between 0.3-0.5cm in wall thickness) and the jejunum measured as normal (between 0.2-0.47cm.)

**BREED**

Labrador Retriever

Visualized peristalsis appears appropriate. There were no focal lesions consistent with obstruction or a mass effect observed.

**SEX**

Female

The ileocecal junction was visualized and exhibited normal intact wall layering and is subjectively of normal thickness. Sections of colon are visualized with formed fecal material and gas shadowing distally. There is no observed focal or generalized colon wall thickening or loss of layering.

***Pancreas***

**AGE**

19 Weeks

The pancreas is normal and isoechoic to surrounding mesentery. There is no evidence of nodules or cystic lesions. There is no evidence of regional mesenteric inflammation or fluid.

***Free Abdomen***

**WEIGHT**

36.5

Evaluation of the peritoneal cavity did not reveal any evidence of effusion, or subjective lymphadenomegaly. The Medial iliac nodes appear normal and there was no evidence of a caudal aortic thrombus at the bifurcation. The omentum is of normal uniform echogenicity.

**ULTRASONOGRAPHIC FINDINGS**

- No significant ultrasonographic lesions visualized

**INTERPRETED BY**

Kathleen Sennello DVM,  
MS, Diplomate ACVIM  
(Small Animal Internal  
Medicine)

**INTERPRETATION OF THE FINDINGS & FURTHER RECOMMENDATIONS**

No large obvious abnormalities associated with the urinary tract were visualized. Often dogs with ectopic ureters will have renal pyelectasia. This was not visualized, nor were any stones, etc. Unfortunately, this study cannot exclude the possibility of a small, non-dilated ectopic ureter, as these can often be difficult to visualize in an awake patient without a high-resolution ultrasound probe.

**IMAGING PERFORMED BY**

Velasco

Consider contrast CT scan to better evaluate the ureters and urinary structures for congenital abnormalities. Additionally, evaluate the external genitalia for evidence of vulvar abnormalities, persistent hymen, urine pooling, etc. Recommend aggressive probiotic therapy to counteract frequent use of antibiotics and help to reduce the risk of dysbiosis and resistance. Additionally, cystoscopy can be considered. Ideally this patient would not be spayed until further evaluation is performed, or the spay could be performed by a board certified veterinary surgeon to further evaluate the ureters at that time.

**HOSPITAL NAME**

Bethany Family PC

**REFERRING VET**

Dr. Merrill

**INVOICE**

24990

**DATE**

8/27/21



**PATIENT**

Molly Pekelder

**SPECIES**

Canine

**BREED**

Labrador Retriever

**SEX**

Female

**AGE**

19 Weeks

**WEIGHT**

36.5

**INTERPRETED BY**

Kathleen Sennello DVM,  
MS, Diplomate ACVIM  
(Small Animal Internal  
Medicine)

**IMAGING  
PERFORMED BY**

Velasco

**HOSPITAL NAME**

Bethany Family PC

**REFERRING VET**

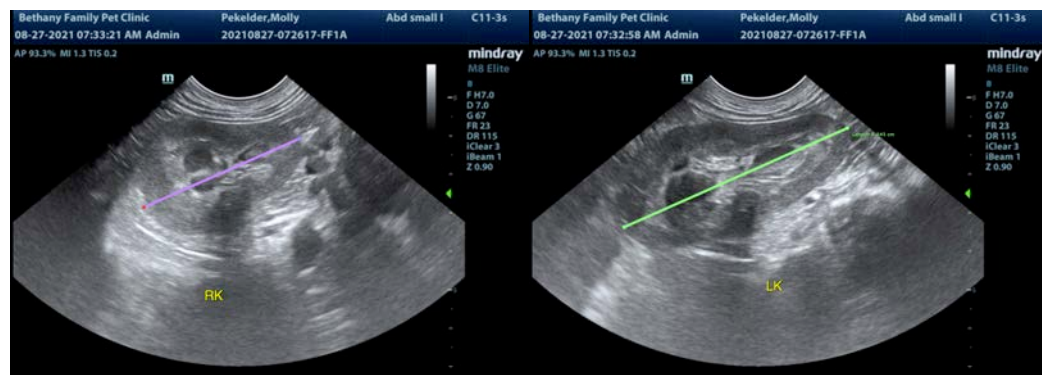
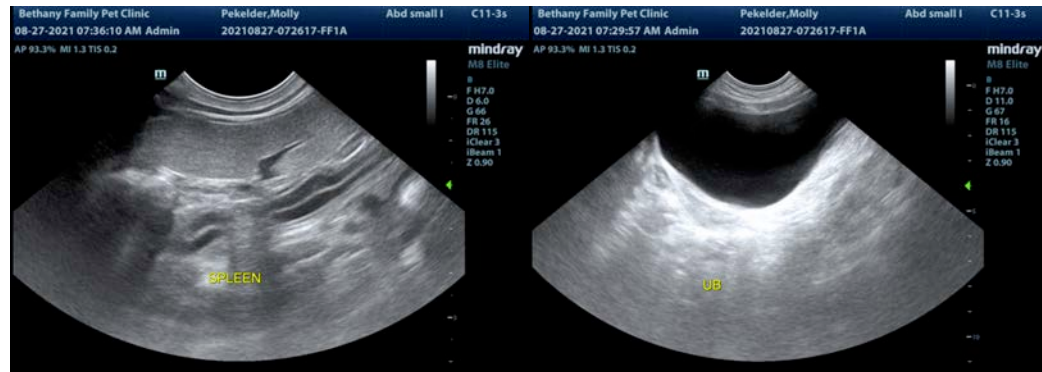
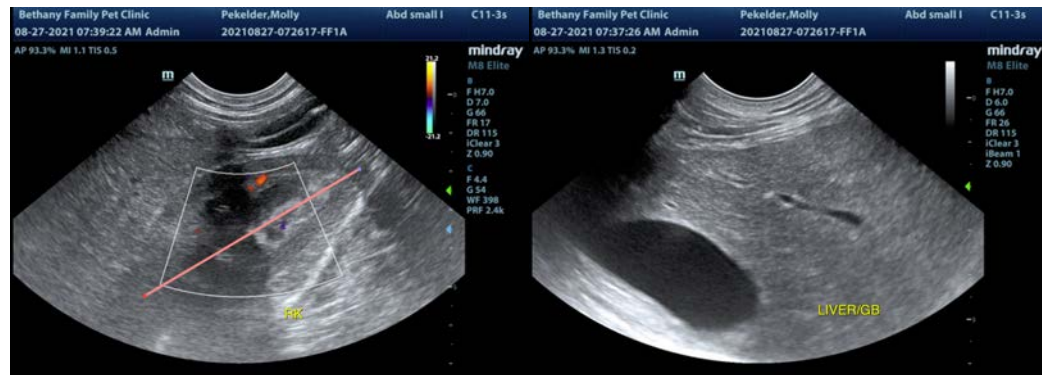
Dr. Merrill

**INVOICE**

24990

**DATE**

8/27/21



The information and recommendations provided are based on the images presented by the referring veterinarian. No evaluation can be communicated regarding pathology that was not visible in the image/video clips provided.

Thank you for this referral. If the clinical or image interpretation does not parallel your findings or if I can be of any further assistance please contact me.

Kathleen Sennello DVM,MS, Diplomate ACVIM (Small animal Internal Medicine)

kathleen.sennello@sonopath.com