

**DATE PRESENTING CLINICAL SIGNS**

8/27/21

History: Patient has a 3-month history of a clear vaginal discharge. Owner adopted with the history that she has been spayed. She has not gone into heat, but we have been unable to find a spay scar.

PATIENT

Ciara Gravatt

Current Medications: No current medications.
Lab Results: Routine CBC/GHP within normal limits.
Radiographs: Not provided by the veterinarian.

SPECIES

Canine

Date of Previous IntraPet Ultrasound: No previous IntraPet scans.
Sedation: IV sedation
Stat Report: not requested

BREED

Great Dane

LIMITED ULTRASONOGRAPHIC EXAMINATION

The urinary bladder is moderately distended with anechoic urine. The Bladder wall, trigone, ureteral papillae and visible urethra (to a depth of 2cm) appear normal with no evidence of wall thickening, mucosal irregularities, masses or cystic calculi.

SEX

Spayed Female

The left kidney has a normal shape and size (7.27 cm). Overall echogenicity is normal with adequate corticomedullary distinction and a typical 1:3 cortex:medulla ratio. There is no evidence of perinephric inflammation or effusion. There is no evidence of pyelectasia, nephroliths, infarcts or hydroureter. Renal vasculature is normal.

AGE

12/21/17

WEIGHT

97 Pounds

The right kidney has a normal shape and size (7.2 cm). Overall echogenicity is normal with adequate corticomedullary distinction and a typical 1:3 cortex:medulla ratio. There is no evidence of perinephric inflammation or effusion. There is no evidence of pyelectasia, nephroliths, infarcts or hydroureter. Renal vasculature is normal.

INTERPRETED BY

Kathleen Sennello DVM,
MS, Diplomate ACVIM
(Small Animal Internal
Medicine)

A tubular structure dorsal to the urinary bladder is visualized, most consistent with a normal uterine stump. Additionally, no tissue consistent with ovarian tissue is visualized.

ULTRASONOGRAPHIC FINDINGS

- Urogenital tract appears within normal limits – likely spayed female

HOSPITAL NAME

Madonna Vet Clinic

INTERPRETATION OF THE FINDINGS & FURTHER RECOMMENDATIONS

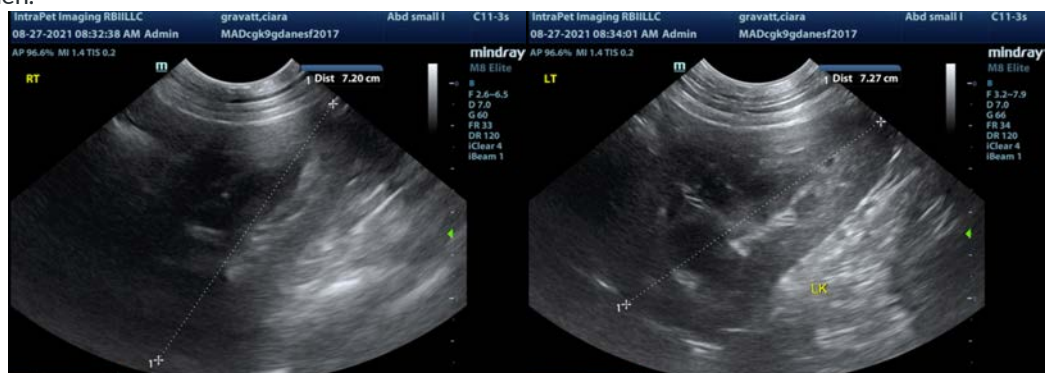
I did not see any evidence of ovaries or a uterine body on today's scan. The uterine stump is visualized and appears normal. I cannot rule out the possibility of an ovarian remnant with ultrasound, but there is low suspicion. If symptoms continued, consider vaginoscopy, vaginal cytology, hormone testing, or CT scan of the abdomen.

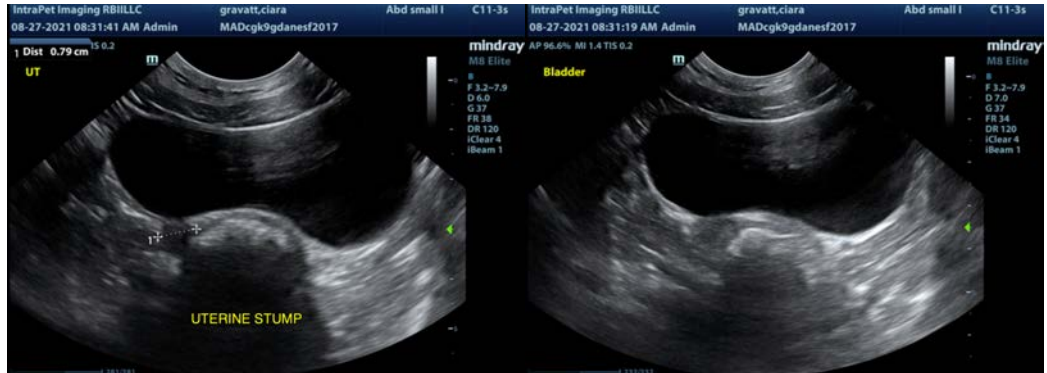
REFERRING VET

Dr. Brockett

INVOICE

25049





The information and recommendations provided are based on the images presented by the referring veterinarian. No evaluation can be communicated regarding pathology that was not visible in the image/video clips provided.

Thank you for this referral. If the clinical or image interpretation does not parallel your findings or if I can be of any further assistance please contact me.

Kathleen Sennello DVM,MS, Diplomate ACVIM (Small animal Internal Medicine)
kathleen.sennello@sonopath.com