



PATIENT

Rosie Schink

SPECIES

Canine

BREED

Goldendoodle

SEX

Spayed Female

AGE

13 Years 8 Months

WEIGHT

52 Pounds

INTERPRETED BY

Kathleen Sennello DVM,
MS, Diplomate ACVIM
(Small Animal Internal
Medicine)

**IMAGING
PERFORMED BY**

Dr. Scott

HOSPITAL NAME

Ho-Ho-Kus VH

REFERRING VET

Dr. Scott

INVOICE

24971

DATE

8/26/21

PRESENTING CLINICAL SIGNS

Hx of elevated liver enzymes, had ultrasound last sept and found benign changes. Pet came in for diarrhea, vomiting, and slightly decreased app. Is currently on denamarin, rimadyl, tramadol
Abnormal PE/Chem/CBC/UA Results: BW ALP 1500, GGT 200, ALT 192, Tbili 0.4

ULTRASONOGRAPHIC EXAMINATION OF THE ABDOMEN

Urinary System

The urinary bladder is mildly distended with anechoic urine. The Bladder wall is mildly diffusely irregular and thickened. In general, the area of the trigone, ureteral papillae and visible urethra (to a depth of 2cm) appear normal with no evidence of thickening, mucosal irregularities, masses, or cystic calculi. The appearance of the bladder wall favors cystitis or inadequate urine distention.

The left kidney has a normal shape and size (5.7 cm). Overall echogenicity is normal with adequate corticomedullary distinction and a typical 1:3 cortex:medulla ratio. There is no evidence of perinephric inflammation or effusion. There is no evidence of pyelectasia, nephroliths, infarcts or hydroureter. Renal vasculature is normal.

The right kidney has a normal shape and size. Overall echogenicity is normal with adequate corticomedullary distinction and a typical 1:3 cortex:medulla ratio. There is no evidence of perinephric inflammation or effusion. There is no evidence of pyelectasia, nephroliths, infarcts or hydroureter. Renal vasculature is normal.

Adrenal Glands

The left adrenal gland is normal in size measuring 0.73 cm at the caudal pole. It is observed in its normal position cranial to the left renal artery. It is normal in appearance (uniformly hypoechoic) and shape with no evidence of a mass effect.

The region of the right adrenal (between right cranial kidney and vena cava) is unremarkable, but the adrenal is not distinctly visualized. No evidence of a mass effect.

Spleen

The spleen is subjectively normal in size, echotexture is homogenous, and the splenic capsule is smooth with no irregularities. The blood flow through the hilus and splenic parenchyma appears normal. No focal parenchymal abnormalities are visualized.

Liver

The liver is large in size, with normal echogenicity and smooth peripheral margins. The parenchyma is heterogenous in echotexture with subtle, indistinct focal mottling. The visible portions of the vasculature and biliary tract appear normal. There is a large, hyperechoic multilobulated solid mass effect evident in the liver, measuring >8.0 cm in size. This mass is deviating the hepatic margins and the hepatic vasculature.

The gall bladder lumen is moderately distended. The wall of the gall bladder is not thickened and has a smooth mucosal surface. There is a mild amount of non-organized echogenic debris. The cystic and common bile ducts are normal/not visible.

Gastrointestinal

The stomach is moderately dilated with fluid and irregular shadowing material most consistent with normal ingesta and gas. It measures at a normal thickness of <0.7cm with some variability due to the



PATIENT

Rosie Schink

presence of rugal folds. The distinction of the gastric wall layering is adequate and there is no impression of reduced peristaltic activity. No masses or focal lesions were observed.

SPECIES

Canine

The visualized areas of duodenum, jejunum and ileum have a relatively uniform diameter with minimal fluid distension. Wall thickness is normal. Bowel loops follow a curvilinear path with distinct wall layering maintaining the typical 1:3 muscularis:mucosa layer ratio. The duodenum measured as normal (between 0.3-0.5cm in wall thickness) and the jejunum measured as normal (between 0.2-0.47cm.) Visualized peristalsis appears appropriate. There were no focal lesions consistent with obstruction or a mass effect observed.

BREED

Goldendoodle

The ileocecal junction was visualized and exhibited normal intact wall layering and is subjectively of normal thickness. Sections of colon are visualized with formed fecal material and gas shadowing distally. There is no observed focal or generalized colon wall thickening or loss of layering.

SEX

Spayed Female

Pancreas

The pancreas is normal and isoechoic to surrounding mesentery. There is no evidence of nodules or cystic lesions. There is no evidence of regional mesenteric inflammation or fluid.

AGE

13 Years 8 Months

Free Abdomen

Evaluation of the peritoneal cavity did not reveal any evidence of effusion, or subjective lymphadenomegaly. The Medial iliac nodes appear normal and there was no evidence of a caudal aortic thrombus at the bifurcation. The omentum is of normal uniform echogenicity.

WEIGHT

52 Pounds

PRIMARY FINDINGS

- Large, multilobulated, hyperechoic liver mass – appearance favors a primary hepatic neoplasia. These can be benign or malignant.

INTERPRETED BY

Kathleen Sennello DVM,
MS, Diplomate ACVIM
(Small Animal Internal
Medicine)

SECONDARY FINDINGS

- Mild gastric distention with ingesta/fluid – correlate with feeding history. If fasted, this could be consistent with delayed gastric emptying or partial obstruction (seems unlikely, not visualized)./
- Mildly irregular urinary bladder mucosa – The bladder mucosal changes could be consistent with cystitis or artifactual due to lack of adequate luminal distension. Bladder neoplasia cannot be ruled out but is considered unlikely in this patient.

IMAGING PERFORMED BY

Dr. Scott

INTERPRETATION OF THE FINDINGS & FURTHER RECOMMENDATIONS

HOSPITAL NAME

Ho-Ho-Kus VH

There is a large, multilobulated hyperechoic liver mass visualized. This appearance favors the likelihood of a primary hepatic mass. These can be benign or malignant, and even if malignant can sometimes behave benignly, as they can be slow growing and slow to metastasize. Recommend advanced imaging (CT scan) to fully evaluate the liver and the location of the mass for surgical removal. Recommend 3-view thoracic radiographs and clotting times.

REFERRING VET

Dr. Scott

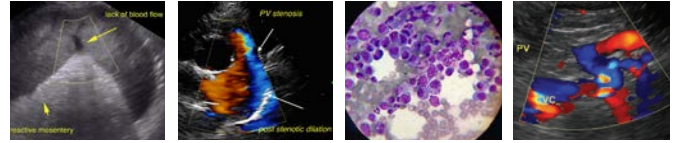
Recommend urinalysis +/- culture due to mild bladder irregularity.

INVOICE

24971

DATE

8/26/21



PATIENT

Rosie Schink

SPECIES

Canine

BREED

Goldendoodle

SEX

Spayed Female

AGE

13 Years 8 Months

WEIGHT

52 Pounds

INTERPRETED BY

Kathleen Sennello DVM,
MS, Diplomate ACVIM
(Small Animal Internal
Medicine)

**IMAGING
PERFORMED BY**

Dr. Scott

HOSPITAL NAME

Ho-Ho-Kus VH

REFERRING VET

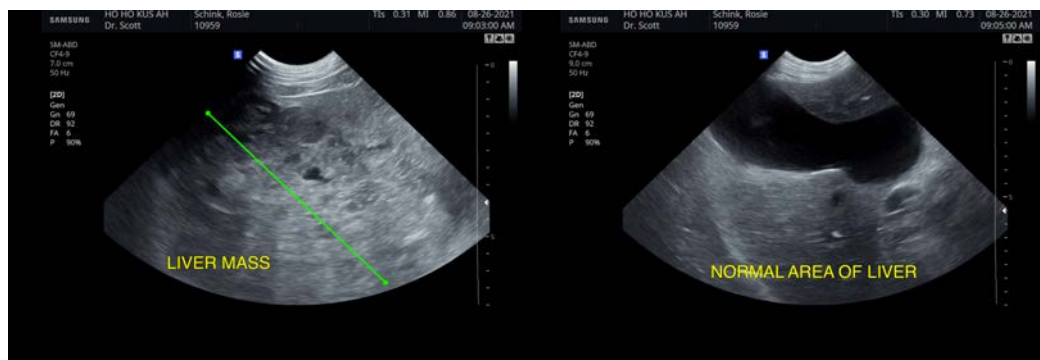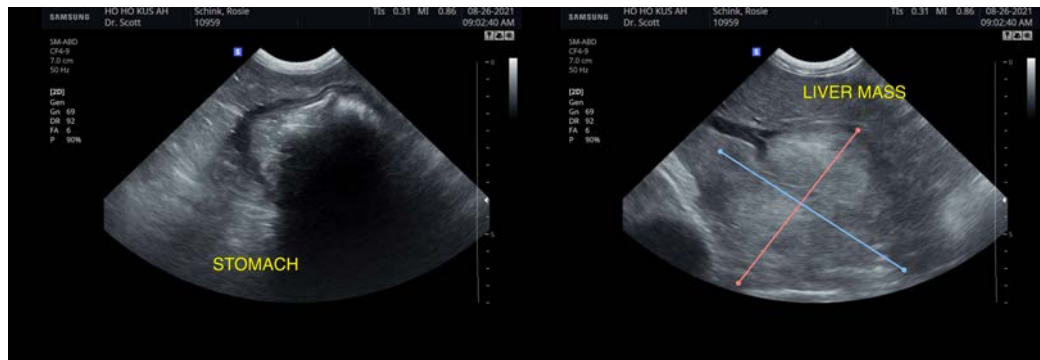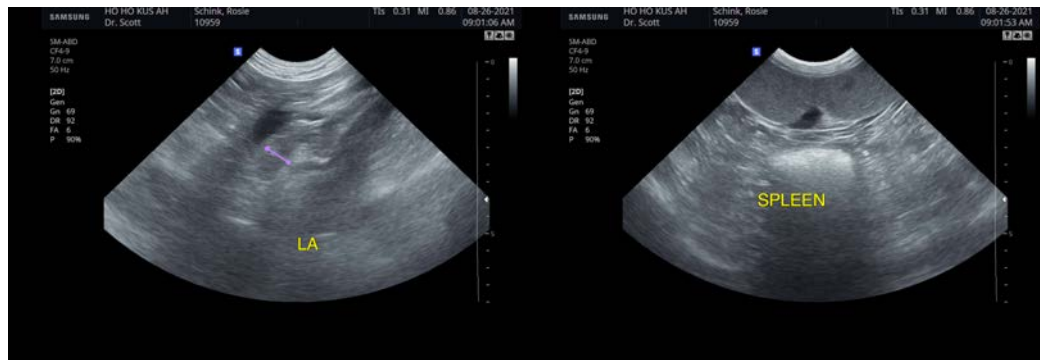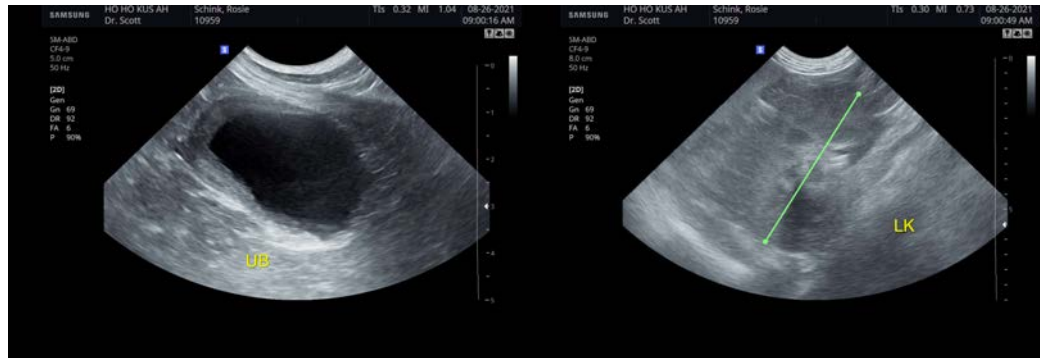Dr. Scott

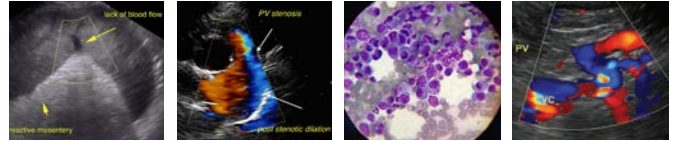
INVOICE

24971

DATE

8/26/21





PATIENT

Rosie Schink

SPECIES

Canine

BREED

Goldendoodle

SEX

Spayed Female

AGE

13 Years 8 Months

WEIGHT

52 Pounds

INTERPRETED BY

Kathleen Sennello DVM,
MS, Diplomate ACVIM
(Small Animal Internal
Medicine)

**IMAGING
PERFORMED BY**

Dr. Scott

HOSPITAL NAME

Ho-Ho-Kus VH

REFERRING VET

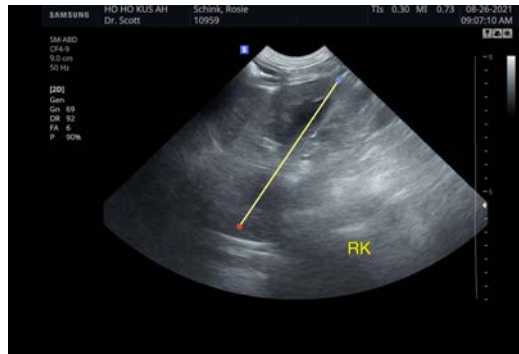Dr. Scott

INVOICE

24971

DATE

8/26/21



The information and recommendations provided are based on the images presented by the referring veterinarian. No evaluation can be communicated regarding pathology that was not visible in the image/video clips provided.

Thank you for this referral. If the clinical or image interpretation does not parallel your findings or if I can be of any further assistance please contact me.

Kathleen Sennello DVM,MS, Diplomate ACVIM (Small animal Internal Medicine)
kathleen.sennello@sonopath.com