



PATIENT

Trixie Hernday

SPECIES

Feline

BREED

DSH

SEX

Spayed Female

AGE

16 Years 4 Months

WEIGHT

10.9

INTERPRETED BY

Kathleen Sennello DVM,
MS, Diplomate ACVIM
(Small Animal Internal
Medicine)

**IMAGING
PERFORMED BY**

M. Kermendy, CVT

HOSPITAL NAME

Wauwatosa VC

REFERRING VET

Dr. Ericka Haynes

INVOICE

24936

DATE

8/25/21

PRESENTING CLINICAL SIGNS

Patient has one year history of urinating outside litter box. Mild azotemia present, no evidence of urinary tract infection. Screening for urinary tract/kidney disease.
Abnormal PE/Chem/CBC/UA Results: BUN=39 (16-37) SDMA=14 (0-14) USG=1.022

ULTRASONOGRAPHIC EXAMINATION OF THE ABDOMEN

Urinary System

The urinary bladder is moderately distended with anechoic urine. The Bladder wall, trigone, ureteral papillae and visible urethra (to a depth of 2cm) appear normal with no evidence of wall thickening, mucosal irregularities, masses or cystic calculi.

The left kidney has a normal shape and size (2.98 cm). Overall echogenicity is slightly hyperechoic with poor corticomedullary distinction and a typical 1:3 cortex:medulla ratio. There is no evidence of perinephric inflammation or effusion. There is no evidence of pyelectasia, nephroliths, infarcts or hydroureter. Renal vasculature is normal.

The right kidney has a normal shape and size (3.24 cm). Overall echogenicity is slightly hyperechoic with poor corticomedullary distinction and a typical 1:3 cortex:medulla ratio. There is no evidence of perinephric inflammation or effusion. There is no evidence of pyelectasia, nephroliths, infarcts or hydroureter. Renal vasculature is normal.

Adrenal Glands

The region of left adrenal (Cranial to left renal artery) is unremarkable but the adrenal is not distinctly visualized. No evidence of a mass effect.

The region of the right adrenal (between right cranial kidney and vena cava) is unremarkable, but the adrenal is not distinctly visualized. No evidence of a mass effect.

Spleen

The spleen is subjectively normal in size, echotexture is homogenous, and the splenic capsule is smooth with no irregularities. The blood flow through the hilus and splenic parenchyma appears normal. No focal parenchymal abnormalities are visualized.

Liver

The liver is subjectively normal in size, and echogenicity with smooth peripheral margins. The parenchyma is homogenous echotexture. The visible portions of the vasculature and biliary tract appear normal. No focal nodules or cystic lesions are observed.

The gallbladder lumen is moderately distended. The wall of the gall bladder is not thickened and has a smooth mucosal surface. Luminal contents are primarily anechoic. The cystic and common bile ducts are normal/not visible.

Gastrointestinal

The stomach contains minimal luminal contents. It measures at a normal thickness of <0.36cm with some variability due to the presence of rugal folds. The distinction of the gastric wall layers is adequate and there is no impression of reduced peristaltic activity. No masses or focal lesions were observed.

The visualized areas of duodenum, jejunum and ileum have a uniform diameter with minimal fluid distension. Wall thickness is normal to slightly increased. Bowel loops follow a typical curvilinear path with distinct wall layering, but some areas display a prominent muscularis layer which does not display



PATIENT

Trixie Hernday

the typical 1:3 muscularis:mucosa layer ratio. Jejunum wall measures 0.27 cm. Visualized peristalsis appears appropriate. There were no focal lesions consistent with obstruction or a mass effect observed.

SPECIES

Feline

The ileocecal junction was visualized and exhibited normal intact wall layering and is subjectively of normal thickness. Sections of colon are visualized with formed fecal material and gas shadowing distally. There is no observed focal or generalized colon wall thickening or loss of layering.

Pancreas

BREED

DSH

The pancreas is normal and isoechoic to surrounding mesentery. There is no evidence of nodules or cystic lesions. There is no evidence of regional mesenteric inflammation or fluid.

SEX

Spayed Female

Evaluation of the peritoneal cavity did not reveal any evidence of effusion, or subjective lymphadenomegaly. The Medial iliac nodes appear normal and there was no evidence of a caudal aortic thrombus at the bifurcation. The omentum is of normal uniform echogenicity.

ULTRASONOGRAPHIC FINDINGS

- Decreased corticomedullary distinction in both kidneys
- Prominent muscularis layer in small intestine – The small intestinal wall changes are most consistent with an inflammatory process (i.e., inflammatory bowel disease) with a low possibility of emerging lymphoma.

AGE

16 Years 4 Months

WEIGHT

10.9

INTERPRETATION OF THE FINDINGS & FURTHER RECOMMENDATIONS

The ultrasonographic changes observed are most consistent with age related progressive kidney disease. There is no evidence of stones or dilation consistent with pyelonephritis. Additionally, the bowel appears somewhat prominent, but this can be a normal change in older pets.

INTERPRETED BY

Kathleen Sennello DVM,
MS, Diplomate ACVIM
(Small Animal Internal
Medicine)

- Recommend urinalysis and culture
- Recommend blood pressure evaluation
- If well tolerated, recommend renal diet

IMAGING PERFORMED BY

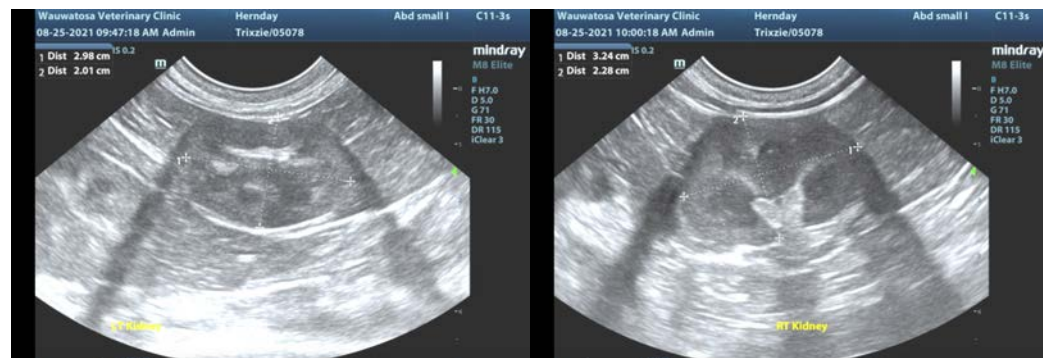
M. Kermendy, CVT

HOSPITAL NAME

Wauwatosa VC

REFERRING VET

Dr. Ericka Haynes



INVOICE

24936

DATE

8/25/21



PATIENT

Trixie Hernday

SPECIES

Feline

BREED

DSH

SEX

Spayed Female

AGE

16 Years 4 Months

WEIGHT

10.9

INTERPRETED BY

Kathleen Sennello DVM,
MS, Diplomate ACVIM
(Small Animal Internal
Medicine)

**IMAGING
PERFORMED BY**

M. Kermendy, CVT

HOSPITAL NAME

Wauwatosa VC

REFERRING VET

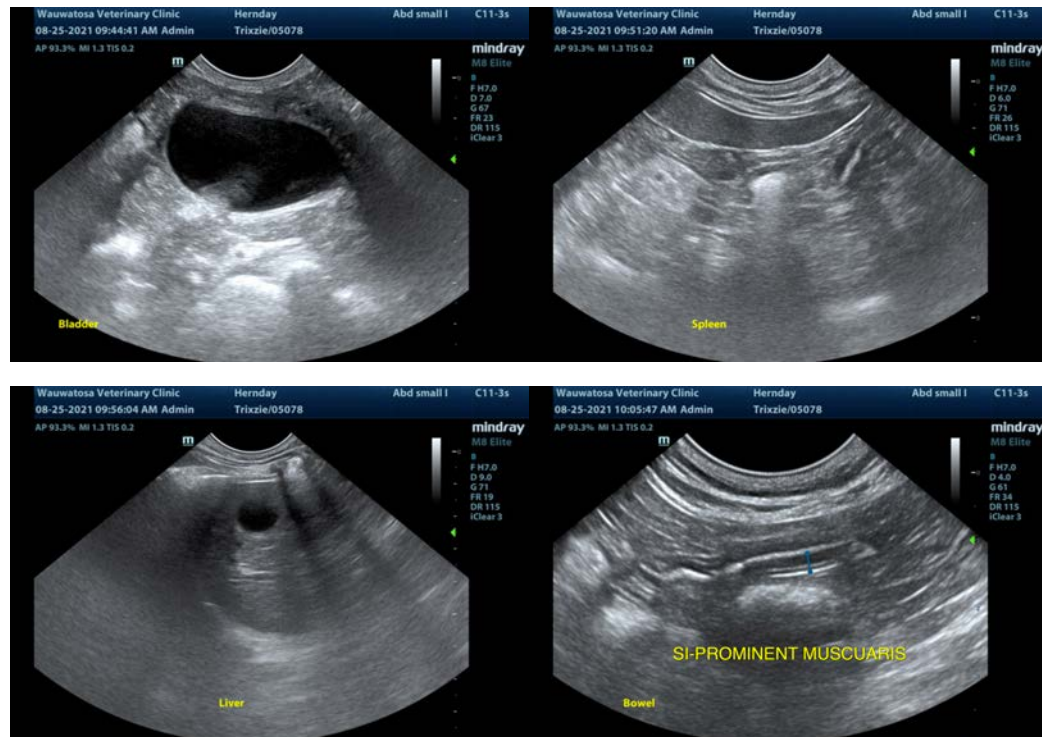
Dr. Ericka Haynes

INVOICE

24936

DATE

8/25/21



The information and recommendations provided are based on the images presented by the referring veterinarian. No evaluation can be communicated regarding pathology that was not visible in the image/video clips provided.

Thank you for this referral. If the clinical or image interpretation does not parallel your findings or if I can be of any further assistance please contact me.

Kathleen Sennello DVM,MS, Diplomate ACVIM (Small animal Internal Medicine)
kathleen.sennello@sonopath.com