IMAGING PERFORMED BY

IntraPet.com

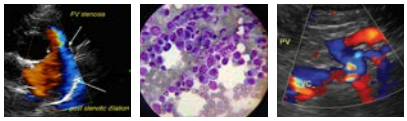

SonoPath

Clinical Sonography & Telecytology

EDUCATIONAL TELECONSULTATION SERVICES™

1-800-838-4268 info@sonopath.com SonoPath.com

DATE

8/25/21

PATIENT

Rosie D'Anna

SPECIES

Feline

BREED

DSH

SEX

Spayed Female

AGE

1/7/06

WEIGHT

13.2 Pounds

INTERPRETED BY

Kathleen Sennello DVM, MS, Diplomate ACVIM (Small Animal Internal Medicine)

HOSPITAL NAME

Frederick Road VH

REFERRING VET

Dr. Beyer

INVOICE

24924

PRESENTING CLINICAL SIGNS

History: Lost 2.62 lbs. in approximately 3 months. Chronic vomiting. (When asked-has always vomited throughout life.) Appetite waxes and wanes. No diarrhea, no lethargy, no PU/PD.

Current Medications: Cerenia (16 mg tabs) 1/4 tab PO q 24 hours PRN
Lab Results: full senior panel wnl
except mildly low TP (TP 6.2 g/dL 6.3 - 8.8 (LOW).)
Radiographs: Not provided by the veterinarian.
Date of Previous IntraPet Ultrasound: No previous IntraPet scans.
Sedation: Gabapentin PO prior to drop off.
Stat Report: not requested

ULTRASONOGRAPHIC EXAMINATION OF THE ABDOMEN

Urinary System

The urinary bladder is moderately distended with anechoic urine. The Bladder wall, trigone, ureteral papillae and visible urethra (to a depth of 2cm) appear normal with no evidence of wall thickening, mucosal irregularities, masses or cystic calculi.

The left kidney has a normal shape and size (3.54 cm). Overall echogenicity is slightly hyperechoic with poor corticomedullary distinction and a typical 1:3 cortex:medulla ratio. There is no evidence of perinephric inflammation or effusion. There is a 1.21 cm hypoechoic, rounded area in the cortex in the medial aspect of the left kidney, consistent with a left renal nodule. There is no evidence of pyelectasia, nephroliths, infarcts or hydroureter. Renal vasculature is normal.

The right kidney has a normal shape and size (4.4 cm). Overall echogenicity is slightly hyperechoic with poor corticomedullary distinction and a typical 1:3 cortex:medulla ratio. There is no evidence of perinephric inflammation or effusion. There is no evidence of pyelectasia, nephroliths, infarcts or hydroureter. Renal vasculature is normal.

Adrenal Glands

The left adrenal gland is normal in size measuring 0.50 cm at the caudal pole. It is observed in its normal position cranial to the left renal artery. It is normal in appearance (uniformly hypoechoic) and shape with no evidence of a mass effect.

The right adrenal gland is normal in size measuring 0.43 cm at the caudal pole. It is observed in its normal position between the cranial aspect of the right kidney and the caudal vena cava. It is normal in appearance (uniformly hypoechoic) and shape with no evidence of a mass effect.

Spleen

The spleen is subjectively normal in size, echotexture is homogenous, and the splenic capsule is smooth with no irregularities. The blood flow through the hilus and splenic parenchyma appears normal. No focal parenchymal abnormalities are visualized.

Liver

The liver is subjectively normal in size, and echogenicity with smooth peripheral margins. The parenchyma is homogenous echotexture. The visible portions of the vasculature and biliary tract appear normal. No focal nodules or cystic lesions are observed.

The gallbladder lumen is moderately distended. The wall of the gall bladder is not thickened and has a smooth mucosal surface. Luminal contents are primarily anechoic. The cystic and common bile ducts are normal/not visible.

Gastrointestinal

The stomach contains minimal luminal contents. It measures at a normal thickness of <0.36cm with some variability due to the presence of rugal folds. The distinction of the gastric wall layers is adequate and there is no impression of reduced peristaltic activity. No masses or focal lesions were observed.

The visualized areas of duodenum, jejunum and ileum have a uniform diameter with minimal fluid distension. Wall thickness is normal to slightly increased. Bowel loops follow a typical curvilinear path with distinct wall layering, but some areas display a prominent muscularis layer which does not display the typical 1:3 muscularis:mucosa layer ratio. Jejunum wall measures 0.27 cm. Visualized peristalsis appears appropriate. There were no focal lesions consistent with obstruction or a mass effect observed.

The ileocecal junction was visualized. The bowel in this area is abnormal and shows a loss of layering and severe thickening with the colon wall measuring 1.0 cm, creating a mass effect measuring approximately 0.98 cm x 2.31 cm. Distal colon appears more normal with intact layering and no thickening.

Pancreas

The pancreas is normal and isoechoic to surrounding mesentery. There is no evidence of nodules or cystic lesions. There is no evidence of regional mesenteric inflammation or fluid.

Free Abdomen

Evaluation of the peritoneal cavity did not reveal any evidence of effusion. There is a mild lymphadenomegaly present. Lymph nodes in the area of the colon are prominent and measured 0.3 and 0.31 cm. in a cluster in inflamed mesentery. The Medial iliac nodes appear normal and there was no evidence of a caudal aortic thrombus at the bifurcation. The omentum is of increased echogenicity in the area around the ileocecal junction.

ULTRASONOGRAPHIC FINDINGS

- Focal colonic wall thickening and loss of layering at the ileocecal junction – most consistent with a mass effect, concern for round cell neoplasia or carcinoma. Granuloma and other possibilities exist.

- Mild mesenteric lymphadenopathy – The prominent abdominal lymph nodes are most consistent with reactive lymphadenitis or lymphoid hyperplasia. Neoplastic infiltration is considered less likely.

- Decreased corticomedullary distinction in both kidneys and a hypoechoic focal lesion in the left kidney – differentials for the lesion include a metastatic lesion, an abscess or granuloma, or possibly an acute infarct.

- Subjectivley diffuse small bowel thickening and prominent muscularis layer – The small intestinal wall changes are most consistent with an inflammatory process (i.e., inflammatory bowel disease) with a low possibility of emerging lymphoma.

INTERPRETATION OF THE FINDINGS & FURTHER RECOMMENDATIONS

The focal lesion involving the ileocecal junction is the likely cause of the symptoms described. Recommend fine needle aspirate of the colonic wall to try to obtain a cytologic diagnosis. Differentials include round cell neoplasia, carcinoma, FIP, granuloma, etc. If a cytologic diagnosis is not possible, consider surgery to biopsy and remove this area. Additionally, there is a lesion in the left kidney. The nature of this lesion is not clear, but there is concern for a possible metastatic lesion. Consider continued monitoring with ultrasound. Recommend 3-view thoracic radiographs.

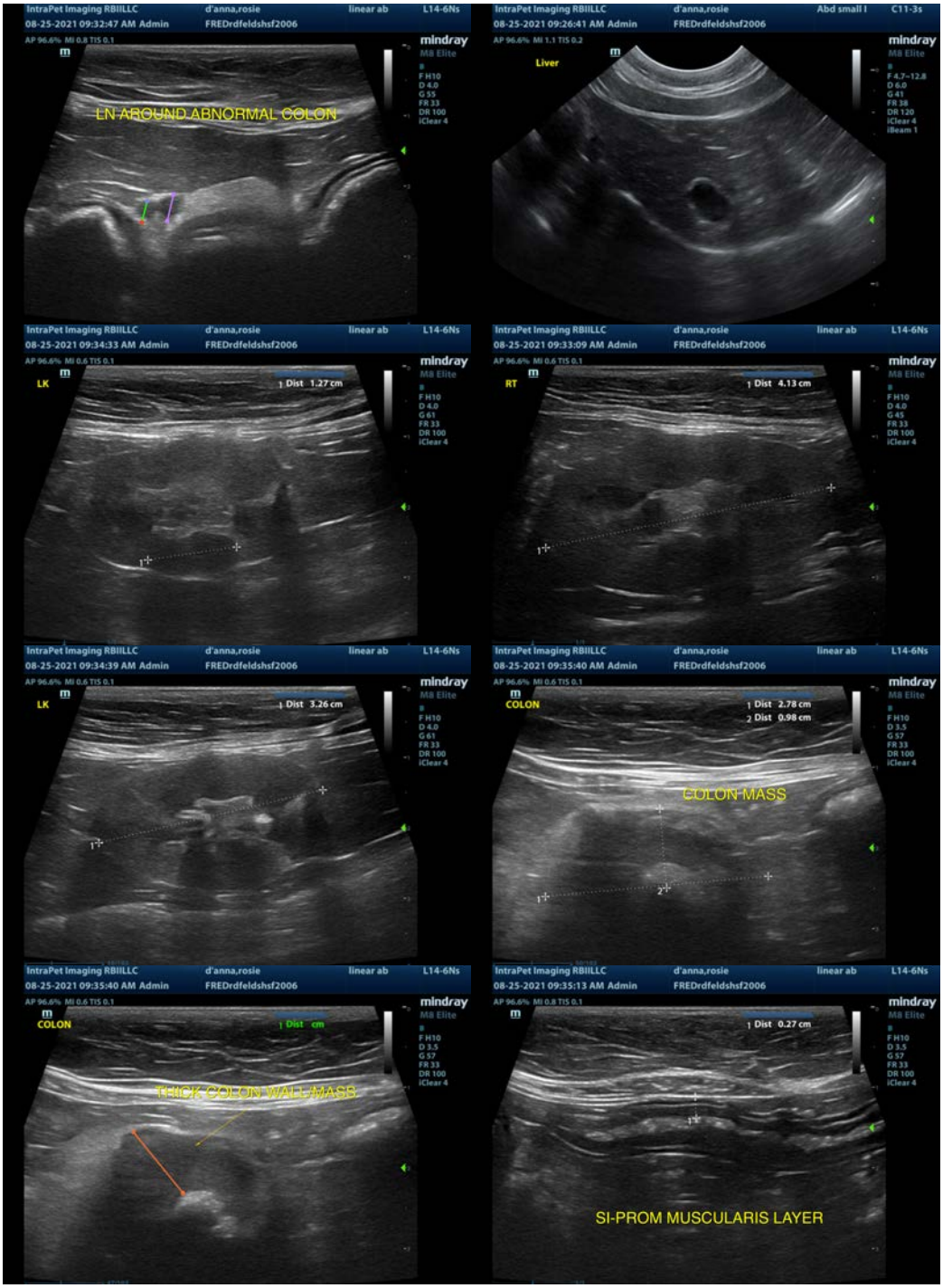
IntraPet Imaging RBIILLC
d'anna,rosie
linear ab
L14-6Ns
08-25-2021 09:32:47 AM Admin
FREDrdfeldshsf2006
mindray
LN AROUND ABNORMAL COLON
IntraPet Imaging RBIILLC
d'anna,rosie
Abd small I
C11-3s
08-25-2021 09:26:41 AM Admin
FREDrdfeldshsf2006
Liver
IntraPet Imaging RBIILLC
d'anna,rosie
linear ab
L14-6Ns
08-25-2021 09:34:33 AM Admin
FREDrdfeldshsf2006
LK
1 Dist 1.27 cm
IntraPet Imaging RBIILLC
d'anna,rosie
linear ab
L14-6Ns
08-25-2021 09:33:09 AM Admin
FREDrdfeldshsf2006
RT
1 Dist 4.13 cm
IntraPet Imaging RBIILLC
d'anna,rosie
linear ab
L14-6Ns
08-25-2021 09:34:39 AM Admin
FREDrdfeldshsf2006
LK
1 Dist 3.26 cm
IntraPet Imaging RBIILLC
d'anna,rosie
linear ab
L14-6Ns
08-25-2021 09:35:40 AM Admin
FREDrdfeldshsf2006
COLON
1 Dist 2.78 cm
2 Dist 0.98 cm
COLON MASS
IntraPet Imaging RBIILLC
d'anna,rosie
linear ab
L14-6Ns
08-25-2021 09:35:40 AM Admin
FREDrdfeldshsf2006
COLON
1 Dist cm
THICK COLON WALL MASS
IntraPet Imaging RBIILLC
d'anna,rosie
linear ab
L14-6Ns
08-25-2021 09:35:13 AM Admin
FREDrdfeldshsf2006
1 Dist 0.27 cm
SI-PROM MUSCULARIS LAYER

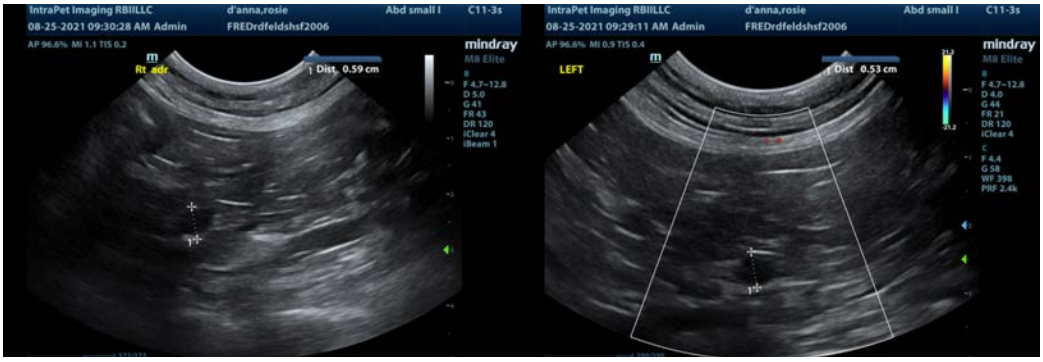

The information and recommendations provided are based on the images presented by the referring veterinarian. No evaluation can be communicated regarding pathology that was not visible in the image/video clips provided.

Thank you for this referral. If the clinical or image interpretation does not parallel your findings or if I can be of any further assistance please contact me.

Kathleen Sennello DVM,MS, Diplomate ACVIM (Small animal Internal Medicine)
kathleen.sennello@sonopath.com