

**DATE PRESENTING CLINICAL SIGNS**

8/25/21

History: Decreased appetite, on/off vomiting, and weight loss. Had previous u/s with IM specialist when went to ER for vomiting (6/8/2021); thickening in stomach, 4 cm nodule in spleen, cysts on kidneys. Was treated with Metoclopramide, Cerenia, Omeprazole, Mirtazapine, bland diet in hospital, and sent home on Omeprazole and bland diet.

**PATIENT**

Maverick Church

**SPECIES**

Canine

**BREED**

Anatolian Shep X

**SEX**

Neutered Male

**AGE**

6/13/11

**WEIGHT**

86.4 Pounds

**INTERPRETED BY**

Kathleen Sennello DVM,  
MS, Diplomate ACVIM  
(Small Animal Internal  
Medicine)

**HOSPITAL NAME**

Frederick Road VH

**REFERRING VET**

Dr. Beyer

**INVOICE**

24932

Current Medications: Omeprazole, Cerenia, GI Low Fat Diet.

Lab Results: CORTISOL 1.6 ug/dL 2.0 - 6.0 (Low) SPEC cPL 61 ug/L 0 - 200.

Radiographs: Attached separately. Ultrasound report: Area examined: Abdomen

Findings:

LIVER: Normal in size and shape; margins are smooth and regular, normal architecture and normal echogenicity. No masses are seen.

GALLBLADDER / CBD: Normally distended with anechoic bile. Visible biliary tree appears normal.

SPLEEN: ~ 4cm heterogenous nodule caudal to hilus

KIDNEYS: Normal in size, shape, echogenicity, with few small cortical cysts. No calculi noted; no pyelectasia or ureteral dilation seen.

ADRENALS: Normal in size and symmetric in shape

GI TRACT: Stomach contains mod to large volume fluid and smaller amount of gas; the visible portions of the gastric wall appear are

variably increased in thickness. Pylorus/pyloric duodenal junction is difficult to see but the pylorus does not appear to have obstruction.

Within the fluid there is hyperechoic non shadowing straight debris. Duodenum is normal in thickness and layering pattern. Jejunum is

normal in thickness and layering pattern. Ileum/ileocolic junction is not seen. Colon is normal.

PANCREAS: Appears normal with normal peripancreatic soft tissues.

LYMPH NODES: Mesenteric, medial iliac, and sub lumbar lymph nodes are normal

URINARY BLADDER: Moderately distended with anechoic urine. Bladder wall is normal. No masses or calculi are identified.

REPRODUCTIVE: Prostate is normal in size and shape with normal homogenous architecture; no distinct masses identified.

ADDITIONAL COMMENTS: Peritoneal fat, omentum, and mesenteries appear normal. No free fluid present.

ASSESSMENT:

Fluid dilated stomach - r/o functional ileus vs. mechanical ileus not visualized

~3cm thin straight material suspended in gastric contents- r/o grass/plant material vs. less likely foreign material

Visible portions of the gastric wall appear are variably increased in thickness- r/o inflammation/gastritis vs. ulceration vs. less likely

neoplasia

Mild renal cortical changes

Splenic nodule- r/o benign vs. malignant changes

see measurement image page for size references

**RECOMMENDATIONS/DISCUSSION:**

Consider supportive care with gastroprotectants +- promotility medications. If vomiting continues, recommend gastroscopy to assess stomach contents and gastric wall.

Significance of the splenic nodule is unknown a both benign or malignant lesions are possible. Consider serial monitoring every 2-3

months or fine needle aspirate to help rule out underlying neoplasia. This is unlikely to be related to the current clinical signs.

Date of Previous IntraPet Ultrasound: No previous IntraPet scans.

Sedation: IV utilized for AUS (Butorphanol (10 mg/ml) 0.8 mls IV and Midazolam (5 mg/ml) 0.8 mls IV)

Stat Report: not requested

## **ULTRASONOGRAPHIC EXAMINATION OF THE ABDOMEN**

### ***Urinary System***

The urinary bladder is moderately distended with anechoic urine. The Bladder wall, trigone, ureteral papillae and visible urethra (to a depth of 2cm) appear normal with no evidence of wall thickening, mucosal irregularities, masses or cystic calculi.

The prostate is normal in size (2.2 cm) and shape for this neutered male dog. The parenchyma is homogenous and the external margins are smooth. The prostatic urethra appears normal with no evidence of irregularity, invasion, mass effect or calculi.

The left kidney has a normal shape and size (7.1 cm). Overall echogenicity is normal with adequate corticomedullary distinction and a typical 1:3 cortex:medulla ratio. There is no evidence of perinephric inflammation or effusion. There is no evidence of pyelectasia, nephroliths, infarcts or hydroureter. Renal vasculature is normal.

The right kidney has a normal shape and size (6.24 cm). Overall echogenicity is normal with adequate corticomedullary distinction and a typical 1:3 cortex:medulla ratio. There is no evidence of perinephric inflammation or effusion. There is no evidence of pyelectasia, nephroliths, infarcts or hydroureter. Renal vasculature is normal.

### ***Adrenal Glands***

The left adrenal gland is normal in size measuring 0.77 cm at the caudal pole. It is observed in its normal position cranial to the left renal artery. It is normal in appearance (uniformly hypoechoic) and shape with no evidence of a mass effect.

The right adrenal gland is normal in size measuring 0.66 cm at the caudal pole. It is observed in its normal position between the cranial aspect of the right kidney and the caudal vena cava. It is normal in appearance (uniformly hypoechoic) and shape with no evidence of a mass effect.

### ***Spleen***

The spleen is subjectively normal in size. The spleen echotexture is heterogenous and mottled, the splenic capsule is smooth with no irregularities. The blood flow through the hilus and splenic parenchyma appears normal. There is a bulging mixed echogenic, somewhat moth eaten appearing mass effect in the mid body of the spleen near the hilus, measuring approximately 6.75 cm x 4.2 cm. There is no evidence of free fluid or inflammation surrounding the spleen.

### ***Liver***

The liver is subjectively normal in size, and echogenicity with smooth peripheral margins. The parenchyma is homogenous echotexture. The visible portions of the vasculature and biliary tract appear normal. No focal nodules or cystic lesions are observed.

The gallbladder lumen is moderately distended. The wall of the gall bladder is not thickened and has a smooth mucosal surface. Luminal contents are primarily anechoic. The cystic and common bile ducts are normal/not visible.

### ***Gastrointestinal***

The stomach contains minimal luminal contents. The stomach wall measures 0.72 cm. distinction of the gastric wall layers is adequate and there is no impression of reduced peristaltic activity. No masses or focal lesions were observed.

The visualized areas of duodenum, jejunum and ileum have a relatively uniform diameter with minimal fluid distension. Wall thickness is normal. Bowel loops follow a curvilinear path with distinct wall layering maintaining the typical 1:3 muscularis:mucosa layer ratio. Duodenum wall measured 0.37 cm. Jejunum wall measured 0.31 cm. Visualized peristalsis appears appropriate. There were no focal lesions consistent with obstruction or a mass effect observed.

The ileocecal junction was visualized and exhibited normal intact wall layering and is subjectively of normal thickness. Sections of colon are visualized with formed fecal material and gas shadowing distally. There is no observed focal or generalized colon wall thickening or loss of layering.

### ***Pancreas***

The pancreas is normal and isoechoic to surrounding mesentery. There is no evidence of nodules or cystic lesions. There is no evidence of regional mesenteric inflammation or fluid.

### ***Free Abdomen***

Evaluation of the peritoneal cavity did not reveal any evidence of effusion, or subjective lymphadenomegaly. The Medial iliac nodes appear normal and there was no evidence of a caudal aortic thrombus at the bifurcation. The omentum is of normal uniform echogenicity.

### ***Other***

A brief view of the heart was submitted. No pericardial effusion was seen.

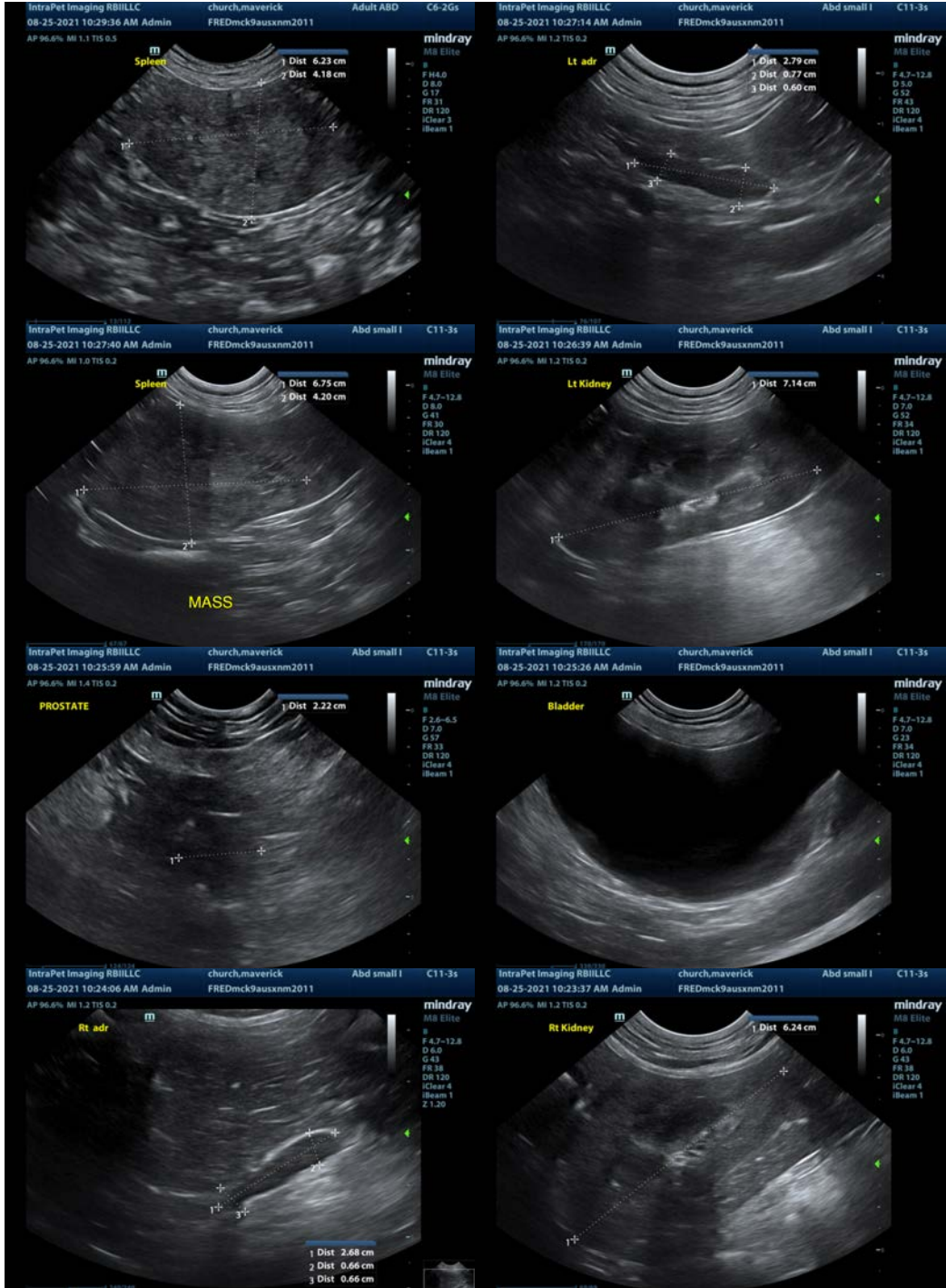
## **ULTRASONOGRAPHIC FINDINGS**

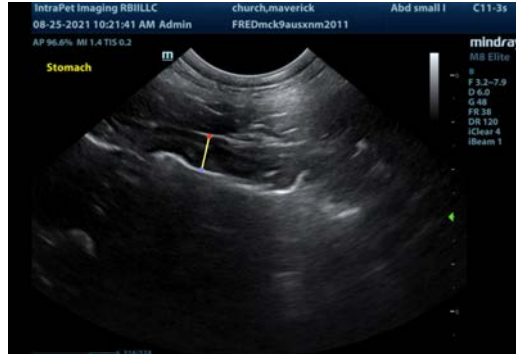- Mixed echogenic splenic mass – differentials include lymphoid hyperplasia, extramedullary hematopoiesis, infiltrative neoplasia, inflammation, and other. Cytology or histopathology may be necessary to get a definitive diagnosis.

## **INTERPRETATION OF THE FINDINGS & FURTHER RECOMMENDATIONS**

The previously identified splenic lesion appears stable to slightly enlarged. This lesion is non-cavitated, but still has the potential to be a cancerous lesion. Additionally, benign lesions can still rupture, so I typically recommend removal of all sizable splenic masses for histopathology and prevention. Recommend 3-view thoracic radiographs. You could consider obtaining full thickness GI biopsies at the time of surgery to obtain more information about the reported GI Signs.

Additionally, consider a GI panel for a quantitative PLI, folate and cobalamin, as this can help to get additional information on the health of the GI tract. General differentials I consider for intermittent anorexia, etc. include GI parasitism, dietary indiscretion, mild pancreatitis, bacterial dysbiosis, food allergy, IBD, and less likely intestinal neoplasia. To be 100% safe I would recommend a pre- and post ACTH stim to rule out Addison's disease. If a diet trial is desired, I would consider a novel protein/hydrolyzed prescription diet.





**The information and recommendations provided are based on the images presented by the referring veterinarian. No evaluation can be communicated regarding pathology that was not visible in the image/video clips provided.**

Thank you for this referral. If the clinical or image interpretation does not parallel your findings or if I can be of any further assistance please contact me.

Kathleen Sennello DVM,MS, Diplomate ACVIM (Small animal Internal Medicine)  
kathleen.sennello@sonopath.com