



**PATIENT**

Margot Chapman

**SPECIES**

Canine

**BREED**

Corgi

**SEX**

Spayed Female

**AGE**

2 Years

**WEIGHT**

10.2 kg

**INTERPRETED BY**

Kathleen Sennello  
DVM, MS, Diplomate  
ACVIM (Small Animal  
Internal Medicine)

**IMAGING PERFORMED BY**

Crystal Hill

**HOSPITAL NAME**

Sixteen Mile VC

**REFERRING VET**

Dr. Bile

**INVOICE**

24938

**DATE**

8/25/21

**PRESENTING CLINICAL SIGNS**

Episodes of straining to urinate, frequent urination, sometimes no urine produced. Minimal response to antibiotics. On Clavaseptin BID  
Abnormal PE/Chem/CBC/UA Results: Sp grav - 1.010 pH 6.5 rest NSF Pre antibiotics u/a - Sp grav - 1.031 pH 6.5 Leuks 2+ Blood 4+

**ULTRASONOGRAPHIC EXAMINATION OF THE ABDOMEN**

**Urinary System**

The urinary bladder is moderately distended with anechoic urine. The Bladder wall, trigone, ureteral papillae and visible urethra (to a depth of 2cm) appear normal with no evidence of wall thickening, mucosal irregularities, masses or cystic calculi.

The left kidney has a normal shape and size (3.79 cm). Overall echogenicity is normal with adequate corticomedullary distinction and a typical 1:3 cortex:medulla ratio. There is no evidence of perinephric inflammation or effusion. There is no evidence of pyelectasia, nephroliths, infarcts or hydroureter. Renal vasculature is normal.

The right kidney has a normal shape and size (4.43 cm). Overall echogenicity is normal with adequate corticomedullary distinction and a typical 1:3 cortex:medulla ratio. There is no evidence of perinephric inflammation or effusion. There is no evidence of pyelectasia, nephroliths, infarcts or hydroureter. Renal vasculature is normal.

**Adrenal Glands**

The left adrenal gland is normal in size measuring 0.44 cm at the caudal pole. It is observed in its normal position cranial to the left renal artery. It is normal in appearance (uniformly hypoechoic) and shape with no evidence of a mass effect.

The right adrenal gland is normal in size measuring 0.38 cm at the caudal pole. It is observed in its normal position between the cranial aspect of the right kidney and the caudal vena cava. It is normal in appearance (uniformly hypoechoic) and shape with no evidence of a mass effect.

**Spleen**

The spleen is subjectively normal in size, echotexture is homogenous, and the splenic capsule is smooth with no irregularities. The blood flow through the hilus and splenic parenchyma appears normal. No focal parenchymal abnormalities are visualized.

**Liver**

The stomach is moderately dilated with fluid and irregular shadowing material most consistent with normal ingesta and gas. It measures at a normal thickness of <0.7cm with some variability due to the presence of rugal folds. The distinction of the gastric wall layering is adequate and there is no impression of reduced peristaltic activity. No masses or focal lesions were observed.

The gallbladder lumen is moderately distended. The wall of the gall bladder is not thickened and has a smooth mucosal surface. Luminal contents are primarily anechoic. The cystic and common bile ducts are normal/not visible.



**PATIENT**

Margot Chapman

**SPECIES**

Canine

**BREED**

Corgi

**SEX**

Spayed Female

**AGE**

2 Years

**WEIGHT**

10.2 kg

**INTERPRETED BY**

Kathleen Sennello  
DVM, MS, Diplomate  
ACVIM (Small Animal  
Internal Medicine)

**IMAGING PERFORMED BY**

Crystal Hill

**HOSPITAL NAME**

Sixteen Mile VC

**REFERRING VET**

Dr. Bile

**INVOICE**

24938

**DATE**

8/25/21

**Gastrointestinal**

The stomach contains minimal luminal contents. It measures at a normal thickness of <0.7cm with some variability due to the presence of rugal folds. The distinction of the gastric wall layers is adequate and there is no impression of reduced peristaltic activity. No masses or focal lesions were observed.

The visualized areas of duodenum, jejunum and ileum have a relatively uniform diameter with minimal fluid distension. Wall thickness is normal. Bowel loops follow a curvilinear path with distinct wall layering maintaining the typical 1:3 muscularis:mucosa layer ratio. The duodenum measured as normal (between 0.3-0.5cm in wall thickness) and the jejunum measured as normal (between 0.2-0.47cm.) Visualized peristalsis appears appropriate. There were no focal lesions consistent with obstruction or a mass effect observed.

The ileocecal junction was visualized and exhibited normal intact wall layering and is subjectively of normal thickness. Sections of colon are visualized with formed fecal material and gas shadowing distally. There is no observed focal or generalized colon wall thickening or loss of layering.

**Pancreas**

The pancreas is normal and isoechoic to surrounding mesentery. There is no evidence of nodules or cystic lesions. There is no evidence of regional mesenteric inflammation or fluid.

**Free Abdomen**

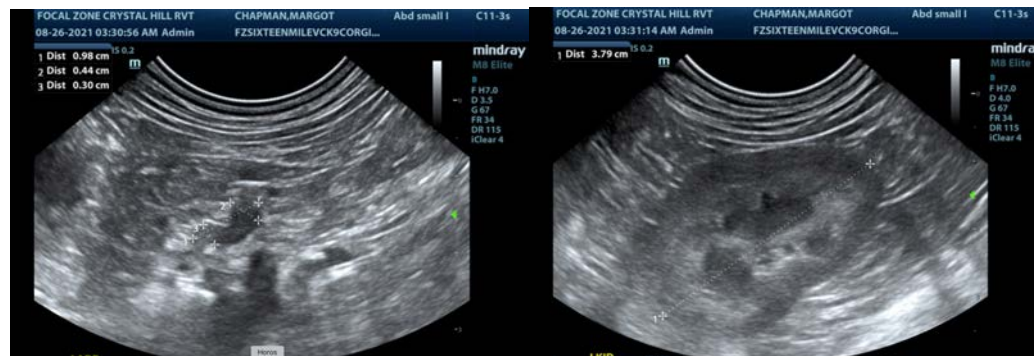
Evaluation of the peritoneal cavity did not reveal any evidence of effusion, or subjective lymphadenomegaly. The Medial iliac nodes appear normal and there was no evidence of a caudal aortic thrombus at the bifurcation. The omentum is of normal uniform echogenicity.

**ULTRASONOGRAPHIC FINDINGS**

- Mild fluid dilation of stomach – correlate with feeding history. If fasted, this could be consistent with delayed gastric emptying or a partial obstruction (not seen).

**INTERPRETATION OF THE FINDINGS & FURTHER RECOMMENDATIONS**

I do not see an obvious lesion to explain the stranguria and hematuria reported. If this hasn't been done, recommend a urine culture at least 5-7 days post discontinuation of antibiotics. Recommend urinalysis with a microscopic exam to look for bacteria, etc. If symptoms persistent and infection is ruled out, consider urine BRAF test to test for TCC. This test is of no use if it negative (does not rule out neoplasia). If it is positive, it is not 100% diagnostic, but would increase suspicion. This seems unlikely in this young of a dog. Recommend rectal palpation of urethra to feel for thickening and consider vaginoscopy and cystoscopy to evaluate the lower urinary tract.





**PATIENT**

Margot Chapman

**SPECIES**

Canine

**BREED**

Corgi

**SEX**

Spayed Female

**AGE**

2 Years

**WEIGHT**

10.2 kg

**INTERPRETED BY**

Kathleen Sennello  
DVM, MS, Diplomate  
ACVIM (Small Animal  
Internal Medicine)

**IMAGING  
PERFORMED BY**

Crystal Hill

**HOSPITAL NAME**

Sixteen Mile VC

**REFERRING VET**

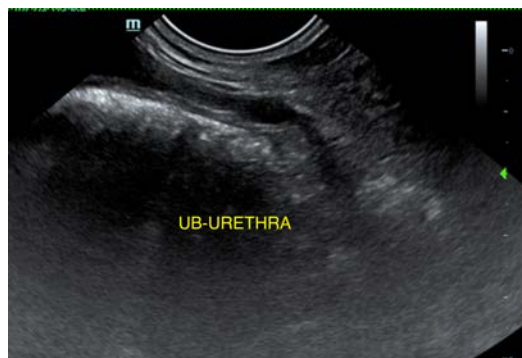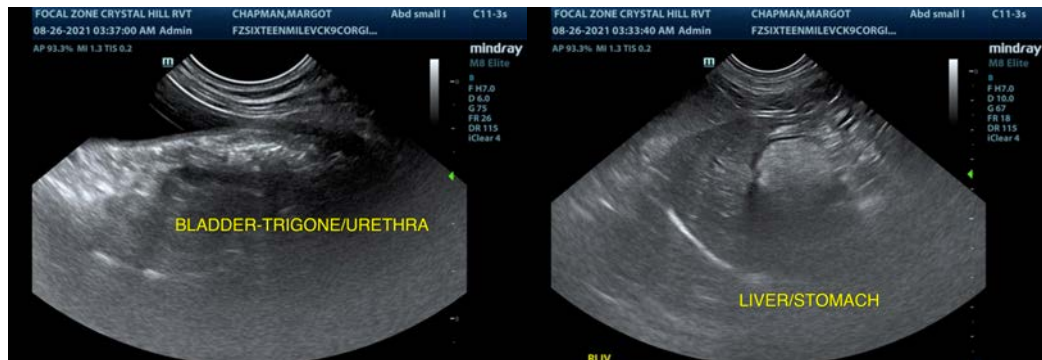
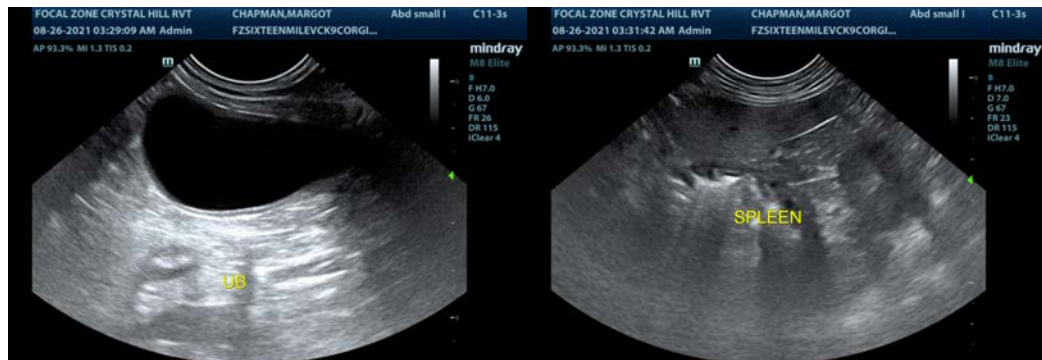
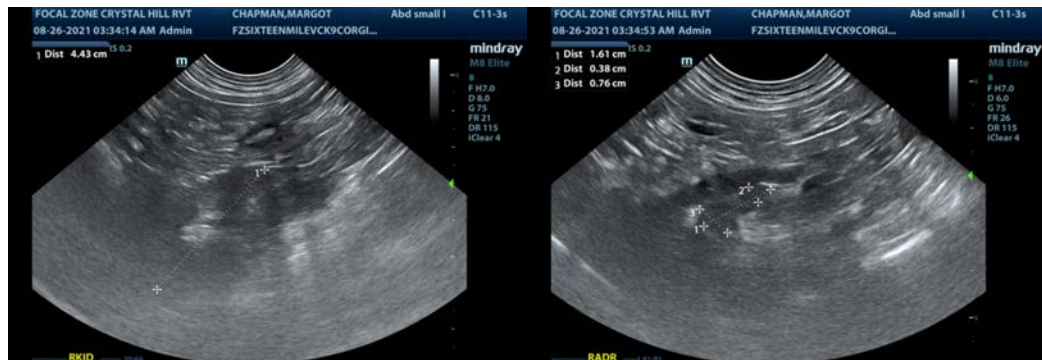
Dr. Bile

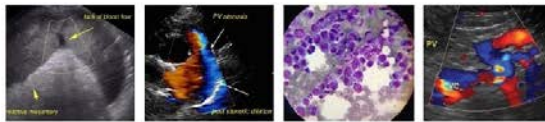
**INVOICE**

24938

**DATE**

8/25/21





**PATIENT**

Margot Chapman

The information and recommendations provided are based on the images presented by the referring veterinarian. No evaluation can be communicated regarding pathology that was not visible in the image/video clips provided.

**SPECIES**

Canine

Thank you for this referral. If the clinical or image interpretation does not parallel your findings or if I can be of any further assistance please contact me.

Kathleen Sennello DVM,MS, Diplomate ACVIM (Small animal Internal Medicine)

**BREED**

Corgi

kathleen.sennello@sonopath.com

**SEX**

Spayed Female

**AGE**

2 Years

**WEIGHT**

10.2 kg

**INTERPRETED BY**

Kathleen Sennello  
DVM, MS, Diplomate  
ACVIM (Small Animal  
Internal Medicine)

**IMAGING  
PERFORMED BY**

Crystal Hill

**HOSPITAL NAME**

Sixteen Mile VC

**REFERRING VET**

Dr. Bile

**INVOICE**

24938

**DATE**

8/25/21