

**DATE PRESENTING CLINICAL SIGNS**

8/25/21 History: first presented with firm abdomen, PU/PD, getting winded going up steps, etc.

PATIENT -treated symptomatically for pancreatitis (Buprenex, low fat diet, Cerenia)
improved clinical signs

Ginger Boquard ALP increased to 1000 and spec cPL decreased from 968 to 499.

SPECIES Current Medications: Buprenex PRN, Cerenia PRN, RC GI low fat diet only.

Canine

Lab Results: Main concerns: elevated ALP and elevated spec cpl.
UPC 2.8 (was 3.6 prior to treatment for pancreatitis). Eosinopenia, lymphopenia, elevated BUN.

Radiographs: enlarged liver on radiographs; subjectively enlarged cardiac silhouette.

BREED

Date of Previous IntraPet Ultrasound: No previous IntraPet scans.

Sedation: not needed

Stat Report: not requested

Yorkshire Terrier

SEX

ULTRASONOGRAPHIC EXAMINATION OF THE ABDOMEN

Spayed Female

Urinary System

The urinary bladder is moderately distended with anechoic urine. The Bladder wall, trigone, ureteral papillae and visible urethra (to a depth of 2cm) appear normal with no evidence of wall thickening, mucosal irregularities, masses or cystic calculi.

AGE

6/27/10

The left kidney has a normal shape and size (4.51 cm). Overall echogenicity is slightly hyperechoic with mildly decreased corticomedullary distinction and a typical 1:3 cortex:medulla ratio. There is no evidence of perinephric inflammation or effusion. Rare small cortical cysts are present. There is no evidence of pyelectasia, nephroliths, infarcts or hydroureter. Renal vasculature is normal.

WEIGHT

12.8 Pounds

The right kidney has a normal shape and size (4.64 cm). Overall echogenicity is slightly hyperechoic with mildly decreased corticomedullary distinction and a typical 1:3 cortex:medulla ratio. There is no evidence of perinephric inflammation or effusion. Rare small cortical cysts are present. There is no evidence of pyelectasia, nephroliths, infarcts or hydroureter. Renal vasculature is normal.

INTERPRETED BY

Kathleen Sennello DVM,
MS, Diplomate ACVIM
(Small Animal Internal
Medicine)

Adrenal Glands

The left adrenal gland is normal/mildly enlarged in size measuring 0.8 cm at the caudal pole. It is observed in its normal position cranial to the left renal artery. It is normal in appearance (uniformly hypoechoic) and shape with no evidence of a mass effect.

HOSPITAL NAME

Frederick Road VH

The right adrenal gland is normal/borderline enlarged in size measuring 0.73 cm at the caudal pole. It is observed in its normal position between the cranial aspect of the right kidney and the caudal vena cava. It is normal in appearance (uniformly hypoechoic) and shape with no evidence of a mass effect.

REFERRING VET

Dr. Beyer

Spleen

The spleen is subjectively normal in size, echotexture is homogenous, and the splenic capsule is smooth with no irregularities. The blood flow through the hilus and splenic parenchyma appears normal. No focal parenchymal abnormalities are visualized.

INVOICE

24925

Liver

The liver is large in size, with normal echogenicity and smooth peripheral margins. The parenchyma is heterogenous in echotexture with subtle, indistinct focal mottling. The visible portions of the vasculature and biliary tract appear normal. No focal nodules or cystic lesions are observed.

The gall bladder lumen is moderately distended. The wall of the gall bladder is not thickened and has a smooth mucosal surface. There is a moderate amount of non-organized echogenic debris with small mineralized, shadowing stones. The cystic and common bile ducts are normal/not visible.

Gastrointestinal

The stomach contains minimal luminal contents. It measures at a normal thickness of <0.7cm with some variability due to the presence of rugal folds. The distinction of the gastric wall layers is adequate and there is no impression of reduced peristaltic activity. No masses or focal lesions were observed.

The visualized areas of duodenum, jejunum and ileum have a relatively uniform diameter with minimal fluid distension. Wall thickness is normal. Bowel loops follow a curvilinear path with distinct wall layering maintaining the typical 1:3 muscularis:mucosa layer ratio. The duodenum measured as normal (between 0.3-0.5cm in wall thickness) and the jejunum measured as normal (between 0.2-0.47cm.) Visualized peristalsis appears appropriate. There were no focal lesions consistent with obstruction or a mass effect observed.

The ileocecal junction was visualized and exhibited normal intact wall layering and is subjectively of normal thickness. Sections of colon are visualized with formed fecal material and gas shadowing distally. There is no observed focal or generalized colon wall thickening or loss of layering.

Pancreas

The pancreas is large and hypoechoic to surrounding mesentery. There is no evidence of nodules or cystic lesions. There is evidence of regional mesenteric inflammation. Consistent with moderate pancreatitis.

Free Abdomen

Evaluation of the peritoneal cavity did not reveal any evidence of effusion, or subjective lymphadenomegaly. The Medial iliac nodes appear normal and there was no evidence of a caudal aortic thrombus at the bifurcation. The omentum is of normal uniform echogenicity.

PRIMARY FINDINGS

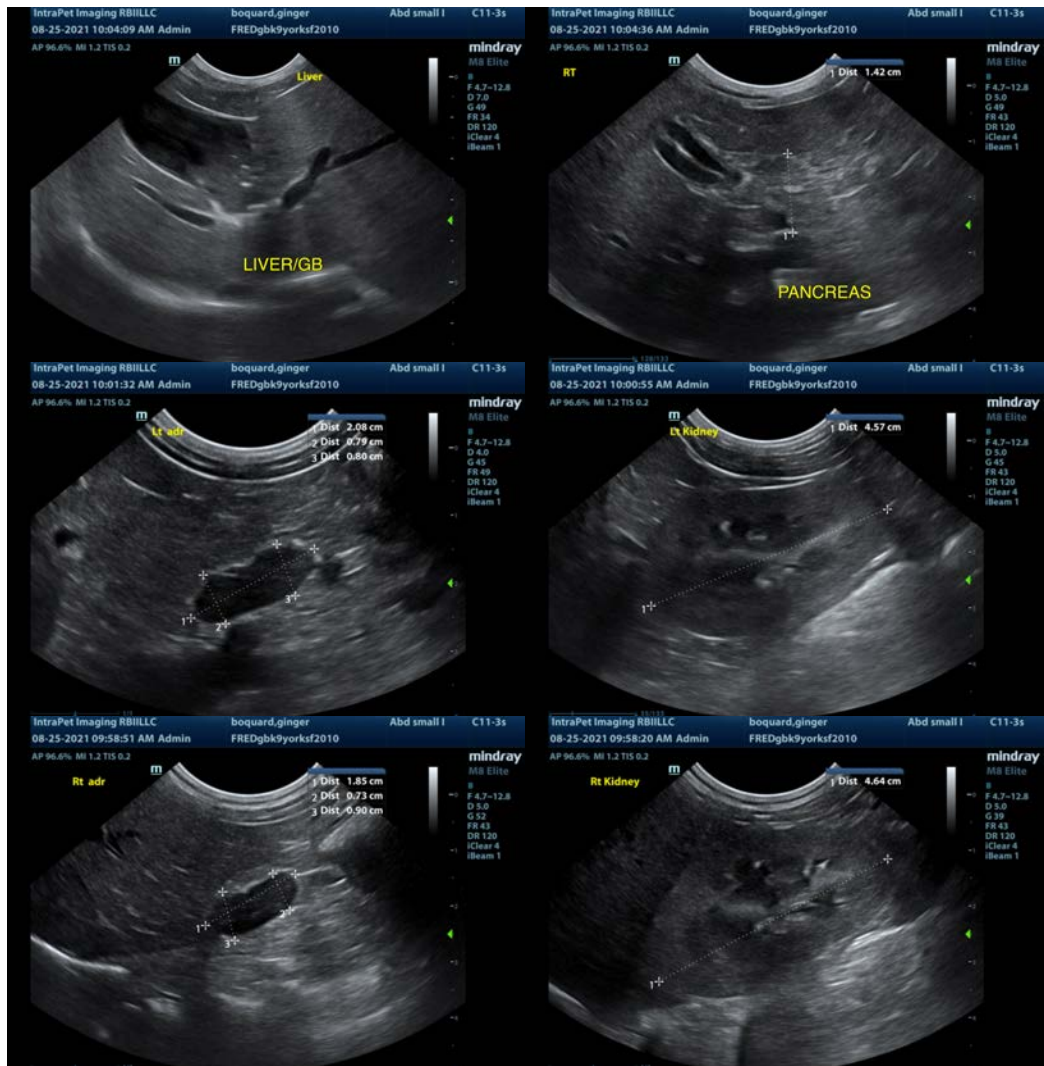
- Bilateral adrenomegaly – The bilateral adrenomegaly could be consistent with bilateral hyperplasia (e.g., secondary to pituitary-dependent hyperadrenocorticism), bilateral infiltrative neoplasia, inflammatory adrenal disease, other. Correlation with clinical findings is recommended.
- Large, heterogeneous liver – The diffuse hepatic changes are non-specific and could be consistent with vacuolar hepatopathy, nodular hyperplasia, inflammatory/immune-mediated disease, fibrosis, extramedullary hematopoiesis, toxic hepatopathy (e.g., copper), infiltrative neoplasia (less likely) or other hepatopathy.
- Prominent, hypoechoic pancreas surrounded by hyperechoic mesentery – The pancreatic changes are most consistent with moderate pancreatitis/pancreatic inflammation. Recommend fPLI testing and continued monitoring for improvement or possible development of a pancreatic abscess. Consider fine needle aspirate if not improving.

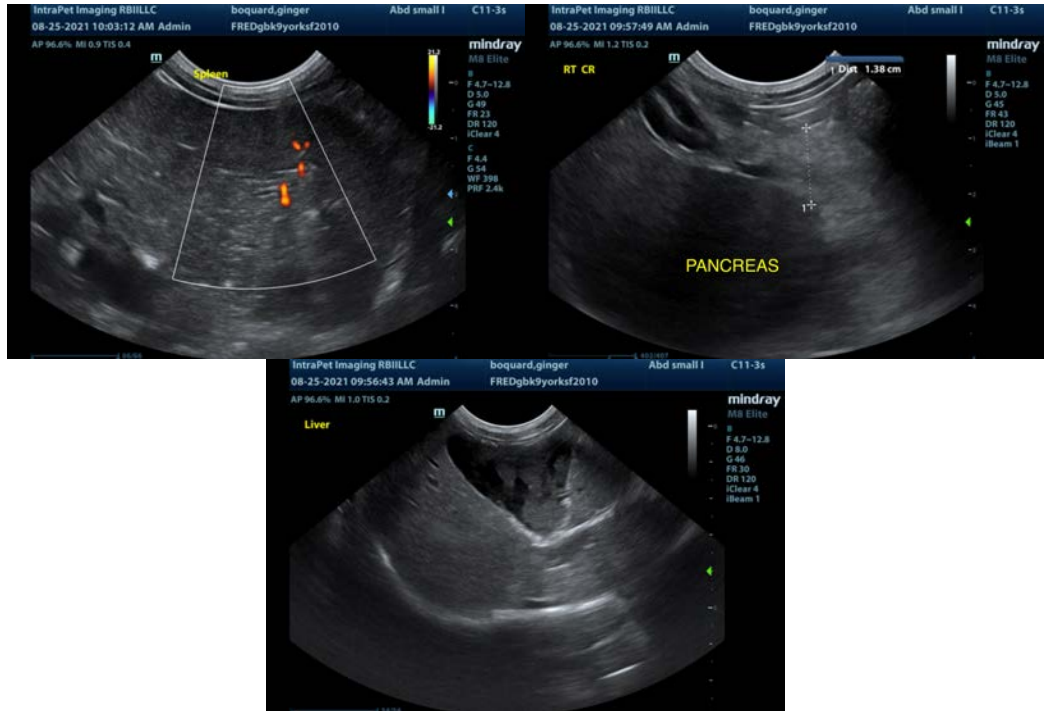
SECONDARY FINDINGS

- Decreased corticomedullary distinction in both kidneys with small cortical cysts – The bilateral renal findings are consistent with age-related change.

INTERPRETATION OF THE FINDINGS & FURTHER RECOMMENDATIONS

As suspected based on the history, the ultrasonographic lesions are most consistent with a diagnosis of Cushing's disease and pancreatitis. If you feel that the pancreatitis is largely subclinical at this point, then I would go ahead and consider adrenal function testing and blood pressure evaluation, as the proteinuria may improve with treatment for Cushing's disease. If pancreatitis is still clinical and active, you could consider giving more time prior to adrenal function testing and additional therapy.





The information and recommendations provided are based on the images presented by the referring veterinarian. No evaluation can be communicated regarding pathology that was not visible in the image/video clips provided.

Thank you for this referral. If the clinical or image interpretation does not parallel your findings or if I can be of any further assistance please contact me.

Kathleen Sennello DVM,MS, Diplomate ACVIM (Small animal Internal Medicine)
kathleen.sennello@sonopath.com