**DATE PRESENTING CLINICAL SIGNS**

8/24/23 Presenting complaint - had cystotomy at another hospital but could not find stones in bladder during Surgery. PE - WNL

**PATIENT**

Rass Creager

Current Medications: None.

Lab Results: urinalysis - RBC. urine culture - no growth. CBC, chemistry - NSF

Radiographs: 5 small bladder stones.

**SPECIES**

Canine

Date of Previous IntraPet Ultrasound: No previous.

Sedation: Not required to complete full diagnostic ultrasound.

Stat Report: Not requested.

Imaging Performed By: Rachel Brillhart, RDMS.

**BREED**

Mini Australian Shepherd

**ULTRASONOGRAPHIC EXAMINATION OF THE ABDOMEN****SEX**

Neutered Male

**Urinary System**

The urinary bladder is moderately distended with anechoic urine. The Bladder wall appears generally of normal thickness. There are some areas with slight mucosal irregularity (possibly previous surgery site?). In the dependent portion of the urinary bladder there is a focal area of hyperechoic shadowing material. This could represent a pile of small stones/mineralized debris, etc. The region of the trigone, ureteral papillae and proximal urethra appear free of any calculi or mass lesions at this time.

**AGE**

6/8/17

The prostate is normal in size (0.76 cm) and shape for this neutered male dog. The parenchyma is homogenous and the external margins are smooth. The prostatic urethra appears normal with no evidence of irregularity, invasion, mass effect or calculi.

**WEIGHT**

37 Pounds

The left kidney has a normal shape and size (4.56 cm). Occasional small cortical mineralizations noted. Overall echogenicity is normal with adequate corticomedullary distinction and a typical 1:3 cortex:medulla ratio. There is no evidence of focal perinephric inflammation or effusion. There is no evidence of pyelectasia,, infarcts or hydroureter. Renal vasculature is normal.

**INTERPRETED BY**

Kathleen Sennello DVM,  
MS, Diplomate ACVIM  
(Small Animal Internal  
Medicine)

The right kidney has a normal shape and size (4.62 cm). Occasional small cortical mineralizations noted. Overall echogenicity is normal with adequate corticomedullary distinction and a typical 1:3 cortex:medulla ratio. There is no evidence of focal perinephric inflammation or effusion. There is no evidence of pyelectasia,, infarcts or hydroureter. Renal vasculature is normal.

**HOSPITAL NAME**

Honeygo AH

**Adrenal Glands**

The left adrenal gland is normal in size measuring 0.72 cm at the caudal pole. It is observed in its normal position cranial to the left renal artery. It is normal in appearance (uniformly hypoechoic) and shape with no evidence of a mass effect.

**REFERRING VET**

Dr. Weichert

The right adrenal gland is normal in size measuring 0.63 cm at the caudal pole. It is observed in its normal position between the cranial aspect of the right kidney and the caudal vena cava. It is normal in appearance (uniformly hypoechoic) and shape with no evidence of a mass effect.

**INVOICE**

44949

**Spleen**

The spleen is subjectively normal in size, echotexture is homogenous, and the splenic capsule is smooth with no irregularities. The blood flow through the hilus and splenic parenchyma appears normal. No focal parenchymal abnormalities are visualized.

### ***Liver***

The liver is subjectively normal in size, and echogenicity with smooth peripheral margins. The parenchyma is homogenous echotexture. The visible portions of the vasculature and biliary tract appear normal. No focal nodules or cystic lesions are observed.

The gallbladder lumen is moderately distended. The wall of the gall bladder is not thickened and has a smooth mucosal surface. Luminal contents are mild and primarily anechoic. The cystic and common bile ducts are normal/not visible.

### ***Gastrointestinal***

The stomach contains minimal luminal contents. It measures at a normal thickness of <0.7cm with some variability due to the presence of rugal folds. The distinction of the gastric wall layers is adequate and there is no impression of reduced peristaltic activity. No masses or focal lesions were observed.

The visualized areas of duodenum, jejunum and ileum have a relatively uniform diameter with minimal fluid distension. Wall thickness is normal. Bowel loops follow a curvilinear path with distinct wall layering maintaining the typical 1:3 muscularis:mucosa layer ratio. The duodenum measured as normal (between 0.3-0.5cm in wall thickness) and the jejunum measured as normal (between 0.2-0.47cm.) Visualized peristalsis appears appropriate. There were no focal lesions consistent with obstruction or a mass effect observed.

The ileocecal junction was visualized and exhibited normal intact wall layering and is subjectively of normal thickness. Sections of colon are visualized with formed fecal material and gas shadowing distally. There is no observed focal or generalized colon wall thickening or loss of layering.

### ***Pancreas***

The pancreas is prominent and mottled compared to the surrounding isoechoic mesentery. There is no evidence of nodules or cystic lesions. There is no evidence of regional mesenteric inflammation or fluid.

### ***Free Abdomen***

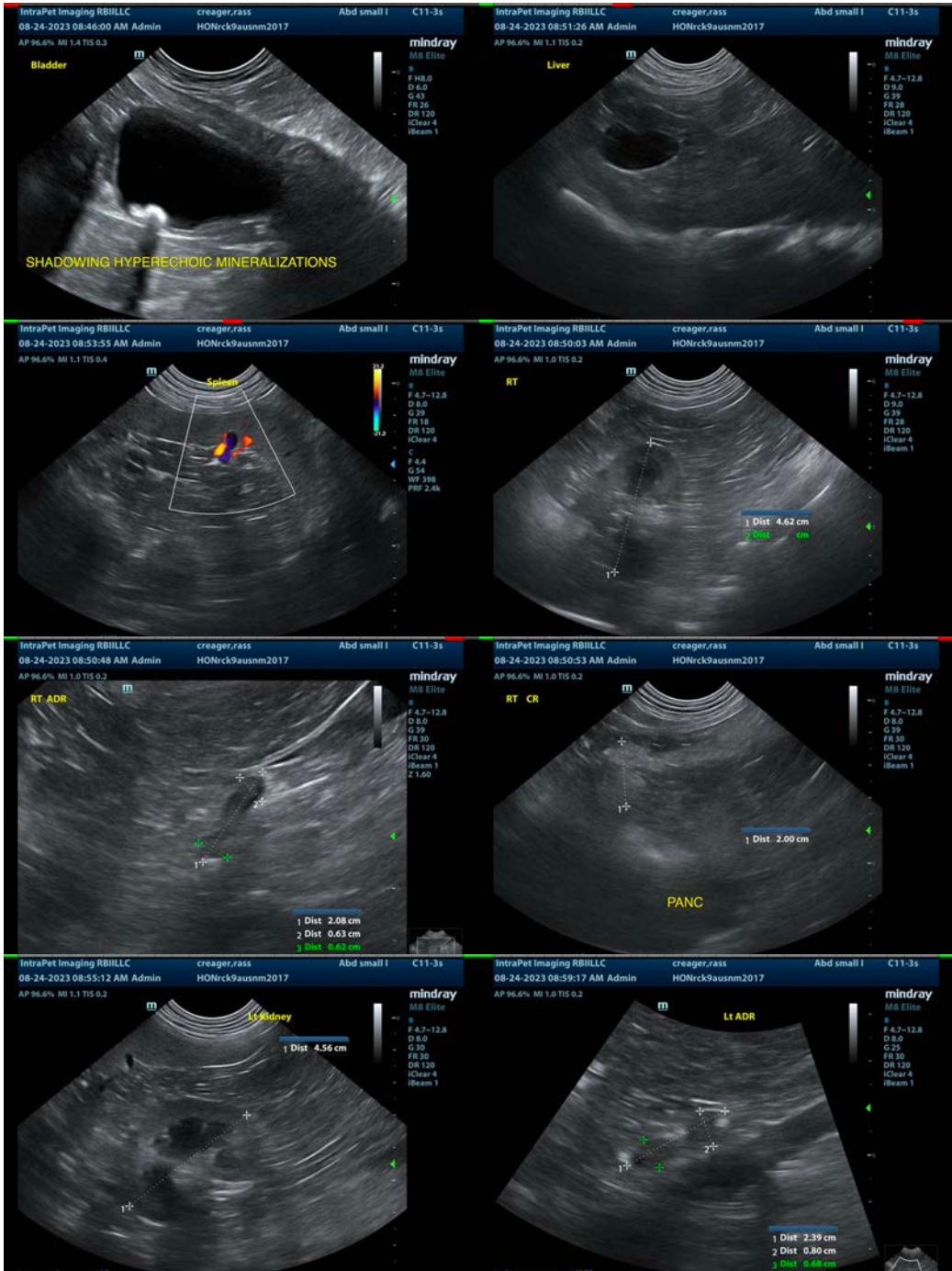
Evaluation of the peritoneal cavity did not reveal any evidence of effusion, or subjective lymphadenomegaly. The Medial iliac nodes appear normal and there was no evidence of a caudal aortic thrombus at the bifurcation. The omentum is of normal uniform echogenicity.

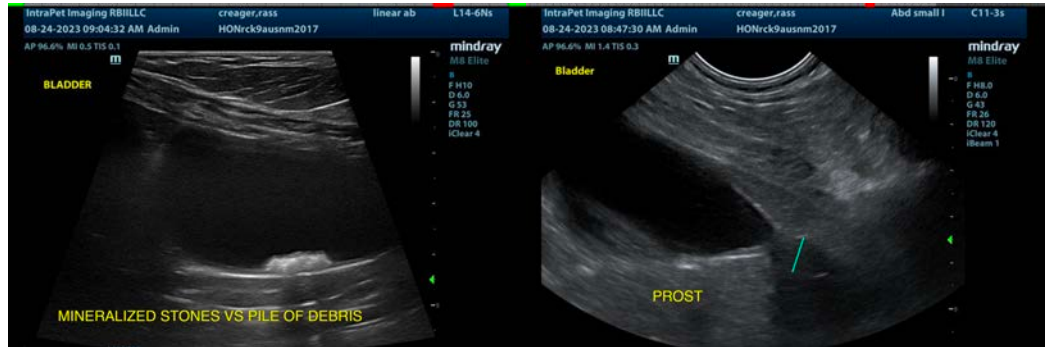
## **ULTRASONOGRAPHIC FINDINGS**

- Shadowing hyperechoic material in the dependent portion of the urinary bladder – Findings are most consistent with a pile of small stones or sandy debris.
- Prominent, mottled pancreas – The pancreatic changes are most consistent with age-related parenchymal remodeling, potentially secondary to a prior inflammatory episode, early fibrosis or chronic pancreatitis.

## **INTERPRETATION OF THE FINDINGS & FURTHER RECOMMENDATIONS**

There is a small pile of mineralized material in the dependent portion of the urinary bladder. This appears somewhat mobile. Typically, radiographs are utilized to differentiate the size and number of calculi present. Recommend urinalysis and culture, looking for evidence of concurrent cystitis.





The information and recommendations provided are based on the images presented by the referring veterinarian/sonographer. No evaluation can be communicated regarding pathology that was not visible in the image/video clips provided.

Thank you for this referral. If the clinical or image interpretation does not parallel your findings or if I can be of any further assistance please contact me.

Kathleen Sennello DVM,MS, Diplomate ACVIM (Small animal Internal Medicine)  
info@sonopath.com