

**PATIENT**

Guppy Sutliff

PRESENTING CLINICAL SIGNS

Constipation, enema given, not eating or drinking well.

SPECIES

Feline

ULTRASONOGRAPHIC EXAMINATION OF THE ABDOMEN**Urinary System**

The urinary bladder is moderately distended with mild primarily suspended echogenic debris present. The Bladder wall, trigone, ureteral papillae and visible urethra (to a depth of 2cm) appear normal with no evidence of wall thickening, mucosal irregularities, masses or calculi. Echogenic debris of this type can be associated with small crystals, cellular debris and proteinaceous debris.

BREED

DSH

SEX

Spayed Female

The left kidney has a normal shape and size (3.76 cm). Overall echogenicity is normal with adequate corticomedullary distinction and a typical 1:3 cortex:medulla ratio. There is no evidence of perinephric inflammation or effusion. There is no evidence of pyelectasia, nephroliths, infarcts or hydroureter. Renal vasculature is normal.

AGE

5 Years

The right kidney has a normal shape and size (3.89 cm). Overall echogenicity is normal with adequate corticomedullary distinction and a typical 1:3 cortex:medulla ratio. There is no evidence of perinephric inflammation or effusion. There is no evidence of pyelectasia, nephroliths, infarcts or hydroureter. Renal vasculature is normal.

WEIGHT

14 Pounds

Adrenal Glands

The left adrenal gland is normal in size measuring 0.29 cm at the caudal pole. It is observed in its normal position cranial to the left renal artery. It is normal in appearance (uniformly hypoechoic) and shape with no evidence of a mass effect.

INTERPRETED BYKathleen Sennello DVM,
MS, Diplomate ACVIM
(Small Animal Internal
Medicine)

The right adrenal gland is normal in size measuring 0.31 cm at the caudal pole. It is observed in its normal position between the cranial aspect of the right kidney and the caudal vena cava. It is normal in appearance (uniformly hypoechoic) and shape with no evidence of a mass effect.

Spleen

The spleen is subjectively normal in size (0.94 cm in width at the level of the hilus), echotexture is homogenous, and the splenic capsule is smooth with no irregularities. The blood flow through the hilus and splenic parenchyma appears normal. No focal parenchymal abnormalities are visualized.

IMAGING PERFORMED BY

Rachel Runnells, RVT

Liver

The liver is subjectively normal in size, and echogenicity with smooth peripheral margins. The parenchyma is homogenous echotexture. The visible portions of the vasculature and biliary tract appear normal. No focal nodules or cystic lesions are observed.

HOSPITAL NAME

SVS Imaging KC

REFERRING VET

Dr. John Doyle

The gallbladder lumen is moderately distended. The wall of the gall bladder is not thickened and has a smooth mucosal surface. Luminal contents are primarily anechoic. The cystic and common bile ducts are normal/not visible.

Gastrointestinal**INVOICE**

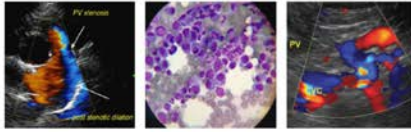
40697

The stomach contains minimal luminal contents. It measures at a normal thickness of <0.36cm with some variability due to the presence of rugal folds. The distinction of the gastric wall layers is adequate and there is no impression of reduced peristaltic activity. No masses or focal lesions were observed.

DATE

8/24/22

The visualized areas of duodenum, jejunum and ileum have a uniform diameter with minimal fluid distension. Wall thickness is normal to slightly increased. Bowel loops follow a typical curvilinear path

**PATIENT**

Guppy Sutliff

with distinct wall layering, but some areas display a prominent muscularis layer which does not display the typical 1:3 muscularis:mucosa layer ratio. Jejunum wall measures 0.25 cm. Visualized peristalsis appears appropriate. There were no focal lesions consistent with obstruction or a mass effect observed.

SPECIES

Feline

The ileocecal junction was visualized and exhibited normal intact wall layering and is subjectively of normal thickness. There is a focal lymphadenopathy and hyperechoic mesentery surrounding the region of the ileocecal junction. Sections of colon are visualized with formed fecal material and gas shadowing distally. There is no observed focal or generalized colon wall thickening or loss of layering.

BREED

DSH

Pancreas

The pancreas is prominent and hypoechoic as compared to the surrounding isoechoic mesentery. There is no evidence of nodules or cystic lesions. There is no evidence of regional mesenteric inflammation or fluid.

SEX

Spayed Female

Free Abdomen

Evaluation of the peritoneal cavity did not reveal any evidence of effusion. There is a mesenteric lymphadenopathy present with a mesenteric lymph node measuring 0.45 cm. Additionally, there are small clusters of prominent mesenteric lymph nodes around the ileocecal junction with lymph nodes measuring 0.31, 0.34, and 0.30 cm. The omentum is hyperechoic around the ileocecal junction.

AGE

5 Years

ULTRASONOGRAPHIC FINDINGS**WEIGHT**

14 Pounds

- Echogenic debris in the urinary bladder – The echogenic debris in the bladder lumen could be consistent with cells, crystals, and/or mucus.
- Hypoechoic, prominent pancreas – The pancreatic changes are most consistent with mild pancreatitis or a recent episode of pancreatic inflammation.
- Prominent muscularis layer to the small intestine – The small intestinal wall changes are most consistent with an inflammatory process (i.e., inflammatory bowel disease) with a low possibility of emerging lymphoma.
- Prominent lymph nodes and mesentery around the ileocecal junction – The prominent abdominal lymph nodes are most consistent with reactive lymphadenitis or lymphoid hyperplasia. Neoplastic infiltration is considered less likely.

INTERPRETED BYKathleen Sennello DVM,
MS, Diplomate ACVIM
(Small Animal Internal
Medicine)**IMAGING PERFORMED BY**

Rachel Runnells, RVT

INTERPRETATION OF THE FINDINGS & FURTHER RECOMMENDATIONS

No focal lesions are visualized involving the gastrointestinal tract. There is mild diffuse prominence of the muscularis layer of the small intestine, and some inflammation and prominent lymph nodes in the region of the ileocecal junction. These changes likely indicate underlying small intestinal disease. Consider such differentials as food allergy/dietary intolerance, GI parasitism, chronic pancreatitis, dysbiosis, IBD, and less likely intestinal neoplasia.

HOSPITAL NAME

SVS Imaging KC

REFERRING VET

Dr. John Doyle

- Recommend a novel protein/hydrolyzed protein prescription diet.
- Consider a GI panel to Texas A&M for a qualitative fPLI, TLI, cobalamin and folate to further evaluate the pancreas and small intestine.
- Recommend treatment for chronic pancreatitis.
- Recommend chronic probiotic therapy.
- If GI signs persist, consider obtaining GI biopsies.

INVOICE

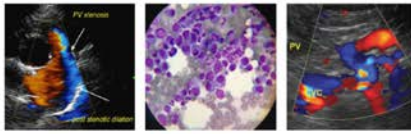
40697

DATE

8/24/22

IMAGING PERFORMED BY

SVS Mobile Imaging KC 816 - 401 - 5010
svsimagingkc@gmail.com



PATIENT

Guppy Sutliff

SPECIES

Feline

BREED

DSH

SEX

Spayed Female

AGE

5 Years

WEIGHT

14 Pounds

INTERPRETED BY

Kathleen Sennello DVM,
MS, Diplomate ACVIM
(Small Animal Internal
Medicine)

**IMAGING
PERFORMED BY**

Rachel Runnels, RVT

HOSPITAL NAME

SVS Imaging KC

REFERRING VET

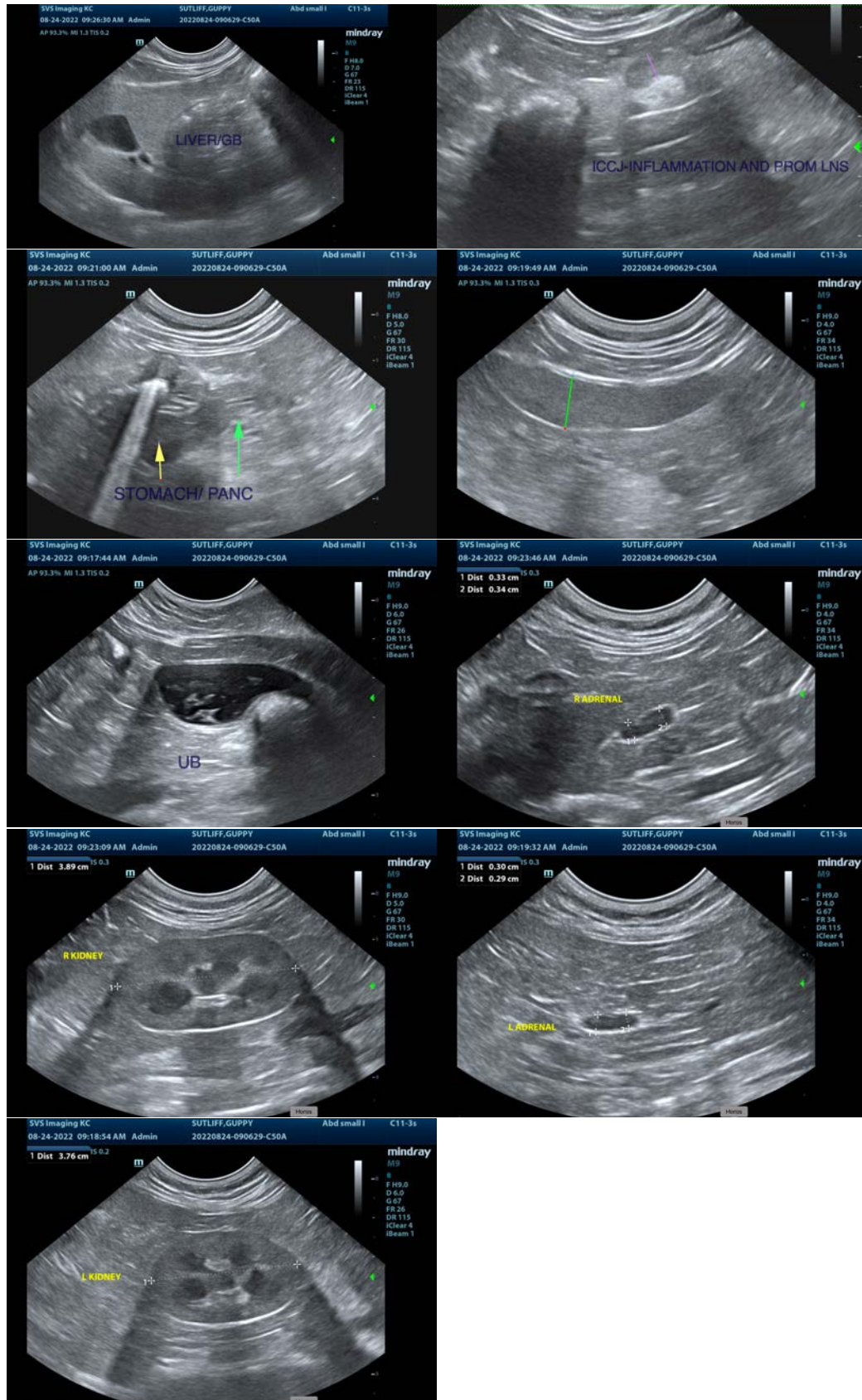
Dr. John Doyle

INVOICE

40697

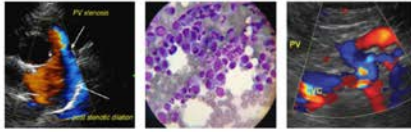
DATE

8/24/22



IMAGING PERFORMED BY

SVS Mobile Imaging KC 816 - 401 - 5010
svsimagingkc@gmail.com



Clinical Sonography & Telectology
EDUCATIONAL TELECONSULTATION SERVICES™
1-800-838-4268 info@sonopath.com SonoPath.com

PATIENT

Guppy Sutliff

SPECIES

Feline

BREED

DSH

SEX

Spayed Female

AGE

5 Years

WEIGHT

14 Pounds

INTERPRETED BY

Kathleen Sennello DVM,
MS, Diplomate ACVIM
(Small Animal Internal
Medicine)

**IMAGING
PERFORMED BY**

Rachel Runnells, RVT

HOSPITAL NAME

SVS Imaging KC

REFERRING VET

Dr. John Doyle

INVOICE

40697

DATE

8/24/22

The information and recommendations provided are based on the images presented by the referring veterinarian/sonographer. No evaluation can be communicated regarding pathology that was not visible in the image/video clips provided.

Thank you for this referral. If the clinical or image interpretation does not parallel your findings or if I can be of any further assistance please contact me.

Kathleen Sennello DVM,MS, Diplomate ACVIM (Small animal Internal Medicine)

kathleen.sennello@sonopath.com