**DATE**

8/24/21

PRESENTING CLINICAL SIGNS

ADR, Painful (Unspecified).

History: Date: 08-23-2021 Notes: Patient has been adr. owner does not know if patient is urinating. Patient has had a decrease appetite. Dr. Willer-- weight loss for the past month- looks thinner; has been wobbling when waking up; occ lethargy; has a cat wheel: owner has put it away- but has continued is a picky eater today- went into a crouch; acting abnormal has been eating and drinking occ coughing/sneeze- over the past 1-2 weeks indoor only.

Current Medications: Gabapentin Tablets 25mg

Lab Results: Attached

Date of Previous IntraPet Ultrasound: No previous

Sedation: not needed

Stat Report: not requested

PATIENT

Vhipir Bell

SPECIES

Feline

BREED

Domestic Shorthair

SEX

Neutered male

AGE

2012

WEIGHT

10.2 lbs

INTERPRETED BY

Kathleen Sennello
DVM, MS, Diplomate
ACVIM (Small Animal
Internal Medicine)

HOSPITAL NAME

Animal Emergency
Hospital

REFERRING VET

Dr. Roper

INVOICE

91464

ULTRASONOGRAPHIC EXAMINATION OF THE ABDOMEN**Urinary System**

The urinary bladder is moderately distended with anechoic urine. The Bladder wall, trigone, ureteral papillae and visible urethra (to a depth of 2cm) appear normal with no evidence of wall thickening, mucosal irregularities, masses or cystic calculi.

The left kidney has a normal shape and size (4.08 cm). Overall echogenicity is normal with adequate corticomedullary distinction and a typical 1:3 cortex:medulla ratio. There is no evidence of perinephric inflammation or effusion. There is no evidence of pyelectasia, nephroliths, infarcts or hydroureter. Renal vasculature is normal.

The right kidney has a normal shape and size (4.11 cm). Overall echogenicity is normal with adequate corticomedullary distinction and a typical 1:3 cortex:medulla ratio. There is no evidence of perinephric inflammation or effusion. There is no evidence of pyelectasia, nephroliths, infarcts or hydroureter. Renal vasculature is normal.

Adrenal Glands

The region of left adrenal (Cranial to left renal artery) is unremarkable but the adrenal is not distinctly visualized. No evidence of a mass effect.

The region of the right adrenal (between right cranial kidney and vena cava) is unremarkable, but the adrenal is not distinctly visualized. No evidence of a mass effect.

Spleen

The spleen is subjectively normal in size, echotexture is homogenous, and the splenic capsule is smooth with no irregularities. The blood flow through the hilus and splenic parenchyma appears normal. No focal parenchymal abnormalities are visualized.

Liver

The liver is subjectively normal in size, and echogenicity with smooth peripheral margins. The parenchyma is heterogenous in echotexture with subtle, indistinct focal mottling. The visible portions of the vasculature and biliary tract appear normal. No focal nodules or cystic lesions are observed. The gallbladder lumen is moderately distended. The wall of the gall bladder is not thickened and has a smooth mucosal surface. Luminal contents are primarily anechoic. The cystic and common bile ducts are normal/not visible.

Gastrointestinal

The stomach contains minimal luminal contents. It measures at a normal thickness of <0.36cm with some variability due to the presence of rugal folds. The distinction of the gastric wall layers is adequate and there is no impression of reduced peristaltic activity. No masses or focal lesions were observed.

The visualized areas of duodenum, jejunum and ileum have a uniform diameter with minimal fluid distension. Wall thickness is normal to slightly increased. Bowel loops follow a typical curvilinear path with distinct wall layering, but some areas display a prominent muscularis layer which does not display the typical 1:3 muscularis:mucosa layer ratio. The jejunum measured 0.32 cm. Visualized peristalsis appears appropriate. There were no focal lesions consistent with obstruction or a mass effect observed.

The ileocecal junction was visualized and exhibited normal intact wall layering and is subjectively of normal thickness. Sections of colon are visualized with formed fecal material and gas shadowing distally. There is no observed focal or generalized colon wall thickening or loss of layering.

Pancreas

The pancreas is large and hypoechoic to surrounding mesentery. There is no evidence of nodules or cystic lesions. There is evidence of regional mesenteric inflammation. Consistent with mild/moderate pancreatitis. The pancreatic duct is prominent at 0.18 cm.

Free Abdomen

Evaluation of the peritoneal cavity did not reveal any evidence of effusion, or subjective lymphadenomegaly. The Medial iliac nodes appear normal and there was no evidence of a caudal aortic thrombus at the bifurcation. The omentum is of normal uniform echogenicity.

ULTRASONOGRAPHIC FINDINGS

PRIMARY FINDINGS:

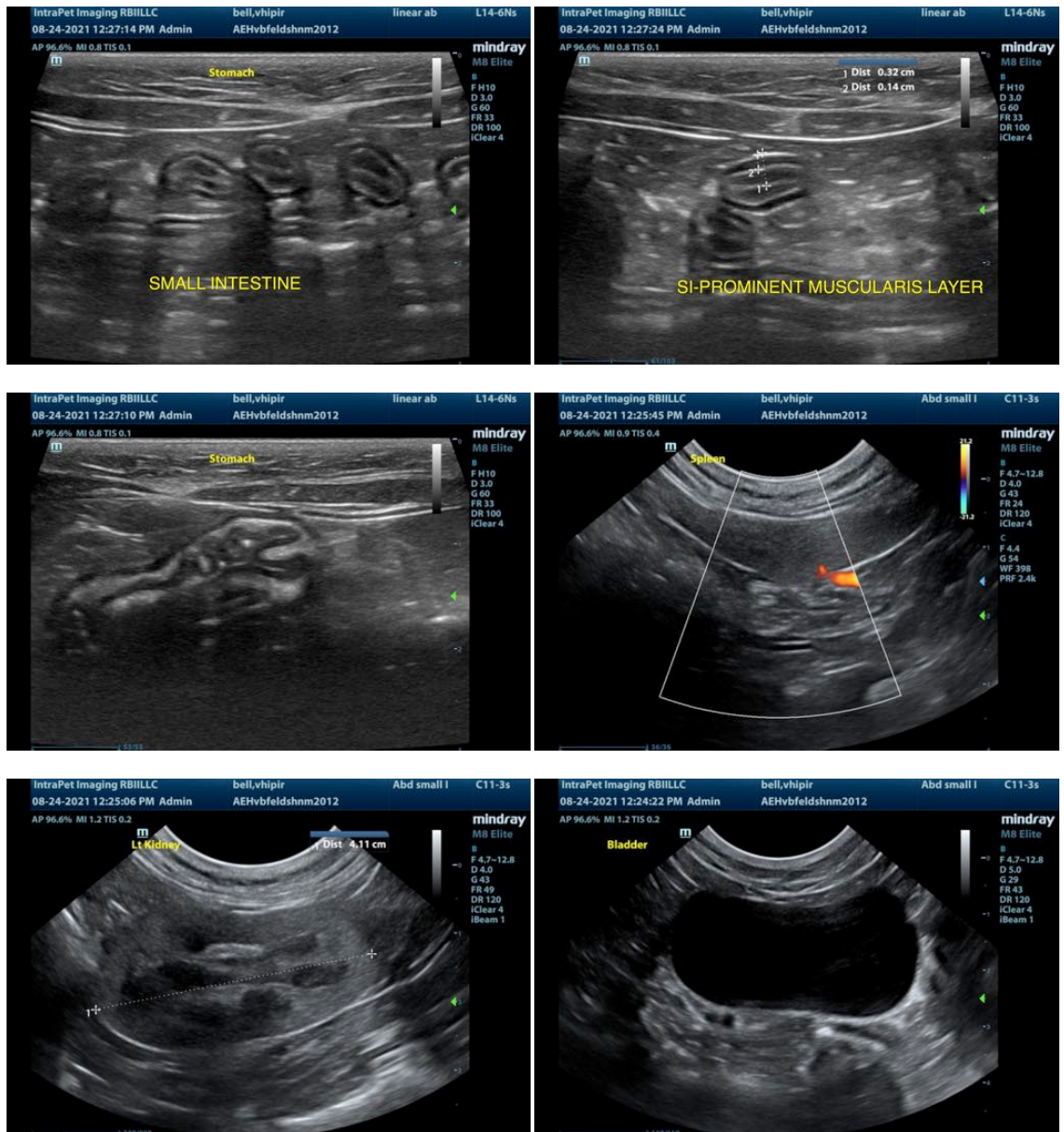
- Prominent, hypoechoic with surrounding, hyperechoic mesentery. The pancreatic changes are most consistent with mild/moderate pancreatitis/pancreatic infiltration. I recommend fPLI testing and continued monitoring for improvement or possible development of a pancreatic abscess. Consider FNA if not improving.
- Subjectively thickened small intestine with prominent muscularis layer. The small intestinal wall changes are most consistent with an inflammatory process (i.e., inflammatory bowel disease) with a low possibility of emerging lymphoma.

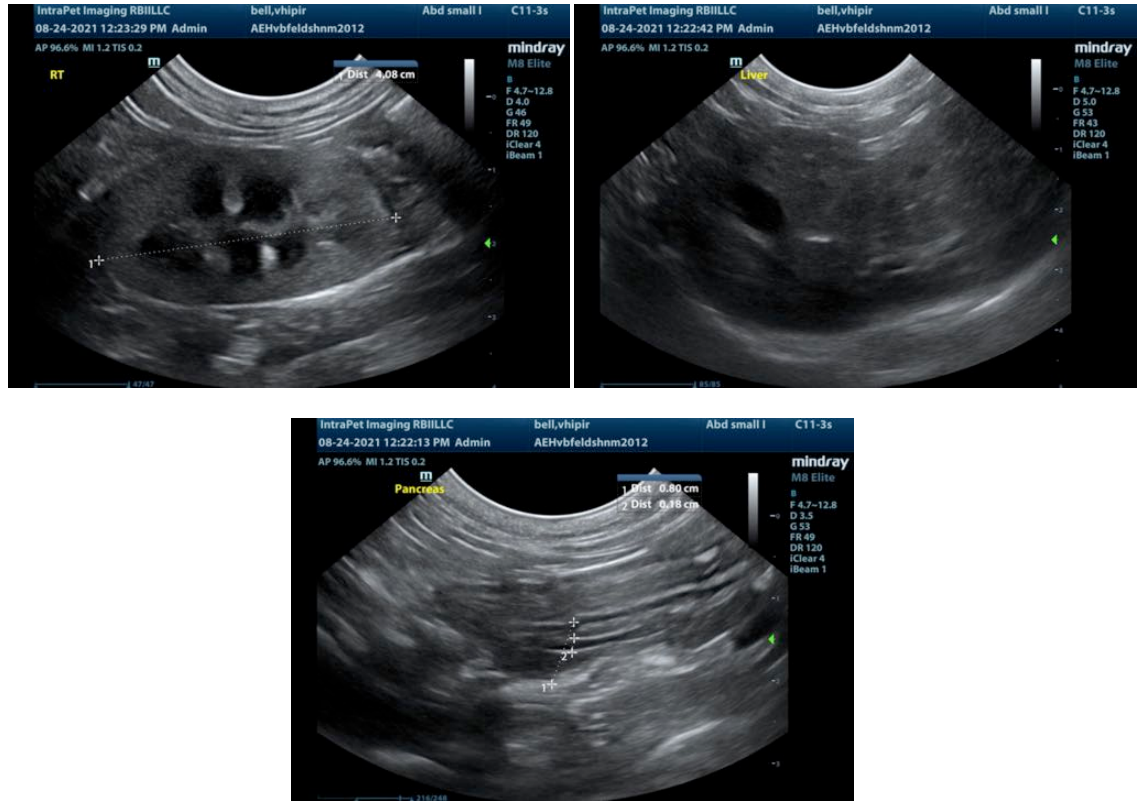
SECONDARY FINDINGS:

- Heterogenous liver. The liver is subjectively normal in size, and echogenicity with smooth peripheral margins. The parenchyma is heterogenous in echotexture with subtle, indistinct focal mottling. The visible portions of the vasculature and biliary tract appear normal. No focal nodules or cystic lesions are observed. In light of normal liver values this may be consistent with age related remodeling.

INTERPRETATION OF THE FINDINGS & FURTHER RECOMMENDATIONS

The pancreas is prominent in this patient and may be a source of abdominal pain. Consider quantitative fPLI to Texas A&M with a gastrointestinal panel, which include B12, folate level to further evaluate for evidence of small intestinal disease. I recommend supportive care for pancreatitis including fluids, pain medications, nausea medications, appetite stimulants, etc. If B12 levels are abnormal and symptoms persist you may need to consider GI biopsies, B12 supplementation, etc.





The information and recommendations provided are based on the images presented by the referring veterinarian. No evaluation can be communicated regarding pathology that was not visible in the image/video clips provided.

Thank you for this referral. If the clinical or image interpretation does not parallel your findings or if I can be of any further assistance please contact me.

Kathleen Sennello DVM,MS, Diplomate ACVIM (Small animal Internal Medicine)
kathleen.sennello@sonopath.com