

**DATE**

8/24/21

PRESENTING CLINICAL SIGNS

Patient seen at AEH (on 8/22) for diarrhea w/ frank blood present. Abdominal radiographs revealed abnormal shape or mass associated with liver or spleen.

Current Medications: Current Medications- Sucralfate tab 1g (1 tab BID), 100mg Gabapentin (1 cap SID).

Patient was on 27.5mg Carprofen BID but it was recommended to discontinue by ER vet.

Lab Results: Elevated live values (ALT = 261, ALKP = 562).

Radiographs: Abdominal radiographs revealed abnormal shape or mass associated with liver or spleen.

Date of Previous IntraPet Ultrasound: No previous

Sedation: not needed

Stat Report: not requested

PATIENT

Bella Schafer

SPECIES

Canine

BREED

Cockapoo

SEX

Spayed Female

AGE

2009

WEIGHT

36 lbs

ULTRASONOGRAPHIC EXAMINATION OF THE ABDOMEN**Urinary System**

The urinary bladder is moderately distended with anechoic urine. The Bladder wall, trigone, ureteral papillae and visible urethra (to a depth of 2cm) appear normal with no evidence of wall thickening, mucosal irregularities, masses or cystic calculi.

The left kidney has a normal shape and size (5.08 cm). Overall echogenicity is slightly hyperechoic with poor corticomedullary distinction and a typical 1:3 cortex:medulla ratio. There is no evidence of perinephric inflammation or effusion. There is no evidence of pyelectasia, nephroliths, infarcts or hydroureter. Renal vasculature is normal.

The right kidney has a normal shape and size (5.1 cm). Overall echogenicity is slightly hyperechoic with poor corticomedullary distinction and a typical 1:3 cortex:medulla ratio. There is no evidence of perinephric inflammation or effusion. There is no evidence of pyelectasia, nephroliths, infarcts or hydroureter. Renal vasculature is normal.

INTERPRETED BY

Kathleen Sennello
DVM, MS, Diplomate
ACVIM (Small Animal
Internal Medicine)

Adrenal Glands

The left adrenal gland is normal in size measuring 0.71 cm at the caudal pole It is observed in its normal position cranial to the left renal artery. It is normal largely normal in appearance, but there is a 0.42 cm indistinct, hyperechoic nodule in the caudal pole, which does not appear to be deforming the silhouette of the gland and is not causing a discrete mass effect.

The right adrenal gland is normal in size measuring 0.63 cm at the caudal pole It is observed in its normal position between the cranial aspect of the right kidney and the caudal vena cava. It is normal in appearance (uniformly hypoechoic) and shape with no evidence of a mass effect.

HOSPITAL NAME

Creswell VC

REFERRING VET

Dr. Cullum

Spleen

The spleen is subjectively normal in size, echotexture is homogenous, and the splenic capsule is smooth with no irregularities. The blood flow through the hilus and splenic parenchyma appears normal. No focal parenchymal abnormalities are visualized.

INVOICE

91462

Liver

The liver is subjectively large in size, and echogenicity with rounded peripheral margins. The parenchyma is heterogenous in echotexture with subtle, indistinct focal mottling. The visible portions of the vasculature and biliary tract appear normal. There are numerous, indistinct, globoid mass effects visualized in the liver. These are not discrete masses, but more subtle mass effects. The one on the left side measured 4.33 x 3.06 cm. The gallbladder lumen is moderately distended. The wall of the gallbladder is not thickened and has a smooth

mucosal surface. There is a moderate amount of non-organized echogenic debris. The cystic and common bile ducts are normal/not visible.

Gastrointestinal

The stomach contains minimal luminal contents. It measures at a normal thickness of <0.7cm with some variability due to the presence of rugal folds. The distinction of the gastric wall layers is adequate and there is no impression of reduced peristaltic activity. No masses or focal lesions were observed.

The visualized areas of duodenum, jejunum and ileum have a uniform diameter with minimal fluid distension. Wall appears subjectively, mildly increased. Bowel loops follow a typical curvilinear path with distinct wall layering. The duodenum measured 0.44 cm and the jejunum is 0.32 cm, 0.33 cm, and 0.3 cm. Visualized peristalsis appears appropriate. There were no focal lesions consistent with obstruction or a mass effect observed

The ileocecal junction was visualized and exhibited normal intact wall layering, but is of increased thickness particularly in the distal colon measuring up to 0.5 cm. Some areas of colon are visualized with non-formed fecal material and gas shadowing distally.

Pancreas

The pancreas is normal and isoechoic to surrounding mesentery. There is no evidence of nodules or cystic lesions. There is no evidence of regional mesenteric inflammation or fluid.

Free Abdomen

Evaluation of the peritoneal cavity did not reveal any evidence of effusion. There is a mild/moderate distal mesenteric lymphadenomegaly in the region of the colon. There is a lymph node that measured 1.17 cm. The omentum is of normal echogenicity.

ULTRASONOGRAPHIC FINDINGS

PRIMARY FINDINGS:

- Large, irregular, heterogenous liver with indistinct mass effects. The diffuse hepatic changes are non-specific and could be consistent with vacuolar hepatopathy, nodular hyperplasia, inflammatory/immune-mediated disease, fibrosis, extramedullary hematopoiesis, toxic hepatopathy (e.g., copper), infiltrative neoplasia (less likely) or other hepatopathy.
- Large volume of gallbladder sludge. In some views this material appears to be organizing and may be consistent with a very early mucocele.
- Distal colonic wall thickening. The findings are most suggestive of acute inflammation/infection. I cannot rule out infiltrative disease.
- Mild, caudal mesenteric lymphadenopathy. The colic lymph node is prominent and enlarged. This is likely reactive/inflammatory. I cannot rule out a neoplastic etiology.

SECONDARY FINDINGS:

- Indistinct, hyperechoic nodule in the left adrenal gland. This may be an incidental finding or could be consistent with an early neoplastic lesion such as a carcinoma, pheochromocytoma, etc. I recommend blood pressure evaluation and continued monitoring.

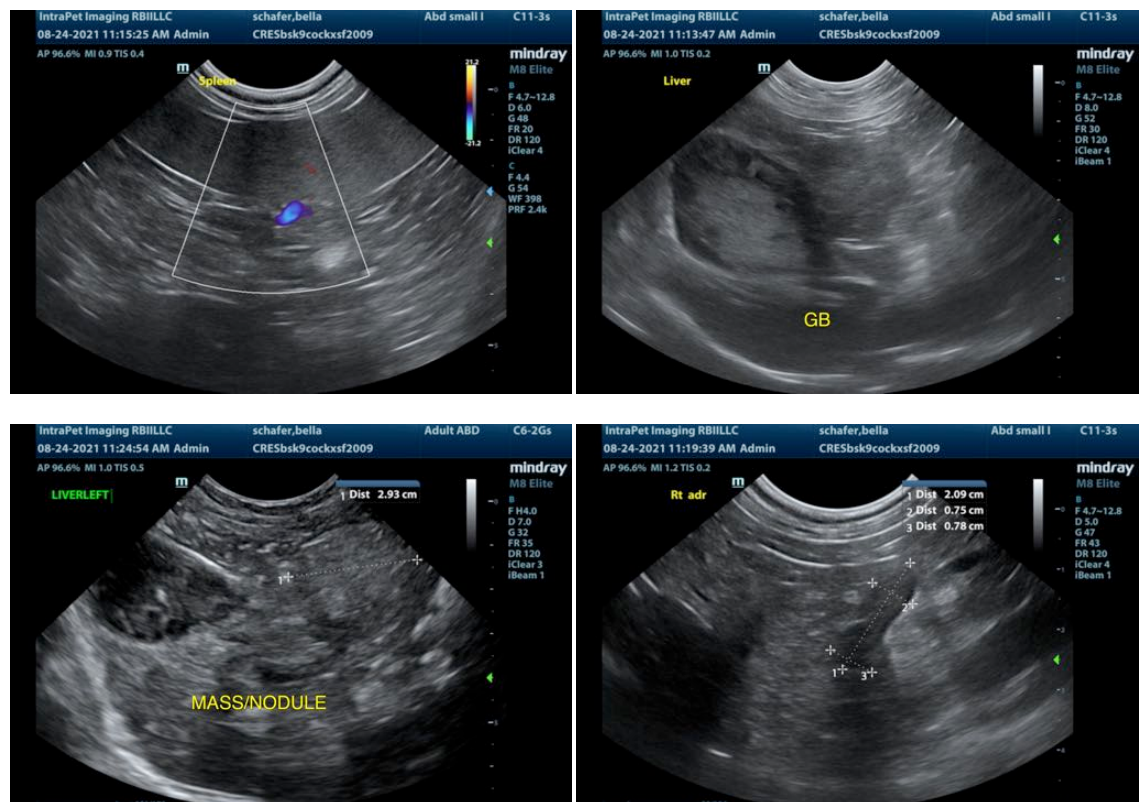
- Decreased corticomedullary kidneys. The bilateral renal findings are consistent with age-related change.
- Subjectively thickened small intestine. The mild small intestinal wall changes may be a normal variant in this patient or could be consistent with an inflammatory process (e.g., inflammatory bowel disease).

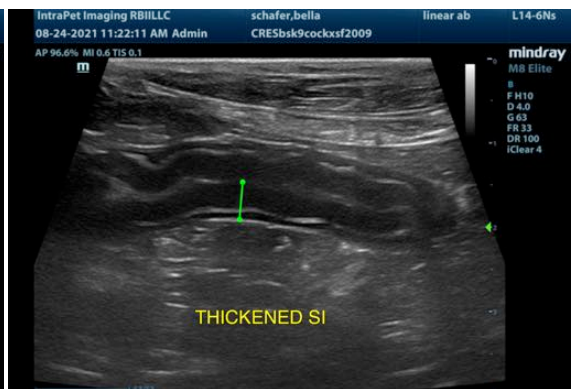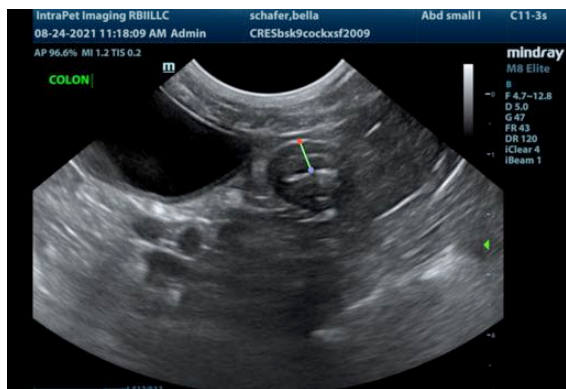
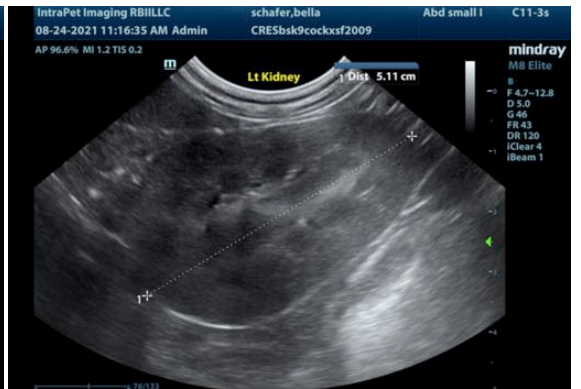
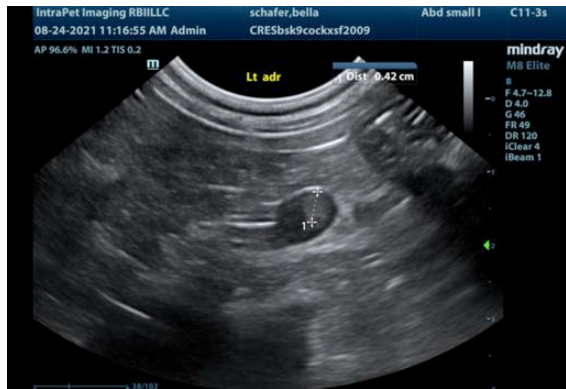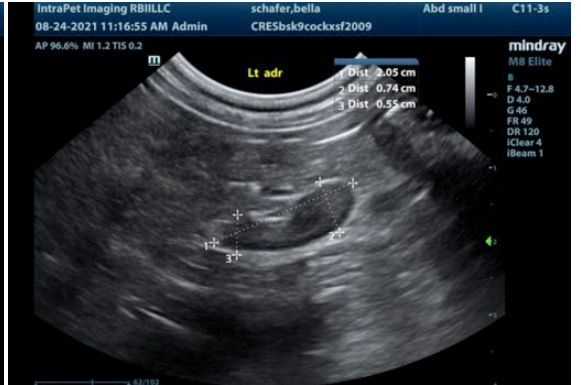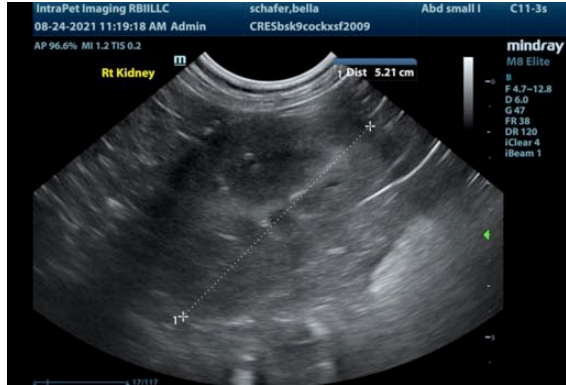INTERPRETATION OF THE FINDINGS & FURTHER RECOMMENDATIONS

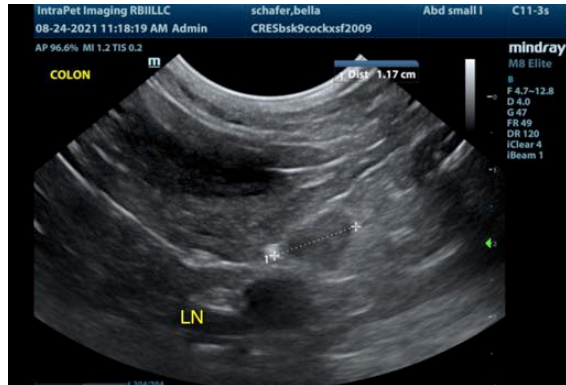The changes observed in the distal bowel are most consistent with severe acute colitis. This can be a somewhat idiopathic condition (HGE) or can be associated with gastrointestinal parasitism, bacterial infectious, fungal infections and less likely a neoplastic change. I recommend continued supportive care for acute hemorrhagic colitis. If there is no response to therapy and diagnostics for infectious causes are negative then consider colonic biopsies. I recommend probiotic therapy.

The liver is large and irregular. These nodules are not discrete, so I am less likely to interpret them as metastatic lesions, etc. Consider a FNA of a liver nodule. Further evaluation would likely involve advanced imaging (CT scan) of the liver for further evaluation and possible surgical planning. I recommended three view thoracic radiographs.

There is a large amount of gallbladder sludge, early, which appears to be starting to organize. Consider starting Ursodiol and continued monitoring. Many of the elevated liver enzymes can be reactive hepatopathy due to the current acute colitis. If the liver values do not normalize then consider a liver function test in the future.







The information and recommendations provided are based on the images presented by the referring veterinarian. No evaluation can be communicated regarding pathology that was not visible in the image/video clips provided.

Thank you for this referral. If the clinical or image interpretation does not parallel your findings or if I can be of any further assistance please contact me.

Kathleen Sennello DVM,MS, Diplomate ACVIM (Small animal Internal Medicine)
kathleen.sennello@sonopath.com