**DATE PRESENTING CLINICAL SIGNS**

8/23/23 Recheck - previously noted enlarged mesenteric LN, pet has not had enough further diagnostics to understand what was really going on, but he improved dramatically on prednisone and doxycycline. Wondering whether the previously noted abnormalities are still present, or whether anything has changed.

**PATIENT**

Zico Michele Current Medications: Prednisone now decreased to 20mg daily, Doxycycline should be done by now, was 30 days at 300mg daily.

**SPECIES**

Canine

Lab Results: GGT and ALP are slightly elevated, otherwise labwork is quite unremarkable now.

Date of Previous IntraPet Ultrasound: 7/19/23. See attached.

Sedation: Not required to complete full diagnostic ultrasound.

Stat Report: Not requested.

**BREED**

Malinois

Imaging Performed By: Stephanie Warga RDCS, RVT.

**ULTRASONOGRAPHIC EXAMINATION OF THE ABDOMEN****SEX**

Neutered Male

**Urinary System**

The urinary bladder is significantly distended with anechoic urine. The Bladder wall, trigone, ureteral papillae and visible urethra (to a depth of 2cm) appear normal with no evidence of wall thickening, mucosal irregularities, masses or cystic calculi.

**AGE**

12/10/14

The prostate is normal in size (2.04 cm in height in the sagittal view) and shape for this neutered male dog. The parenchyma is slightly heterogeneous and the external margins are smooth. The prostatic urethra appears normal with no evidence of irregularity, invasion, mass effect or calculi.

**WEIGHT**

70 Pounds

The left kidney has a normal shape and size (7.34 cm). Overall echogenicity is normal with adequate corticomedullary distinction and a typical 1:3 cortex:medulla ratio. There is no evidence of focal perinephric inflammation or effusion. There is no evidence of pyelectasia, nephroliths, infarcts or hydroureter. Renal vasculature is normal.

**INTERPRETED BY**

Kathleen Sennello DVM,  
MS, Diplomate ACVIM  
(Small Animal Internal  
Medicine)

The right kidney has a normal shape and size (6.94 cm). Overall echogenicity is normal with adequate corticomedullary distinction and a typical 1:3 cortex:medulla ratio. There is no evidence of focal perinephric inflammation or effusion. There is no evidence of pyelectasia, nephroliths, infarcts or hydroureter. Renal vasculature is normal.

**HOSPITAL NAME**

Airpark AH

**Adrenal Glands**

The left adrenal gland is normal in size measuring 0.52 cm at the caudal pole. It is observed in its normal position cranial to the left renal artery. It is normal in appearance (uniformly hypoechoic) and shape with no evidence of a mass effect.

**REFERRING VET**

Dr. Kable

The right adrenal gland is normal in size measuring 0.51 cm at the caudal pole. It is observed in its normal position between the cranial aspect of the right kidney and the caudal vena cava. It is normal in appearance (uniformly hypoechoic) and shape with no evidence of a mass effect.

**INVOICE**

44890

**Spleen**

The spleen is subjectively normal in size, echotexture is homogenous, and the splenic capsule is smooth with no irregularities. The blood flow through the hilus and splenic parenchyma appears normal. No focal parenchymal abnormalities are visualized.

### ***Liver***

The liver is subjectively normal in size with smooth peripheral margins. The parenchyma is hyperechoic and homogenous in echotexture. The visible portions of the vasculature and biliary tract appear normal. No focal nodules or cystic lesions are observed.

The gallbladder lumen is moderately distended. The wall of the gall bladder is not thickened and has a smooth mucosal surface. Luminal contents are mild and primarily anechoic. The cystic and common bile ducts are normal/not visible.

### ***Gastrointestinal***

The stomach contains mild fluid and moderate gas. It measures at a normal thickness of <0.7cm with some variability due to the presence of rugal folds. The distinction of the gastric wall layers is adequate and there is no impression of reduced peristaltic activity. No masses or focal lesions were observed.

The visualized areas of duodenum, jejunum and ileum have a relatively uniform diameter with minimal fluid distension. Wall thickness is normal. Bowel loops follow a curvilinear path with distinct wall layering maintaining the typical 1:3 muscularis:mucosa layer ratio. Duodenum wall measures 0.32 cm. Jejunum wall measures 0.28 cm. Visualized peristalsis appears appropriate. There were no focal lesions consistent with obstruction or a mass effect observed.

Sections of colon are visualized with formed fecal material and gas shadowing distally. There is no observed focal or generalized colon wall thickening or loss of layering.

### ***Pancreas***

The area of the pancreas is normal and isoechoic to surrounding mesentery. There is no evidence of nodules or cystic lesions. There is no evidence of regional mesenteric inflammation or fluid.

### ***Free Abdomen***

Evaluation of the peritoneal cavity did not reveal any evidence of effusion. There is a small cluster of hypoechoic lymph nodes in the mid abdomen. One measures 0.90 cm x 1.95 cm. Another measures 0.89 cm in diameter. The omentum is generally of normal echogenicity.

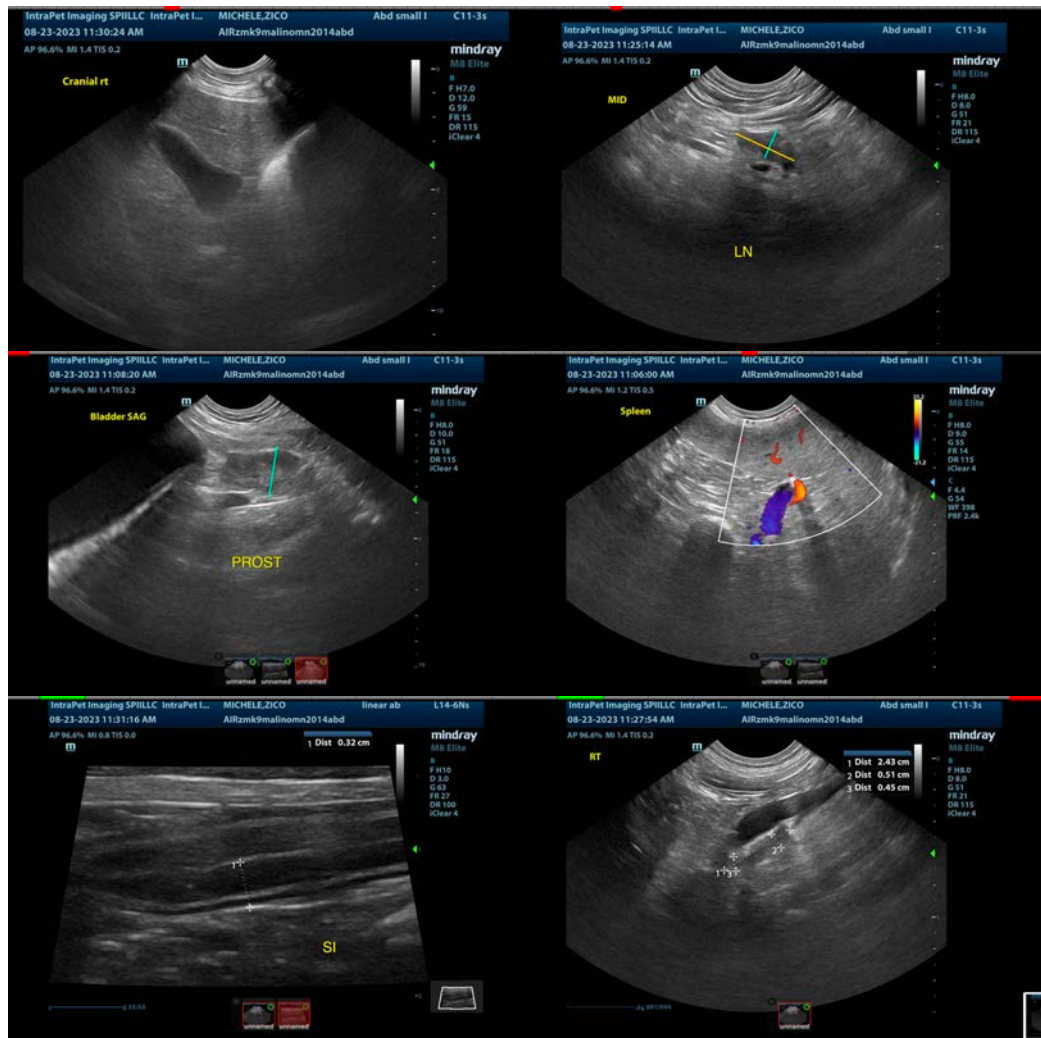
## **ULTRASONOGRAPHIC FINDINGS**

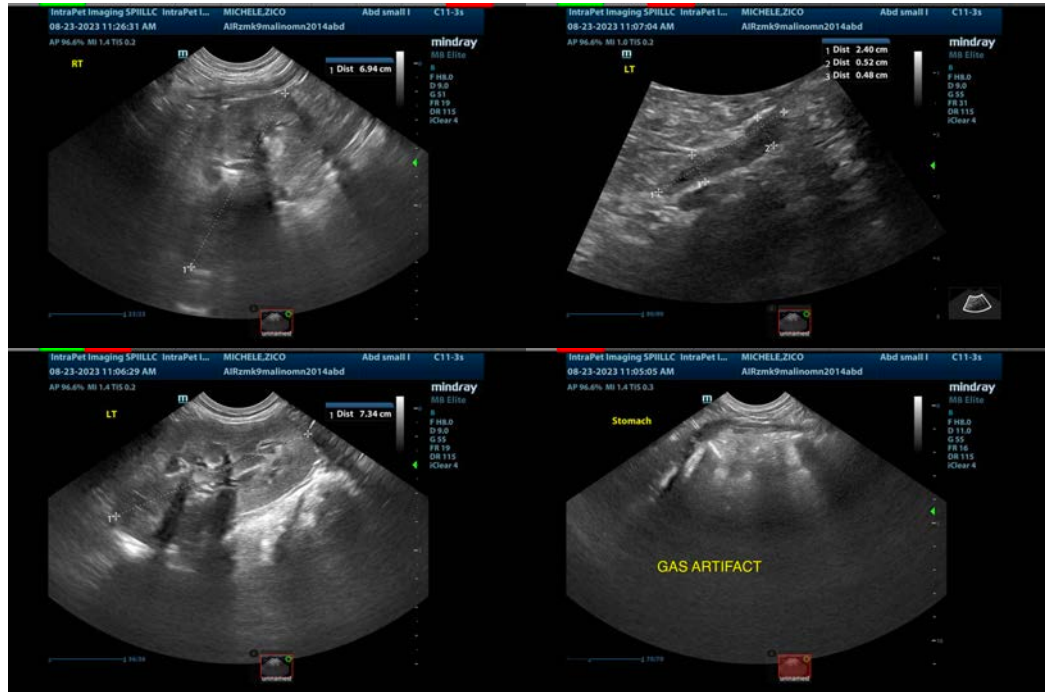
- Hyperechoic liver – The diffuse hepatic changes are non-specific and can be seen with vacuolar hepatopathy, reactive change, nodular hyperplasia or, less likely, inflammatory/immune-mediated disease, infiltrative neoplasia, or other hepatopathy. This could be secondary to Prednisone therapy.
- Mild/moderate fluid/gas in the stomach – Air artifact hinders full evaluation of the stomach and parts of the cranial abdomen.
- Hypoechoic, prominent mesenteric lymph nodes – The prominent abdominal lymph nodes are most consistent with reactive lymphadenitis or lymphoid hyperplasia. Neoplastic infiltration is considered less likely.

## **INTERPRETATION OF THE FINDINGS & FURTHER RECOMMENDATIONS**

The changes observed on today's scan are relatively mild as compared to the previous scan 7/2023. The free fluid has resolved, and the spleen appears much more normal. Additionally, the large mass effect in the mid abdomen is now most consistent with a small prominent lymph node. I'm concerned that this is underlying

round cell neoplasia and there is a temporary remission secondary to Prednisone therapy, but this can only be determined based on cytologic evaluation or recurrence of symptoms and cytological evaluation. At this time, options would include continued Prednisone therapy at an anti-inflammatory dose (approximately 1 mg/kg per day) or tapering off the Prednisone with close continued monitoring of the peripheral lymph nodes +/- the abdominal lymph nodes, and if symptoms recur or the lymph nodes enlarge, then recommend sampling. Inflammatory or autoimmune disease would also be possible but seem less likely in this scenario.





The information and recommendations provided are based on the images presented by the referring veterinarian/sonographer. No evaluation can be communicated regarding pathology that was not visible in the image/video clips provided.

Thank you for this referral. If the clinical or image interpretation does not parallel your findings or if I can be of any further assistance please contact me.

Kathleen Sennello DVM,MS, Diplomate ACVIM (Small animal Internal Medicine)  
info@sonopath.com