

PATIENT

Tadhg MacLaren

SPECIES

Canine

BREED

Irish Water Spaniel

SEX

Neutered Male

AGE

10 Years

WEIGHT

29.9 kg

INTERPRETED BY

Kathleen Sennello DVM,
MS, Diplomate ACVIM
(Small Animal Internal
Medicine)

**IMAGING
PERFORMED BY**

Dr. Nigel Gumley

HOSPITAL NAME

Cedarview AH

REFERRING VET

Dr. Nigel Gumley

INVOICE

44876

DATE

8/23/23

PRESENTING CLINICAL SIGNS

Reduced appetite/picky eater recently. Recent vomiting and appears to be more PU/PD
Abnormal PE/Chem/CBC/UA Results: CBC, chemistries normal, T4 low normal (14) UA normal

ULTRASONOGRAPHIC EXAMINATION OF THE ABDOMEN

Urinary System

The urinary bladder is moderately distended with anechoic urine. The Bladder wall, trigone, ureteral papillae and visible urethra (to a depth of 2cm) appear normal with no evidence of wall thickening, mucosal irregularities, masses or cystic calculi. Bladder wall measures 0.40 cm.

The prostate is borderline large at 2.18 cm. = The parenchyma is homogenous and the external margins are smooth. The prostatic urethra appears normal with no evidence of irregularity, invasion, mass effect or calculi.

The left kidney has a normal shape and size (6.15 cm). Overall echogenicity is normal with adequate corticomedullary distinction and a typical 1:3 cortex:medulla ratio. There is no evidence of focal perinephric inflammation or effusion. There is no evidence of pyelectasia, nephroliths, infarcts or hydroureter. Renal vasculature is normal.

The right kidney has a normal shape and size (6.53 cm). Overall echogenicity is normal with adequate corticomedullary distinction and a typical 1:3 cortex:medulla ratio. There is no evidence of focal perinephric inflammation or effusion. There is no evidence of pyelectasia, nephroliths, infarcts or hydroureter. Renal vasculature is normal.

Adrenal Glands

The left adrenal gland is normal in size measuring 0.48 cm at the caudal pole. It is observed in its normal position cranial to the left renal artery. It is normal in appearance (uniformly hypoechoic) and shape with no evidence of a mass effect.

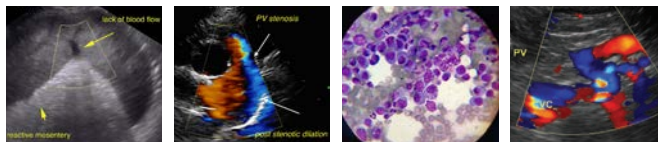
The right adrenal gland is normal in size measuring 0.63 cm at the caudal pole. It is observed in its normal position between the cranial aspect of the right kidney and the caudal vena cava. It is normal in appearance (uniformly hypoechoic) and shape with no evidence of a mass effect.

Spleen

The spleen is borderline large. The spleen echotexture is heterogenous and mottled, the splenic capsule is smooth with no irregularities. The blood flow through the hilus and splenic parenchyma appears normal. There is a hypoechoic nodule visualized towards the caudal aspect of the spleen measuring 0.37 cm x 0.66 cm. Additionally, there is a hyperechoic, slightly cystic nodule visualized in the cranial aspect of the spleen measuring 1.75 cm x 1.68 cm.

Liver

The liver is subjectively normal in size, and echogenicity with smooth peripheral margins. The parenchyma is heterogenous in echotexture with subtle, indistinct focal mottling. The visible portions of the vasculature and biliary tract appear normal. No focal nodules or cystic lesions are observed.



PATIENT

Tadhg MacLaren

The gallbladder lumen is moderately distended. The wall of the gall bladder is not thickened and has a smooth mucosal surface. Luminal contents are mild and primarily anechoic. The cystic and common bile ducts are normal/not visible.

SPECIES

Canine

Gastrointestinal

The stomach contains minimal luminal contents. It measures at a normal thickness of <0.7cm with some variability due to the presence of rugal folds. The distinction of the gastric wall layers is adequate and there is no impression of reduced peristaltic activity. No masses or focal lesions were observed.

BREED

Irish Water Spaniel

The visualized areas of duodenum, jejunum and ileum have a relatively uniform diameter with minimal fluid distension. Wall thickness is normal. Bowel loops follow a curvilinear path with distinct wall layering maintaining the typical 1:3 muscularis:mucosa layer ratio. Duodenum wall measures 0.44 cm. Jejunum wall measures 0.33 cm. Visualized peristalsis appears appropriate. There were no focal lesions consistent with obstruction or a mass effect observed.

SEX

Neutered Male

AGE

10 Years

The ileocecal junction was visualized and exhibited normal intact wall layering and is subjectively of normal thickness. Sections of colon are visualized with formed fecal material and gas shadowing distally. There is no observed focal or generalized colon wall thickening or loss of layering.

WEIGHT

29.9 kg

Pancreas

The pancreas is normal and isoechoic to surrounding mesentery. There is no evidence of nodules or cystic lesions. There is no evidence of regional mesenteric inflammation or fluid.

INTERPRETED BY

Kathleen Sennello DVM,
MS, Diplomate ACVIM
(Small Animal Internal
Medicine)

Free Abdomen

Evaluation of the peritoneal cavity did not reveal any evidence of effusion, or subjective lymphadenomegaly. The Medial iliac nodes appear normal and there was no evidence of a caudal aortic thrombus at the bifurcation. The omentum is of normal uniform echogenicity.

IMAGING PERFORMED BY

Dr. Nigel Gumley

ULTRASONOGRAPHIC FINDINGS

- Borderline large prostate – The appearance of the prostate is relatively normal, but it is large for a dog neutered prior to puberty. If this patient was neutered after puberty this could be within normal limits. Correlate with the history. If prostatic disease is a concern, then consider a fine needle aspirate of the prostate.
- Hypoechoic and hyperechoic nodules in the spleen – Differentials include lymphoid hyperplasia, extramedullary hematopoiesis, infiltrative neoplasia, inflammation, other. Cytology or histopathology would be necessary to get a definitive diagnosis.
- Heterogeneous liver – The diffuse hepatic changes are non-specific and could be consistent with vacuolar hepatopathy, nodular hyperplasia, inflammatory/immune-mediated disease, fibrosis, extramedullary hematopoiesis, toxic hepatopathy (e.g., copper), infiltrative neoplasia (less likely) or other hepatopathy.

HOSPITAL NAME

Cedarview AH

REFERRING VET

Dr. Nigel Gumley

INVOICE

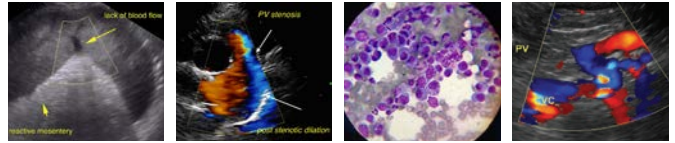
44876

DATE

8/23/23

INTERPRETATION OF THE FINDINGS & FURTHER RECOMMENDATIONS

The spleen appears borderline large and somewhat mottled with a small hypoechoic lesion with a slightly larger hyperechoic lesion. This lesion comes into contact with the liver. While it is strongly suspected that this lesion is of splenic origin, hepatic involvement cannot be definitively ruled out. If this



PATIENT

Tadhg MacLaren

SPECIES

Canine

BREED

Irish Water Spaniel

SEX

Neutered Male

AGE

10 Years

WEIGHT

29.9 kg

INTERPRETED BY

Kathleen Sennello DVM,
MS, Diplomate ACVIM
(Small Animal Internal
Medicine)

**IMAGING
PERFORMED BY**

Dr. Nigel Gumley

HOSPITAL NAME

Cedarview AH

REFERRING VET

Dr. Nigel Gumley

INVOICE

44876

DATE

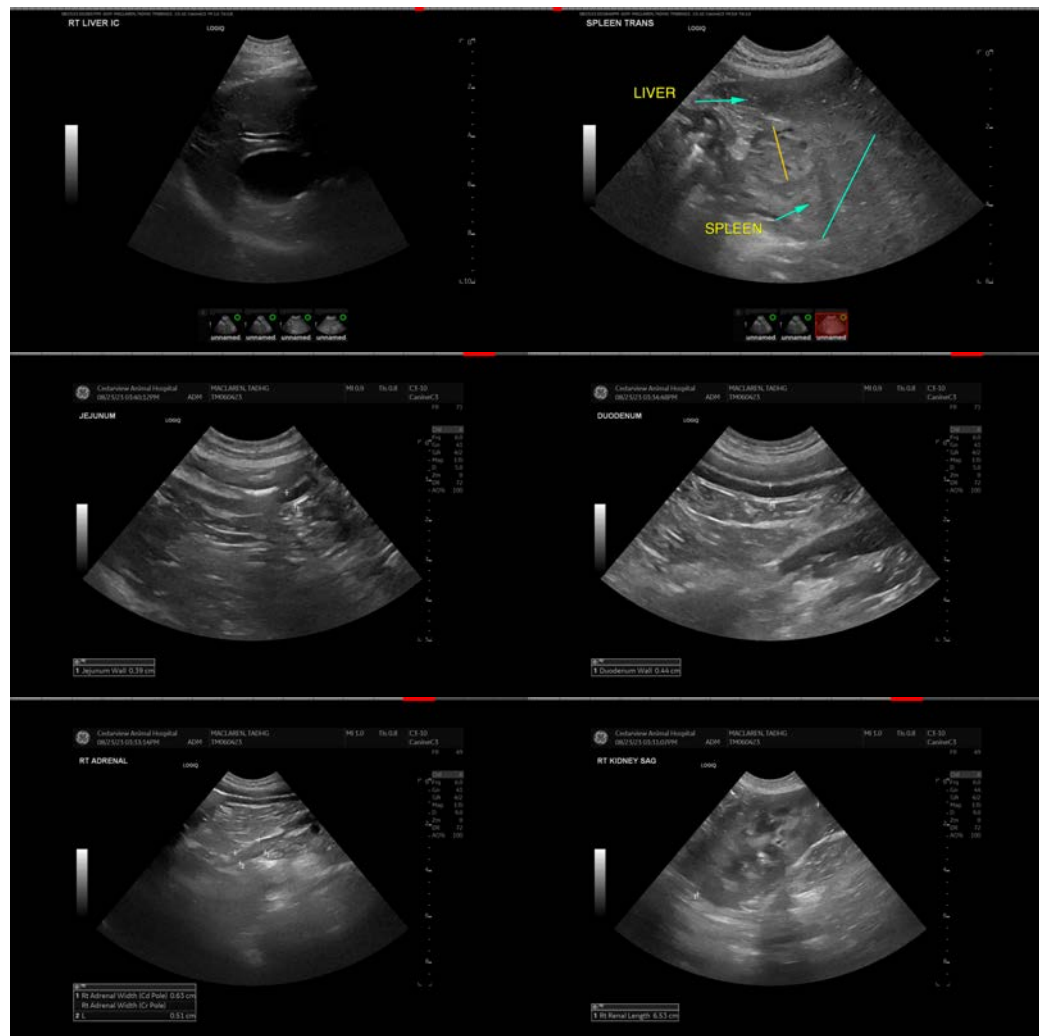
8/23/23

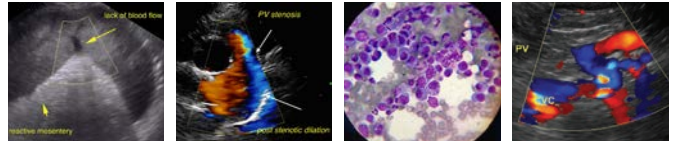
is a concern, a contrast CT scan could be considered to confirm the origin of this nodule. Additionally, you could consider a fine needle aspirate. It is uncertain if the splenic changes are associated with the symptoms described, but no other obvious lesions are visualized to attribute to the decrease in appetite, vomiting, etc. Options moving forward would include a fine needle aspirate of the splenic lesions or a splenectomy for both diagnostic and therapeutic purposes.

You'd have to consider the possibility of concurrent gastrointestinal disease as a source for the vomiting reported. You could consider a GI panel to Texas A&M for a qualitative PLI, TLI, cobalamin and folate to further evaluate for this. If there is concern for concurrent gastrointestinal disease, then biopsies of the GI tract should be considered.

The prostate is somewhat prominent for a neutered male dog. Correlate these findings with the age of neutering. If the patient was neutered prior to puberty, this could be abnormal, and a fine needle aspirate may be warranted.

Recommend three view thoracic radiographs to evaluate for possible concurrent thoracic disease/involvement.





PATIENT

Tadhg MacLaren

SPECIES

Canine

BREED

Irish Water Spaniel

SEX

Neutered Male

AGE

10 Years

WEIGHT

29.9 kg

INTERPRETED BY

Kathleen Sennello DVM,
MS, Diplomate ACVIM
(Small Animal Internal
Medicine)

**IMAGING
PERFORMED BY**

Dr. Nigel Gumley

HOSPITAL NAME

Cedarview AH

REFERRING VET

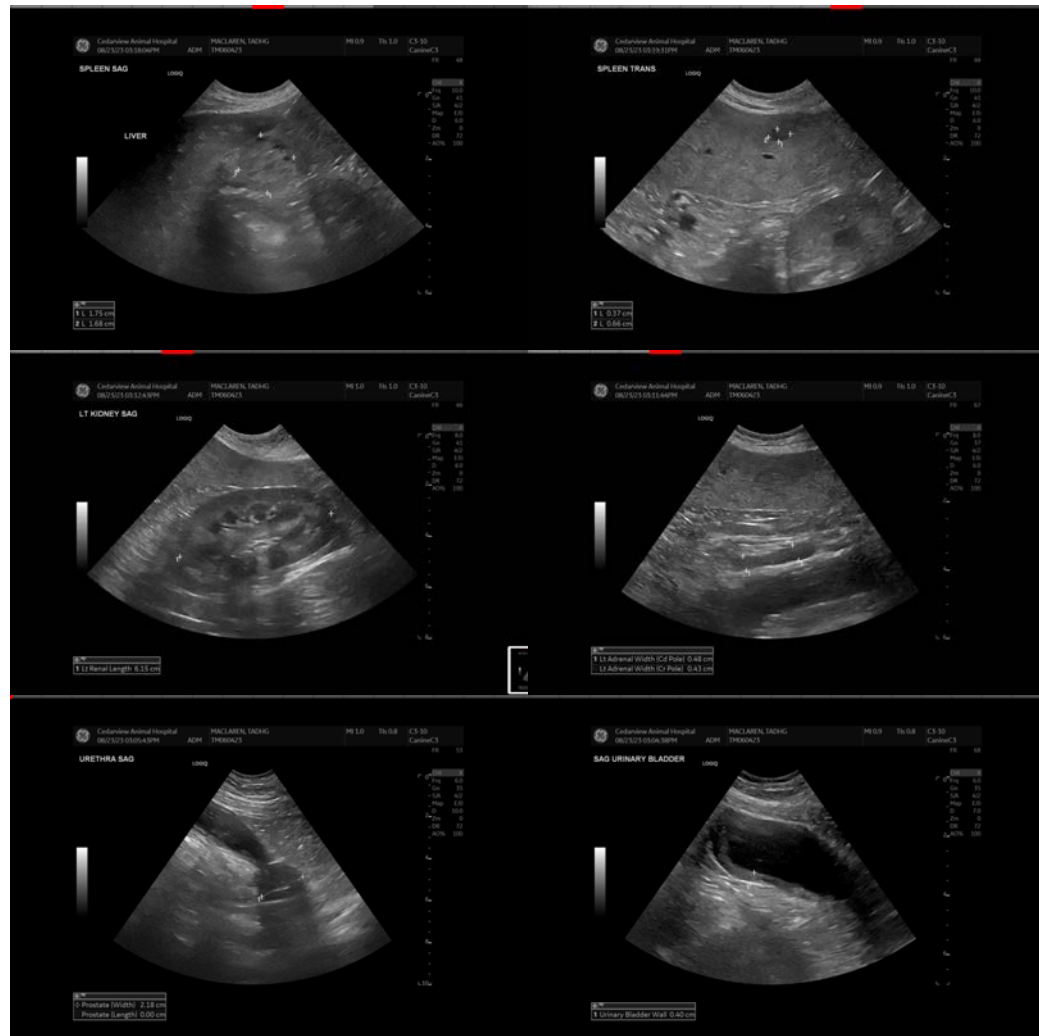
Dr. Nigel Gumley

INVOICE

44876

DATE

8/23/23



The information and recommendations provided are based on the images presented by the referring veterinarian/sonographer. No evaluation can be communicated regarding pathology that was not visible in the image/video clips provided.

Thank you for this referral. If the clinical or image interpretation does not parallel your findings or if I can be of any further assistance please contact me.

Kathleen Sennello DVM,MS, Diplomate ACVIM (Small animal Internal Medicine)

info@sonopath.com