

**PATIENT PRESENTING CLINICAL SIGNS**

**PATIENT**  
Niska Jacobson  
Severe bloody diarrhea and vomiting while on holidays. Stools improving now. Collapsed on the weekend. Diabetic and hypothyroid Currents meds- Humulin N and thyro tabs

**SPECIES**

Canine

Abnormal PE/Chem/CBC/UA Results: Underweight slightly, diffusely dull and sparse haircoat, worse on trunk

**BREED**

Husky

**ULTRASONOGRAPHIC EXAMINATION OF THE ABDOMEN**

**Urinary System**

**SEX**

Spayed Female

The urinary bladder is moderately distended with severely echogenic urine. The Bladder wall is diffusely thickened and irregular, measuring approximately 0.50 cm in thickness with no focal lesions. Findings are most consistent with diffuse cystitis, although an underlying neoplastic process cannot be definitively ruled out.

**AGE**

8

The left kidney has a normal shape and size (6.78 cm). Overall echogenicity is normal with adequate corticomedullary distinction and a typical 1:3 cortex:medulla ratio. There is no evidence of focal perinephric inflammation or effusion. There is no evidence of pyelectasia, nephroliths, infarcts or hydroureter. Renal vasculature is normal.

**WEIGHT**

24 kg

The right kidney has a normal shape and size (7.42 cm). Overall echogenicity is normal with adequate corticomedullary distinction and a typical 1:3 cortex:medulla ratio. There is no evidence of focal perinephric inflammation or effusion. There is no evidence of pyelectasia, nephroliths, infarcts or hydroureter. Renal vasculature is normal.

**INTERPRETED BY**

Kathleen Sennello DVM,  
MS, Diplomate ACVIM  
(Small Animal Internal  
Medicine)

**Adrenal Glands**

**IMAGING**

**PERFORMED BY**

Dr. Hayley Biederbeck

The left adrenal gland is normal in size measuring 0.51 cm at the caudal pole. It is observed in its normal position cranial to the left renal artery. It is normal in appearance (uniformly hypoechoic) and shape with no evidence of a mass effect.

The right adrenal gland is normal in size measuring 0.70 cm at the caudal pole. It is observed in its normal position between the cranial aspect of the right kidney and the caudal vena cava. It is normal in appearance (uniformly hypoechoic) and shape with no evidence of a mass effect.

**HOSPITAL NAME**

Lomsnes Vet Hospital

**Spleen**

The spleen is subjectively normal in size, echotexture is homogenous, and the splenic capsule is smooth with no irregularities. The blood flow through the hilus and splenic parenchyma appears normal. No focal parenchymal abnormalities are visualized.

**REFERRING VET**

Dr. Hayley Biederbeck

**Liver**

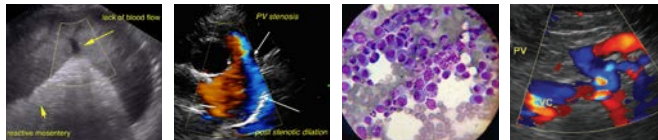
**INVOICE**

44874

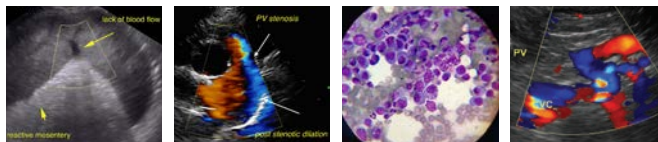
The liver is large in size and irregular. The parenchyma is heterogenous in echotexture with subtle, indistinct focal mottling. The visible portions of the vasculature and biliary tract appear normal. The parenchyma of the liver is diffusely nodular with isoechoic, variably sized nodules, generally measuring approximately 1-2 cm, causing irregular, nodular margins.

**DATE**

8/23/23



<b>PATIENT</b>	The gallbladder lumen is moderately distended. The wall of the gall bladder is not thickened and has a smooth mucosal surface. Luminal contents are mild and primarily anechoic. The cystic and common bile ducts are normal/not visible.
Niska Jacobson	
<b>SPECIES</b>	<b><i>Gastrointestinal</i></b>
Canine	The stomach contains a large amount of ingesta. It measures at a normal thickness of 0.57 cm with some variability due to the presence of rugal folds. The distinction of the gastric wall layers is adequate and there is no impression of reduced peristaltic activity. The irregular nature of the intraluminal ingesta makes it difficult to evaluate the gastric wall and differentiate ingesta from abnormal tissue.
<b>BREED</b>	
Husky	The visualized areas of duodenum, jejunum and ileum have a relatively uniform diameter with minimal fluid distension. Wall thickness is normal. Bowel loops follow a curvilinear path with distinct wall layering maintaining the typical 1:3 muscularis:mucosa layer ratio. Duodenum wall measures 0.40 cm. Jejunum wall measures 0.40 cm. Visualized peristalsis appears appropriate. There were no focal lesions consistent with obstruction or a mass effect observed.
<b>SEX</b>	
Spayed Female	
<b>AGE</b>	
8	The ileocecal junction was visualized and exhibited normal intact wall layering and is subjectively of normal thickness. Sections of colon are visualized with formed fecal material and gas shadowing distally. There is no observed focal or generalized colon wall thickening or loss of layering.
<b>WEIGHT</b>	<b><i>Pancreas</i></b>
24 kg	The area of the pancreas is normal and isoechoic to surrounding mesentery. There is no evidence of nodules or cystic lesions. There is no evidence of regional mesenteric inflammation or fluid.
<b>INTERPRETED BY</b>	<b><i>Free Abdomen</i></b>
Kathleen Sennello DVM, MS, Diplomate ACVIM (Small Animal Internal Medicine)	Evaluation of the peritoneal cavity did not reveal any evidence of effusion. There is a diffuse mild mesenteric lymphadenopathy present with mesenteric lymph nodes measuring 0.57 and 0.53 cm. The omentum is generally of normal echogenicity.
<b>IMAGING PERFORMED BY</b>	<b>ULTRASONOGRAPHIC FINDINGS</b>
Dr. Hayley Biederbeck	<ul style="list-style-type: none"> <li>• Diffusely thickened, irregular urinary bladder wall with echogenic urine – Findings are most consistent with cystitis. Recommend urinalysis and culture.</li> <li>• Large, irregular, diffusely nodular, heterogeneous liver – The diffuse hepatic changes are non-specific and could be consistent with vacuolar hepatopathy, nodular hyperplasia, inflammatory/immune-mediated disease, fibrosis, extramedullary hematopoiesis, toxic hepatopathy (e.g., copper), infiltrative neoplasia (less likely) or other hepatopathy. The appearance of the diffuse nodules could be consistent with a benign process (severe regenerative nodules, etc.) or underlying neoplasia.</li> <li>• Ingested dilated stomach with questionable wall thickening – Consider reevaluation, fasted if possible, or with a very small breakfast. Wall layering appears intact. Consider possible gastritis(?).</li> <li>• Prominent mesenteric lymph nodes – The prominent abdominal lymph nodes are most consistent with reactive lymphadenitis or lymphoid hyperplasia. Neoplastic infiltration is considered less likely.</li> </ul>
<b>HOSPITAL NAME</b>	
Lomsnes Vet Hospital	
<b>REFERRING VET</b>	
Dr. Hayley Biederbeck	
<b>INVOICE</b>	
44874	
<b>DATE</b>	
8/23/23	



## PATIENT

Niska Jacobson

## SPECIES

Canine

## BREED

Husky

## SEX

Spayed Female

## AGE

8

## WEIGHT

24 kg

## INTERPRETED BY

Kathleen Sennello DVM,  
MS, Diplomate ACVIM  
(Small Animal Internal  
Medicine)

## IMAGING PERFORMED BY

Dr. Hayley Biederbeck

## HOSPITAL NAME

Lomsnes Vet Hospital

## REFERRING VET

Dr. Hayley Biederbeck

## INVOICE

44874

## DATE

8/23/23

## INTERPRETATION OF THE FINDINGS & FURTHER RECOMMENDATIONS

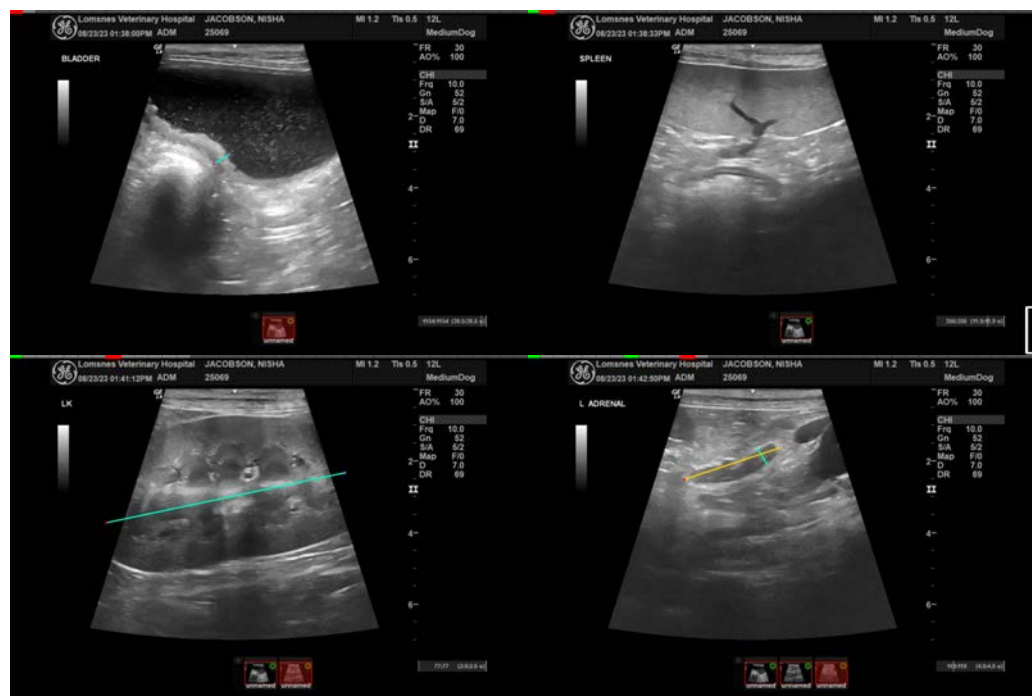
The urinary bladder wall is diffusely thickened, and the intraluminal urine has a very large amount of echogenic debris present. Recommend a urinalysis and culture, as bacterial cystitis is suspected.

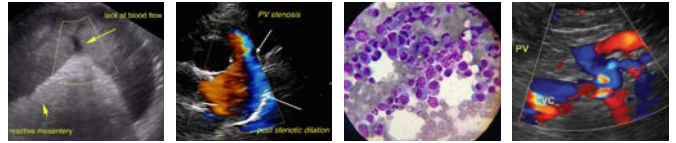
The liver is severely nodular with irregular nodular margins. The margins appear fairly homogeneous and isoechoic. The appearance is almost consistent with a cirrhotic liver, but it is large. Primary differential would be severe nodular regeneration, although underlying neoplasia cannot be ruled out. Consider a fine needle aspirate and correlate with current lab work.

The stomach appears unusual. I suspect there is irregular textured ingesta within the lumen, making it difficult to interpret the appearance of the gastric wall and difficult to determine what is soft tissue versus ingesta. Consider reevaluation with an empty stomach, or if this is not possible in a diabetic patient, maybe a small breakfast of smooth gruel, etc. If the gastric wall appears persistently thickened, this could be consistent with severe gastritis, infiltrative neoplasia, etc., and an upper GI endoscopy could be considered to further evaluate.

A definitive cause for the acute vomiting and diarrhea is not identified, although there are many causes for acute hemorrhagic gastroenteritis that cannot be diagnosed by ultrasound alone. Consider empirical supportive care. If symptoms are persistent, consider repeat imaging +/- additional diagnostics such as upper and lower GI endoscopy, a GI panel to Texas A&M for a qualitative PLI, TLI, cobalamin and folate, and further evaluation of the liver.

Recommend three view thoracic radiographs to evaluate for possible concurrent thoracic disease/involvement.





**PATIENT**

Niska Jacobson

**SPECIES**

Canine

**BREED**

Husky

**SEX**

Spayed Female

**AGE**

8

**WEIGHT**

24 kg

**INTERPRETED BY**

Kathleen Sennello DVM,  
MS, Diplomate ACVIM  
(Small Animal Internal  
Medicine)

**IMAGING  
PERFORMED BY**

Dr. Hayley Biederbeck

**HOSPITAL NAME**

Lomsnes Vet Hospital

**REFERRING VET**

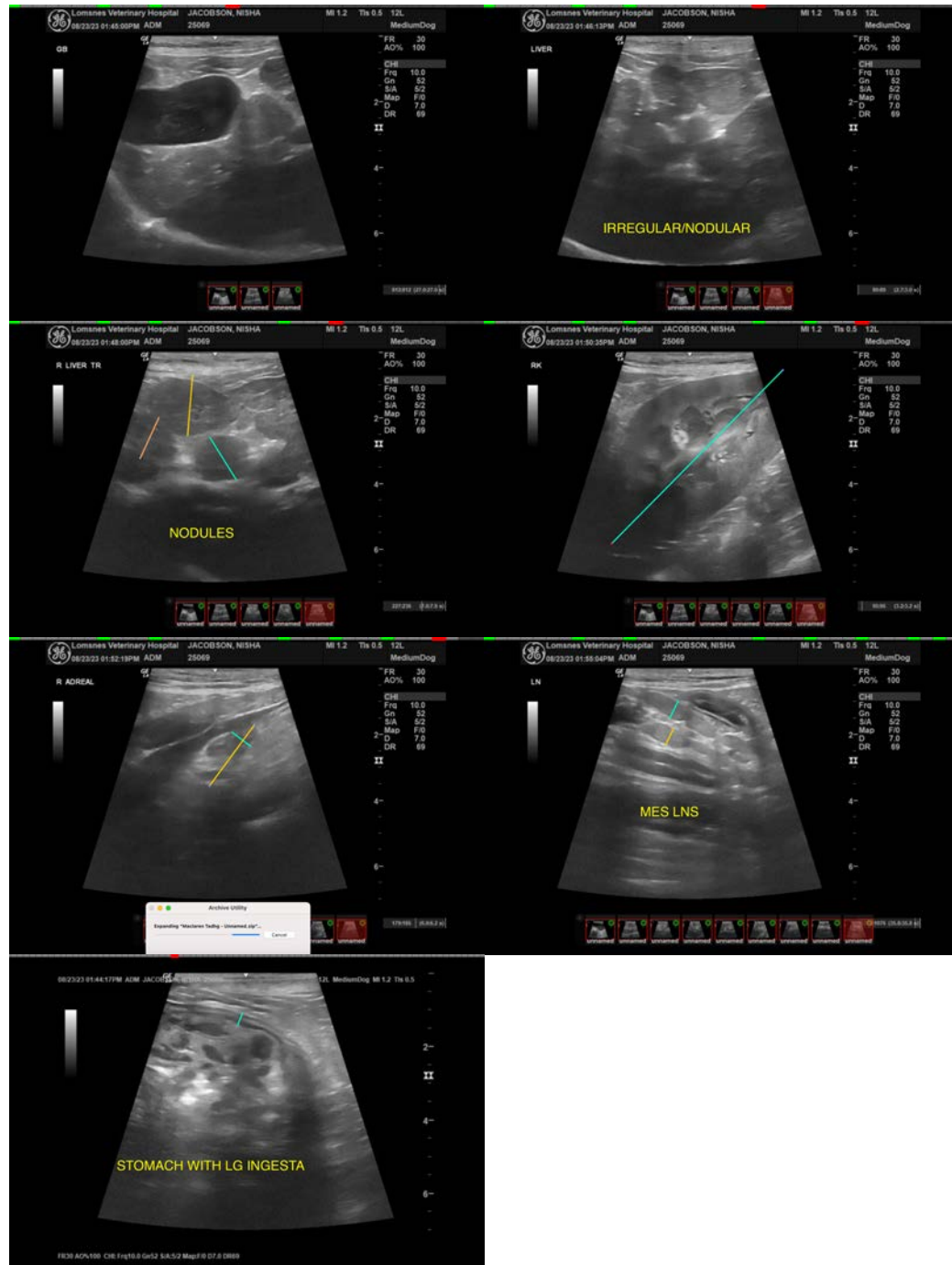
Dr. Hayley Biederbeck

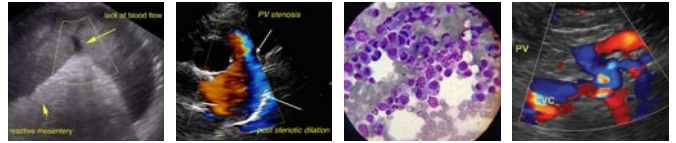
**INVOICE**

44874

**DATE**

8/23/23





**PATIENT**

Niska Jacobson

The information and recommendations provided are based on the images presented by the referring veterinarian/sonographer. No evaluation can be communicated regarding pathology that was not visible in the image/video clips provided.

**SPECIES**

Canine

Thank you for this referral. If the clinical or image interpretation does not parallel your findings or if I can be of any further assistance please contact me.

**BREED**

Husky

Kathleen Sennello DVM,MS, Diplomate ACVIM (Small animal Internal Medicine)

**SEX**

Spayed Female

info@sonopath.com

**AGE**

8

**WEIGHT**

24 kg

**INTERPRETED BY**

Kathleen Sennello DVM,  
MS, Diplomate ACVIM  
(Small Animal Internal  
Medicine)

**IMAGING  
PERFORMED BY**

Dr. Hayley Biederbeck

**HOSPITAL NAME**

Lomsnes Vet Hospital

**REFERRING VET**

Dr. Hayley Biederbeck

**INVOICE**

44874

**DATE**

8/23/23