



PATIENT

Monty Bowen

SPECIES

Canine

BREED

Husky X

SEX

Neutered Male

AGE

9 Years

WEIGHT

80 Pounds

INTERPRETED BY

Kathleen Sennello DVM,
MS, Diplomate ACVIM
(Small Animal Internal
Medicine)

**IMAGING
PERFORMED BY**

A Murphy, CVT

HOSPITAL NAME

Wauwatosa VC

REFERRING VET

Dr. Ericka Haynes

INVOICE

40659

DATE

8/23/22

PRESENTING CLINICAL SIGNS

Approximately 2-3 week history of finicky appetite. Patient will eventually eat his entire meal but needs to be coaxed. CBC, chem, cPL -all WNL. Patient treated for suspected respiratory infection in July 2022. Appetite change occurred while receiving antibiotics (doxycycline) Screening for GI disease

ULTRASONOGRAPHIC EXAMINATION OF THE ABDOMEN

Urinary System

The urinary bladder is moderately distended with anechoic urine. The Bladder wall, trigone, ureteral papillae and visible urethra (to a depth of 2cm) appear normal with no evidence of wall thickening, mucosal irregularities, masses or cystic calculi.

The visualized areas of prostate and surrounding tissue appear normal. Unfortunately, the prostate is not fully visualized likely due to its intrapelvic location. Correlate with rectal exam findings.

The left kidney has a normal shape and size (6.63 cm). Overall echogenicity is normal with adequate corticomedullary distinction and a typical 1:3 cortex:medulla ratio. There is no evidence of perinephric inflammation or effusion. There is no evidence of pyelectasia, nephroliths, infarcts or hydroureter. Renal vasculature is normal.

The right kidney has a normal shape and size (6.8 cm). Overall echogenicity is normal with adequate corticomedullary distinction and a typical 1:3 cortex:medulla ratio. There is no evidence of perinephric inflammation or effusion. There is no evidence of pyelectasia, nephroliths, infarcts or hydroureter. Renal vasculature is normal.

Adrenal Glands

The left adrenal gland is normal in size measuring 0.69 cm at the caudal pole. It is observed in its normal position cranial to the left renal artery. It is normal in appearance (uniformly hypoechoic) and shape with no evidence of a mass effect.

The region of the right adrenal (between right cranial kidney and vena cava) is unremarkable, but the adrenal is not distinctly visualized. No evidence of a mass effect.

Spleen

The spleen is subjectively normal in size, echotexture is homogenous, and the splenic capsule is smooth with no irregularities. The blood flow through the hilus and splenic parenchyma appears normal. No focal parenchymal abnormalities are visualized.

Liver

The liver is subjectively normal in size, and echogenicity with smooth peripheral margins. The parenchyma is heterogenous in echotexture with subtle, indistinct focal mottling. The visible portions of the vasculature and biliary tract appear normal. No focal nodules or cystic lesions are observed.

The gallbladder lumen is moderately distended. The wall of the gall bladder is not thickened and has a smooth mucosal surface. Luminal contents are primarily anechoic. The cystic and common bile ducts are normal/not visible.

Gastrointestinal

The stomach contains minimal luminal contents. It measures at a normal thickness of <0.7cm with some variability due to the presence of rugal folds. The distinction of the gastric wall layers is adequate and there is no impression of reduced peristaltic activity. No masses or focal lesions were observed.



PATIENT

Monty Bowen

The visualized areas of duodenum, jejunum and ileum have a relatively uniform diameter with minimal fluid distension. Wall thickness is normal. Bowel loops follow a curvilinear path with distinct wall layering maintaining the typical 1:3 muscularis:mucosa layer ratio. Jejunum wall measured 0.33 cm. Visualized peristalsis appears appropriate. There were no focal lesions consistent with obstruction or a mass effect observed.

SPECIES

Canine

The ileocecal junction was visualized and exhibited normal intact wall layering and is subjectively of normal thickness. Sections of colon are visualized with formed fecal material and gas shadowing distally. There is no observed focal or generalized colon wall thickening or loss of layering.

BREED

Husky X

Pancreas

The pancreas is normal and isoechoic to surrounding mesentery. There is no evidence of nodules or cystic lesions. There is no evidence of regional mesenteric inflammation or fluid.

SEX

Neutered Male

Free Abdomen

Evaluation of the peritoneal cavity did not reveal any evidence of effusion, or subjective lymphadenomegaly. The Medial iliac nodes appear normal and there was no evidence of a caudal aortic thrombus at the bifurcation. The omentum is of normal uniform echogenicity.

AGE

9 Years

ULTRASONOGRAPHIC FINDINGS

- Heterogeneous liver – The diffuse hepatic changes are non-specific and could be consistent with vacuolar hepatopathy, nodular hyperplasia, inflammatory/immune-mediated disease, fibrosis, extramedullary hematopoiesis, toxic hepatopathy (e.g., copper), infiltrative neoplasia (less likely) or other hepatopathy.

WEIGHT

80 Pounds

INTERPRETATION OF THE FINDINGS & FURTHER RECOMMENDATIONS

No focal lesions are visualized associated with the GI tract to explain the poor appetite reported. Unfortunately, not all causes of GI signs can be definitively diagnosed by ultrasound alone. Provided metabolic screening is normal (including testing for Addison's if clinically appropriate), then consider primary GI causes. Based on the history, I would consider dysbiosis secondary to antibiotic therapy. Other differentials would include food allergy/dietary intolerance, GI parasitism, dietary indiscretion, pancreatitis, IBD, and less likely intestinal neoplasia.

INTERPRETED BY

Kathleen Sennello DVM,
MS, Diplomate ACVIM
(Small Animal Internal
Medicine)

IMAGING PERFORMED BY

A Murphy, CVT

HOSPITAL NAME

Wauwatosa VC

REFERRING VET

Dr. Ericka Haynes

INVOICE

40659

DATE

8/23/22

- Consider a novel protein/hydrolyzed protein prescription diet.
- Recommend chronic probiotic therapy.
- Recommend a GI panel to Texas A&M for a PLI, TLI, cobalamin and folate to further evaluate the pancreas and small intestine.
- If symptoms persist, consider reevaluating bloodwork and imaging, and consider obtaining GI biopsies.



PATIENT

Monty Bowen

SPECIES

Canine

BREED

Husky X

SEX

Neutered Male

AGE

9 Years

WEIGHT

80 Pounds

INTERPRETED BY

Kathleen Sennello DVM,
MS, Diplomate ACVIM
(Small Animal Internal
Medicine)

**IMAGING
PERFORMED BY**

A Murphy, CVT

HOSPITAL NAME

Wauwatosa VC

REFERRING VET

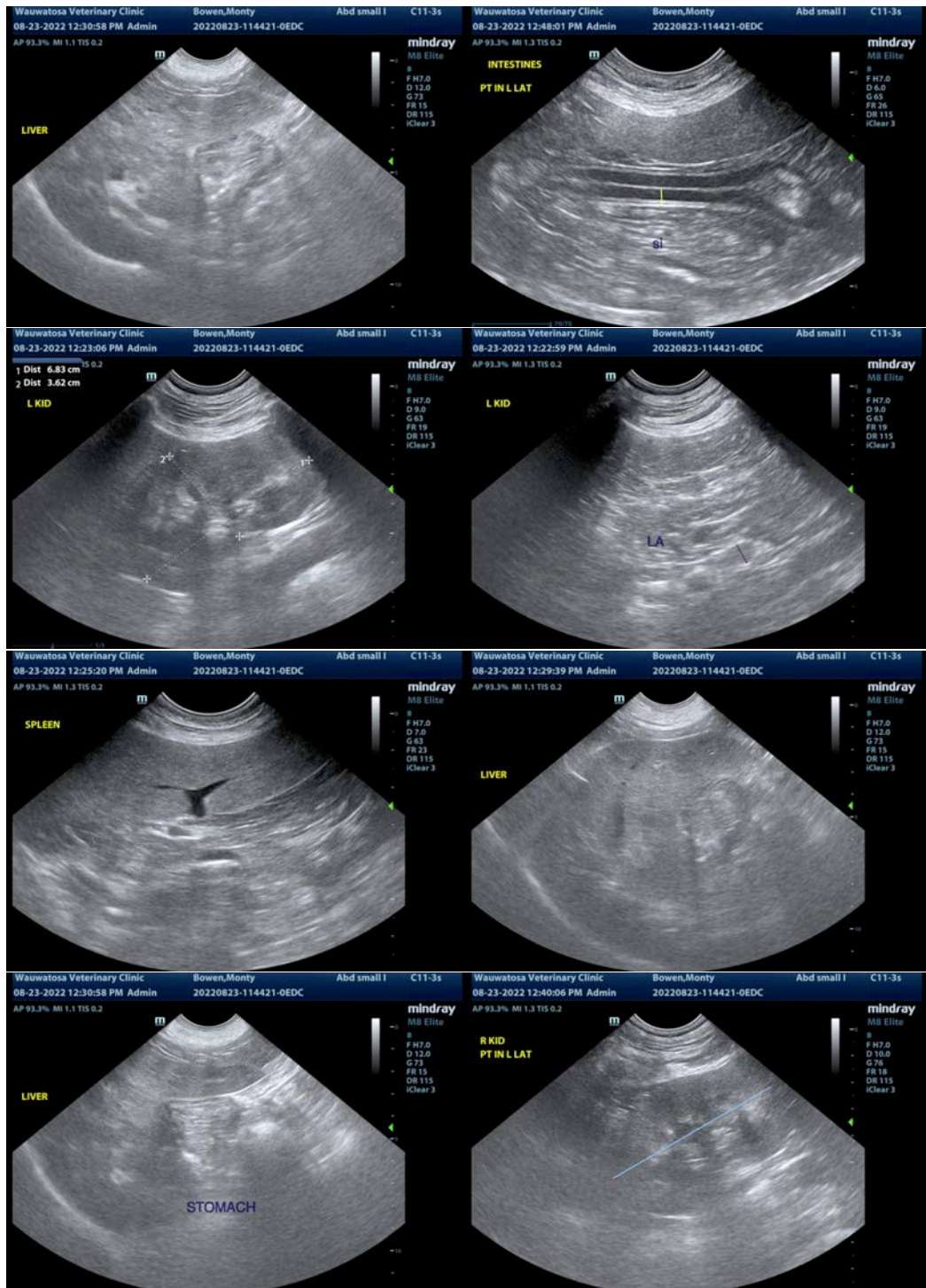
Dr. Ericka Haynes

INVOICE

40659

DATE

8/23/22





PATIENT

Monty Bowen

The information and recommendations provided are based on the images presented by the referring veterinarian/sonographer. No evaluation can be communicated regarding pathology that was not visible in the image/video clips provided.

SPECIES

Canine

Thank you for this referral. If the clinical or image interpretation does not parallel your findings or if I can be of any further assistance please contact me.

Kathleen Sennello DVM,MS, Diplomate ACVIM (Small animal Internal Medicine)

kathleen.sennello@sonopath.com

BREED

Husky X

SEX

Neutered Male

AGE

9 Years

WEIGHT

80 Pounds

INTERPRETED BY

Kathleen Sennello DVM,
MS, Diplomate ACVIM
(Small Animal Internal
Medicine)

**IMAGING
PERFORMED BY**

A Murphy, CVT

HOSPITAL NAME

Wauwatosa VC

REFERRING VET

Dr. Ericka Haynes

INVOICE

40659

DATE

8/23/22