

**PATIENT PRESENTING CLINICAL SIGNS**

Maggie Rossi Sedation 0.02ml dexdormitor/0.05ml butorphanol IV- Pre-op bloodwork for dental shows elevated ALT Last year 122, this year 164- dental schedule for tomorrow but may postpone if advised

**SPECIES**

Canine

Abnormal PE/Chem/CBC/UA Results: ALT 164 (12-118)

**BREED**

Mini Schnauzer

**ULTRASONOGRAPHIC EXAMINATION OF THE ABDOMEN**

**Urinary System**

**SEX**

Spayed Female

The urinary bladder is moderately distended with anechoic urine. The Bladder wall, trigone, ureteral papillae and visible urethra (to a depth of 2cm) appear normal with no evidence of wall thickening, mucosal irregularities, masses or cystic calculi.

**AGE**

3/27/18

The left kidney has a normal shape and size (3.56 cm). Overall echogenicity is normal with adequate corticomedullary distinction and a typical 1:3 cortex:medulla ratio. There is no evidence of focal perinephric inflammation or effusion. There is no evidence of pyelectasia, nephroliths, infarcts or hydroureter. Renal vasculature is normal.

**WEIGHT**

7.39 kg

The right kidney has a normal shape and size (5.12 cm). Overall echogenicity is normal with adequate corticomedullary distinction and a typical 1:3 cortex:medulla ratio. There is no evidence of focal perinephric inflammation or effusion. There is no evidence of pyelectasia, nephroliths, infarcts or hydroureter. Renal vasculature is normal.

**INTERPRETED BY**

Kathleen Sennello DVM,  
MS, Diplomate ACVIM  
(Small Animal Internal  
Medicine)

**Adrenal Glands**

The left adrenal gland is normal in size measuring 0.43 cm at the caudal pole. It is observed in its normal position cranial to the left renal artery. It is normal in appearance (uniformly hypoechoic) and shape with no evidence of a mass effect.

**IMAGING PERFORMED BY**

Loetitia Saint-Jacques,  
LVT

The right adrenal gland is normal in size measuring 0.33 cm at the caudal pole. It is observed in its normal position between the cranial aspect of the right kidney and the caudal vena cava. It is normal in appearance (uniformly hypoechoic) and shape with no evidence of a mass effect.

**HOSPITAL NAME**

VCA Lakeside AH

**Spleen**

The spleen is subjectively normal in size, echotexture is homogenous, and the splenic capsule is smooth with no irregularities. The blood flow through the hilus and splenic parenchyma appears normal. No focal parenchymal abnormalities are visualized.

**REFERRING VET**

Dr. Sophia Krajewski

**Liver**

The liver is subjectively normal in size, and echogenicity with smooth peripheral margins. The parenchyma is homogenous echotexture. The visible portions of the vasculature and biliary tract appear normal. On the right side of the liver in the dorsocaudal aspect, best visualized intracostally, there is an ill-defined, irregular, hyperechoic region of the liver creating a mass effect, which does not appear expansile, measuring 3.06 cm x 3.23 cm. In this same region, there is a very ill-defined, small, hypoechoic nodule measuring 0.91 cm in diameter.

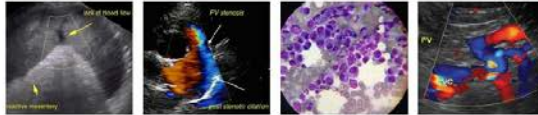
**INVOICE**

44845

**DATE**

8/22/23

The gall bladder lumen is moderately distended. The wall of the gall bladder is not thickened and has a smooth mucosal surface. There is a moderate amount of non-organized echogenic debris. The cystic and common bile ducts are normal/not visible.



**PATIENT**

Maggie Rossi

**SPECIES**

Canine

**BREED**

Mini Schnauzer

**SEX**

Spayed Female

**AGE**

3/27/18

**WEIGHT**

7.39 kg

**INTERPRETED BY**

Kathleen Sennello DVM,  
MS, Diplomate ACVIM  
(Small Animal Internal  
Medicine)

**IMAGING  
PERFORMED BY**

Loetitia Saint-Jacques,  
LVT

**HOSPITAL NAME**

VCA Lakeside AH

**REFERRING VET**

Dr. Sophia Krajewski

**INVOICE**

44845

**DATE**

8/22/23

***Gastrointestinal***

The stomach contains minimal luminal contents. It measures at a normal thickness of <0.7cm with some variability due to the presence of rugal folds. The distinction of the gastric wall layers is adequate and there is no impression of reduced peristaltic activity. No masses or focal lesions were observed.

The visualized areas of duodenum, jejunum and ileum have a relatively uniform diameter with minimal fluid distension. Wall thickness is normal. Bowel loops follow a curvilinear path with distinct wall layering maintaining the typical 1:3 muscularis:mucosa layer ratio. Duodenum wall measures 0.43 cm. Jejunum wall measured 0.24 cm. Visualized peristalsis appears appropriate. There were no focal lesions consistent with obstruction or a mass effect observed.

The ileocecal junction was visualized and exhibited normal intact wall layering and is subjectively of normal thickness. Sections of colon are visualized with formed fecal material and gas shadowing distally. There is no observed focal or generalized colon wall thickening or loss of layering.

***Pancreas***

The pancreas is mildly prominent and mottled compared to the surrounding isoechoic mesentery. There is no evidence of nodules or cystic lesions. There is no evidence of regional mesenteric inflammation or fluid.

***Free Abdomen***

Evaluation of the peritoneal cavity did not reveal any evidence of effusion. Occasional prominent mesenteric lymph nodes are visualized. One such lymph node measures 0.66 cm. The omentum is of normal echogenicity.

**PRIMARY FINDINGS**

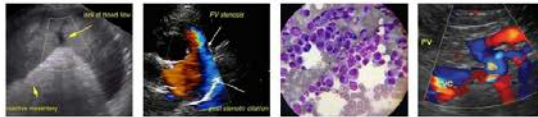
- Ill-defined, hyperechoic region of the right liver – This irregular appearance creates somewhat of a “mass effect”, although there is no deviation in the shape or margins of the liver. The appearance trends towards a benign lesion such as an area of fibrosis, remodeling, etc., but a more pathologic process (neoplasia, infection, etc.) cannot be ruled out.
- Moderate gallbladder debris – The significance of the aggregated gallbladder debris is unclear. This could represent an early mucocele, cholestasis, or may be secondary to fasting but seems unlikely to be causing a current issue. Recommend continued monitoring.

**SECONDARY FINDINGS**

- Mildly prominent, mottled right limb of the pancreas – The pancreatic changes are most consistent with age-related parenchymal remodeling, potentially secondary to a prior inflammatory episode, early fibrosis or chronic pancreatitis.

**INTERPRETATION OF THE FINDINGS & FURTHER RECOMMENDATIONS**

There is a somewhat poorly defined, irregular, hyperechoic lesion visualized in the liver. This lesion does not appear expansile and does not appear to be significantly disrupting the margins or architecture of the liver. This appearance favors a more benign process such as hyperplasia, fibrosis, etc., although a focus of infection, a neoplastic lesion, etc. cannot be ruled out. Ideally, sampling of this area would be performed, although it appears to be in an area that would be difficult to sample non-invasively. Options moving forward would include continued monitoring of this lesion or ideally a contrast CT scan to better



**PATIENT**

Maggie Rossi

**SPECIES**

Canine

**BREED**

Mini Schnauzer

**SEX**

Spayed Female

**AGE**

3/27/18

**WEIGHT**

7.39 kg

**INTERPRETED BY**

Kathleen Sennello DVM,  
MS, Diplomate ACVIM  
(Small Animal Internal  
Medicine)

**IMAGING  
PERFORMED BY**

Loetitia Saint-Jacques,  
LVT

**HOSPITAL NAME**

VCA Lakeside AH

**REFERRING VET**

Dr. Sophia Krajewski

**INVOICE**

44845

**DATE**

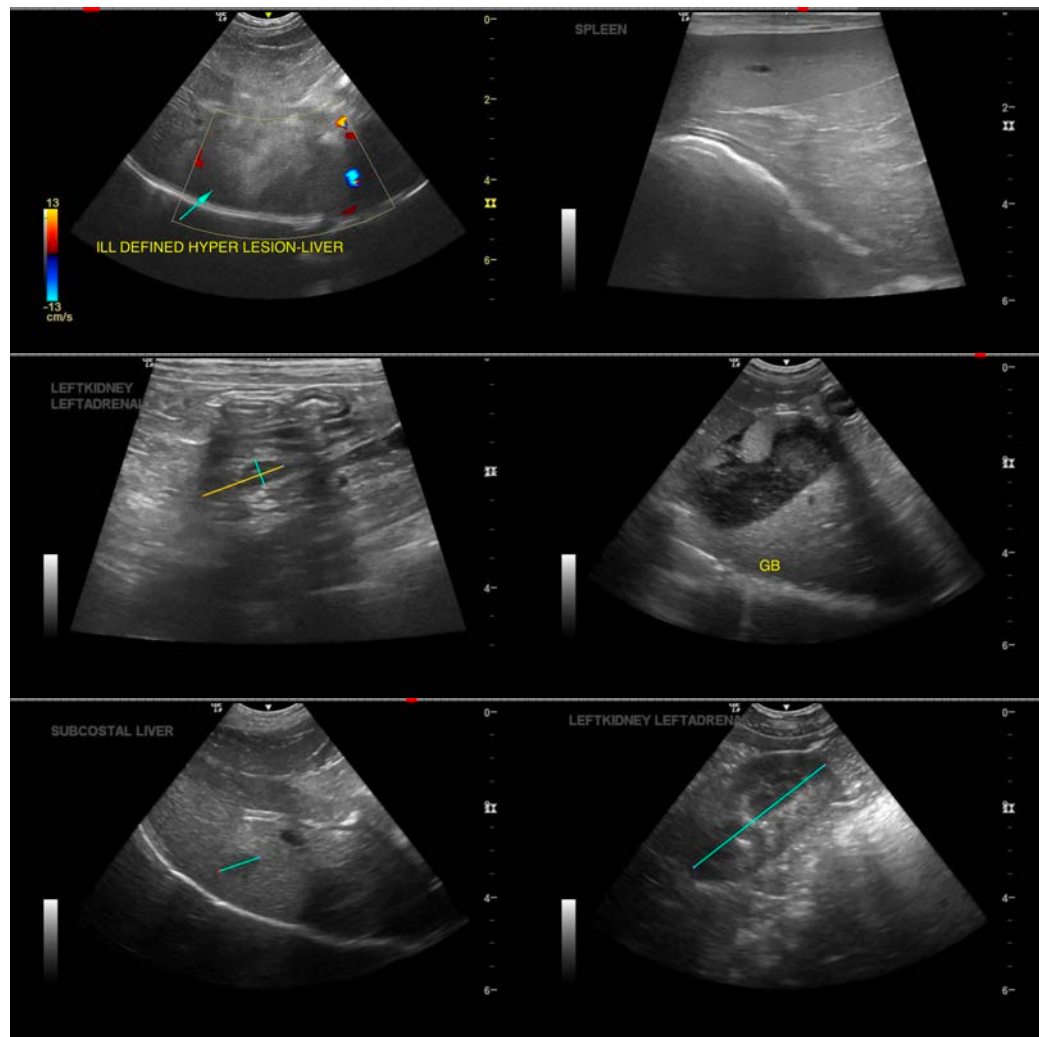
8/22/23

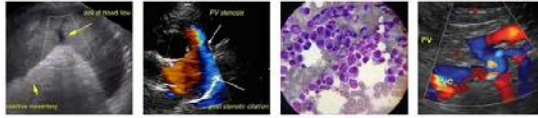
define, localize, and make a plan for this irregular area.

There is a moderate amount of debris visualized in the gallbladder with no gallbladder wall thickening or surrounding inflammation. Chronic Ursodiol therapy could be considered and/or continued monitoring of this region.

Additionally, you could consider screening for Leptospirosis and a fine needle aspirate of more normal area of liver.

Recommend three view thoracic radiographs to evaluate for possible concurrent thoracic disease/involvement.





**PATIENT**

Maggie Rossi

**SPECIES**

Canine

**BREED**

Mini Schnauzer

**SEX**

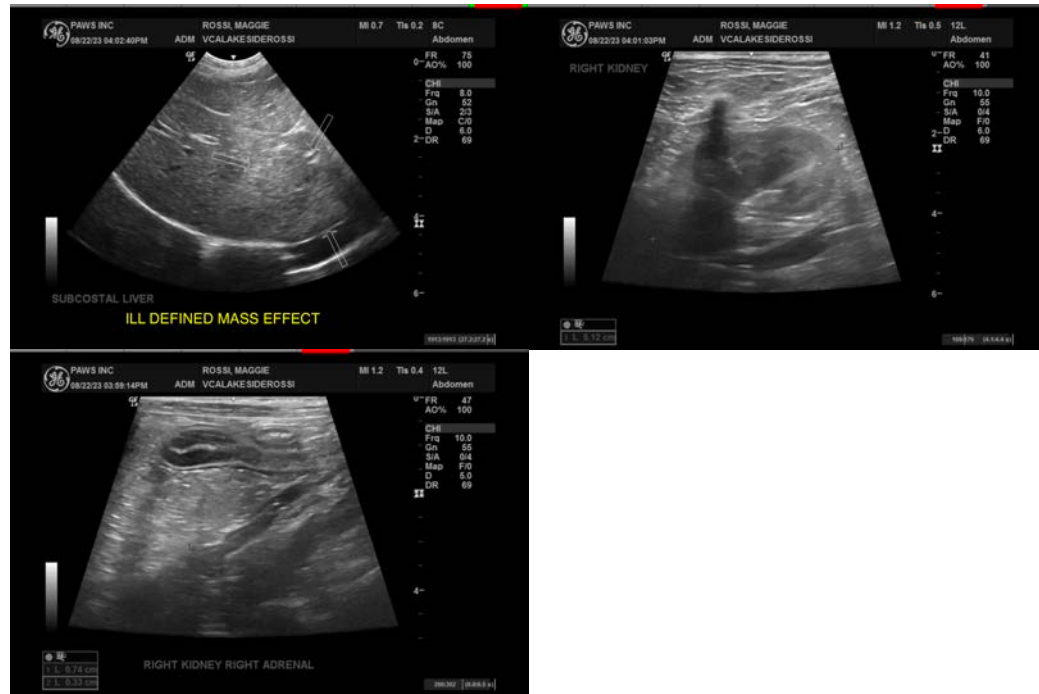
Spayed Female

**AGE**

3/27/18

**WEIGHT**

7.39 kg



**INTERPRETED BY**

Kathleen Sennello DVM,  
MS, Diplomate ACVIM  
(Small Animal Internal  
Medicine)

**IMAGING PERFORMED BY**

Loetitia Saint-Jacques,  
LVT

**HOSPITAL NAME**

VCA Lakeside AH

**REFERRING VET**

Dr. Sophia Krajewski

**INVOICE**

44845

**DATE**

8/22/23

The information and recommendations provided are based on the images presented by the referring veterinarian/sonographer. No evaluation can be communicated regarding pathology that was not visible in the image/video clips provided.

Thank you for this referral. If the clinical or image interpretation does not parallel your findings or if I can be of any further assistance please contact me.

Kathleen Sennello DVM,MS, Diplomate ACVIM (Small animal Internal Medicine)

info@sonopath.com