

**DATE PRESENTING CLINICAL SIGNS**

8/18/23

**PATIENT**

Winnie Killoran

**SPECIES**

Feline

**BREED**

DLH

**SEX**

Spayed Female

**AGE**

5/23/13

**WEIGHT**

5.78 Pounds

**INTERPRETED BY**Kathleen Sennello DVM,  
MS, Diplomate ACVIM  
(Small Animal Internal  
Medicine)**HOSPITAL NAME**Animal Emergency  
Hospital**REFERRING VET**

Dr. King

**INVOICE**

44800

(RDVM notes) seen on 6/26/23- bloodwork done- NSF seen on 7/29/23- vomited 3x times during the week- concern for stress- xrays taken- do not have; started on cerenia and Ultamino not eating the diet concern about weight loss, ultrasound recommended history from owner- ( spoke with woman)- normally healthy cat- senior wellness exam in June with rabies-overgrooming on belly (hx)- does not like other cats; can be stressed around other cats in July ( 2023)- had foster kittens for 3 weeks ( June 20th til July 13th)- had kept away from Winne; vomiting started towards the end of time there- concern it was stressed- did not stop vomiting after the kittens left; concern if she was having reaction to diet( purina- gentle formula- has been on her life); occ gets tablespoon from generic food from Aldi's ; changed diet to ultamino and cerenia: did not do well with diet- vomiting/not eating the diet once the cerenia was finished; August 5th- went back to her normal diet- kept down; had hairball August 8th; grass vomitus August 12th 15th - vomited with grass and food - coming from outside walk yesterday- vomitus with food prior health problems- none UTD on vaccines goes out on leash outside/outside walks indoor mostly

Current Medications: None listed.

Date of Previous IntraPet Ultrasound: No previous.

Sedation: Not required to complete full diagnostic ultrasound.

Stat Report: Not requested.

Imaging Performed By: Rachel Brillhart, RDMS.

**ULTRASONOGRAPHIC EXAMINATION OF THE ABDOMEN****Urinary System**

The urinary bladder is moderately distended with anechoic urine. The Bladder wall, trigone, ureteral papillae and visible urethra (to a depth of 2cm) appear normal with no evidence of wall thickening, mucosal irregularities, masses or cystic calculi.

The left kidney has a normal shape and size (3.17 cm). Overall echogenicity is normal with adequate corticomedullary distinction and a typical 1:3 cortex:medulla ratio. There is no evidence of focal perinephric inflammation or effusion. There is no evidence of pyelectasia, nephroliths, infarcts or hydroureter. Renal vasculature is normal.

The right kidney has a normal shape and size (3.37 cm). Overall echogenicity is normal with adequate corticomedullary distinction and a typical 1:3 cortex:medulla ratio. There is no evidence of focal perinephric inflammation or effusion. There is no evidence of pyelectasia, nephroliths, infarcts or hydroureter. Renal vasculature is normal.

**Adrenal Glands**

The region of left adrenal (Cranial to left renal artery) is unremarkable but the adrenal is not distinctly visualized. No evidence of a mass effect is visualized.

The right adrenal gland is normal in size measuring 0.56 cm at the caudal pole. It is observed in its normal position between the cranial aspect of the right kidney and the caudal vena cava. It is normal in appearance (uniformly hypoechoic) and shape with no evidence of a mass effect.

**Spleen**

The spleen is subjectively normal in size (0.67 cm), echotexture is homogenous, and the splenic capsule is smooth with no irregularities. The blood flow through the hilus and splenic parenchyma appears normal. No focal parenchymal abnormalities are visualized.

### ***Liver***

The liver is subjectively normal in size, and echogenicity with smooth peripheral margins. The parenchyma is homogenous echotexture. The visible portions of the vasculature and biliary tract appear normal. No focal nodules or cystic lesions are observed.

The gallbladder lumen is moderately distended. The wall of the gall bladder is not thickened and has a smooth mucosal surface. Luminal contents are mild and primarily anechoic. The cystic and common bile ducts are normal/not visible.

### ***Gastrointestinal***

The stomach contains minimal luminal contents. It measures at a normal thickness of <0.36cm with some variability due to the presence of rugal folds. The distinction of the gastric wall layers is adequate and there is no impression of reduced peristaltic activity. No masses or focal lesions were observed.

The visualized areas of duodenum, jejunum and ileum have a uniform diameter with minimal fluid distension. Wall thickness is normal to slightly increased. Bowel loops follow a typical curvilinear path with distinct wall layering, but some areas display a prominent muscularis layer which does not display the typical 1:3 muscularis:mucosa layer ratio. Jejunum wall measures 0.25 cm. Visualized peristalsis appears appropriate. There were no focal lesions consistent with obstruction or a mass effect observed.

The ileocecal junction was visualized and exhibited normal intact wall layering and is subjectively of normal thickness. Sections of colon are visualized with formed fecal material and gas shadowing distally. There is no observed focal or generalized colon wall thickening or loss of layering.

### ***Pancreas***

The pancreas is prominent and mottled compared to the surrounding isoechoic mesentery. There is no evidence of nodules or cystic lesions. There is no evidence of regional mesenteric inflammation or fluid.

### ***Free Abdomen***

Evaluation of the peritoneal cavity did not reveal any evidence of effusion. There are clusters of prominent, rounded, hypoechoic lymph nodes, examples of which measure at 0.37, 0.40, and 0.35 cm. The omentum is generally of normal echogenicity but slightly hyperechoic around the prominent lymph nodes.

## **ULTRASONOGRAPHIC FINDINGS**

- Prominent, mottled pancreas – The pancreatic changes are most consistent with mild pancreatitis or a recent episode of pancreatic inflammation.
- Subjectively thickened small intestine with a prominent muscularis layer – The small intestinal wall changes could be consistent with an underlying inflammatory process. These types of changes can sometimes be seen in normal older cats. Correlate with clinical signs.
- Prominent, mildly enlarged clusters of mesenteric lymph nodes – The prominent abdominal lymph nodes are most consistent with reactive lymphadenitis or lymphoid hyperplasia. Neoplastic infiltration is considered less likely.

## **INTERPRETATION OF THE FINDINGS & FURTHER RECOMMENDATIONS**

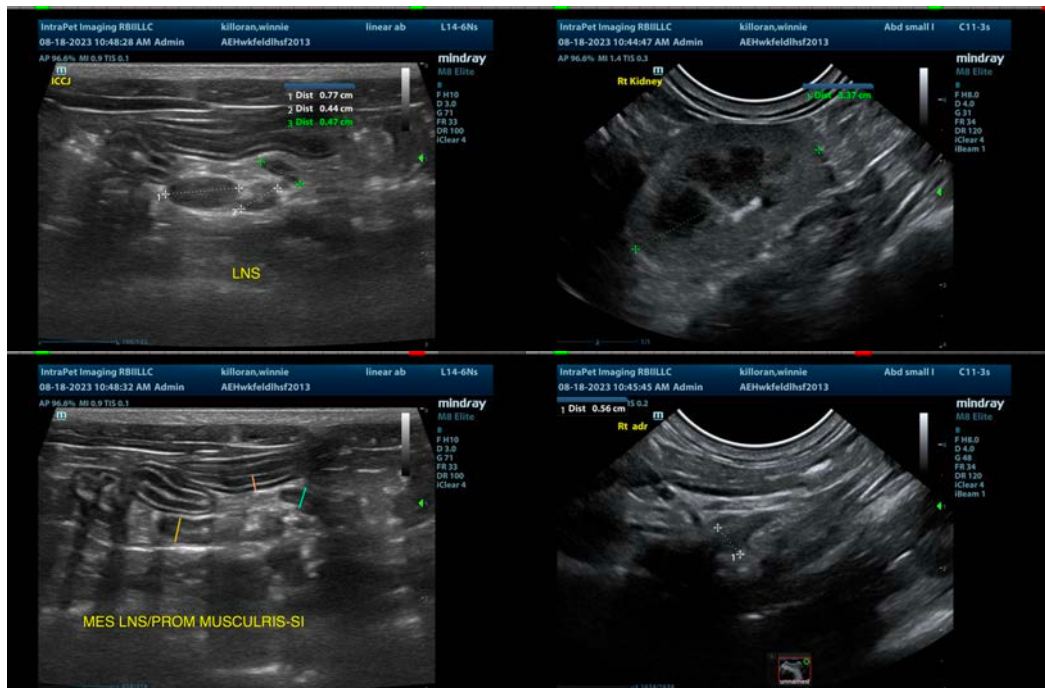
There is the general impression of diffusely mildly thickened small intestine with a prominent muscularis

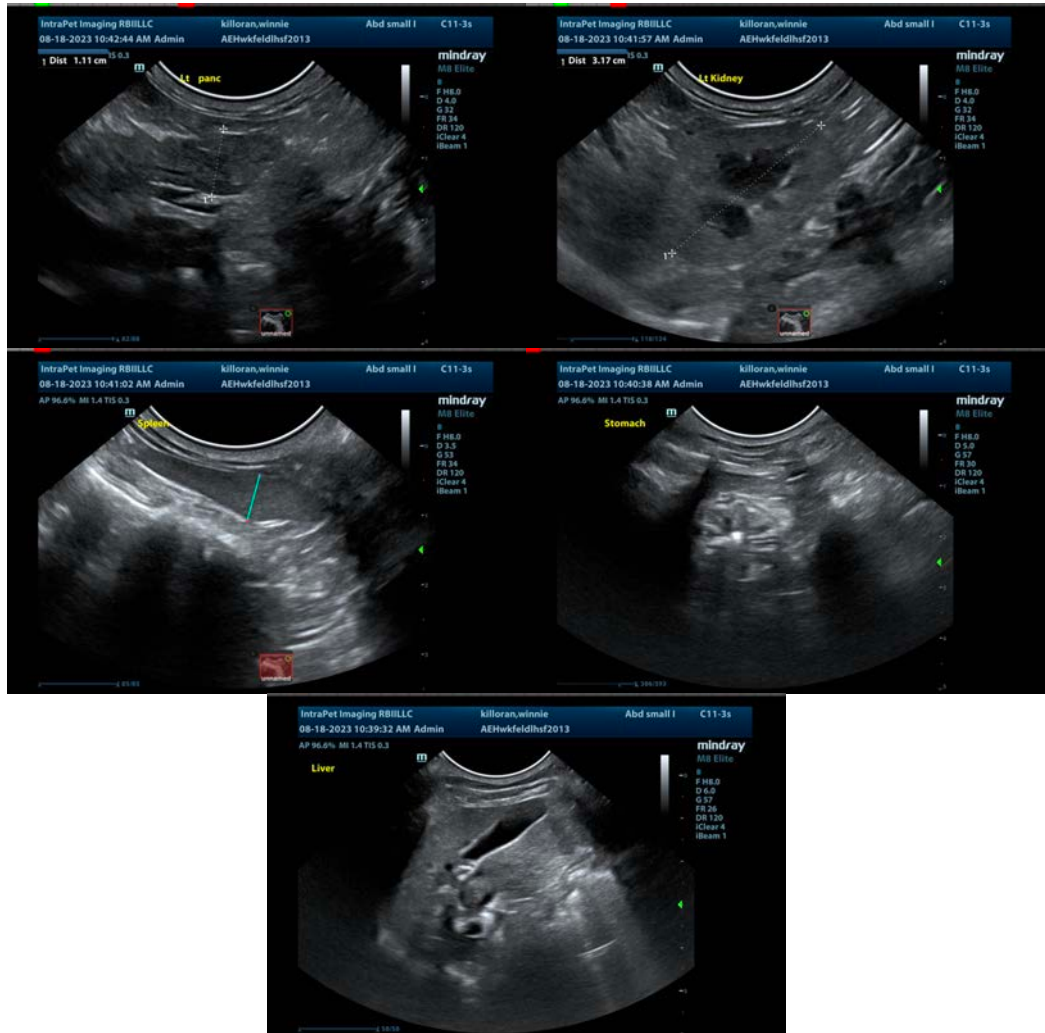
layer and some clusters of mildly enlarged mesenteric lymph nodes, which are likely reactive, but an early neoplastic process cannot be ruled out. Findings are suggestive of a primary enteropathy. Recommend current bloodwork to rule out concurrent metabolic disease.

- Consider a novel protein/hydrolyzed protein diet (exclusively at least 4-6 weeks)
- Consider a GI panel to Texas A&M for evaluation of B12 levels, folate, PLI/TLI etc.. to further evaluate for pancreatic/small intestinal disease.
- Recommend chronic probiotic therapy.

If symptoms are persistent despite taking these measures, consider obtaining GI biopsies. Additionally, fine needle aspirate of a mesenteric lymph node could be considered.

Recommend three view thoracic radiographs to evaluate for possible concurrent thoracic disease/involvement.





The information and recommendations provided are based on the images presented by the referring veterinarian/sonographer. No evaluation can be communicated regarding pathology that was not visible in the image/video clips provided.

Thank you for this referral. If the clinical or image interpretation does not parallel your findings or if I can be of any further assistance please contact me.

Kathleen Sennello DVM,MS, Diplomate ACVIM (Small animal Internal Medicine)  
info@sonopath.com