



## PATIENT

Maisie Maheu

## PRESENTING CLINICAL SIGNS

## SPECIES

Canine

## BREED

Shep/Newfoundland

## SEX

Spayed Female

sedated for 1/2 of abdominal ultrasound and aspirate- NO sedation for echo-Hx: Exam to check eyes- Owner reports no vomiting diarrhea coughing sneezing. drinking normal. activity normal. Patient has a voracious appetite. Will at times become very stiff after long walks and is a little sore but warms out of it. Her back Just seems stiff a lot even without strenuous exercise. Eyes have been a problem since early June and the right is worse than the left. Has a mucoid discharge but not pruritic. Took rads and saw a large Mass in abdomen seen on RADs. A: Suspect there is mild hemorrhage from mass in abdomen and is probably localized due to good serosal detail other than around mass. Obvious hepatic involvement but unsure if this is primary or possible metastases. Abnormal PE/Chem/CBC/UA Results: Chemistry screen: Increased ALT377, alk phos7227 and GGT21. Increased BUN45 and potassium. Increased cholesterol and PSL. CBC: Hemogram values low or low normal. Heartworm test antigen: Negative Fecal: No eggs or parasites seen Urinalysis: PH upper end of normal likely causing falsely increase protein Heart, Lungs and pulse: Heart irregularly irregular rhythm. Lungs auscult and femoral pulses within normal limits.

## ULTRASONOGRAPHIC EXAMINATION OF THE ABDOMEN

### AGE

14 Years

### Urinary System

The urinary bladder is moderately distended with anechoic urine. The Bladder wall, trigone, ureteral papillae and visible urethra (to a depth of 2cm) appear normal with no evidence of wall thickening, mucosal irregularities, masses or cystic calculi.

### WEIGHT

48 Pounds

The left kidney has a normal shape and size (5.67 cm). Overall echogenicity is slightly hyperechoic with poor corticomedullary distinction and a typical 1:3 cortex:medulla ratio. There is no evidence of perinephric inflammation or effusion. There is no evidence of pyelectasia, nephroliths, infarcts or hydroureter. Renal vasculature is normal.

## INTERPRETED BY

Kathleen Sennello DVM,  
MS, Diplomate ACVIM  
(Small Animal Internal  
Medicine)

The right kidney has a normal shape and size (60.1 cm). Overall echogenicity is slightly hyperechoic with poor corticomedullary distinction and a typical 1:3 cortex:medulla ratio. There is no evidence of perinephric inflammation or effusion. There is no evidence of pyelectasia, nephroliths, infarcts or hydroureter. Renal vasculature is normal.

## IMAGING BY

Loetitia Saint-Jacques,  
LVT

### Adrenal Glands

The left adrenal gland is normal in size measuring 0.57 cm at the cranial pole, 0.77 cm at the caudal pole, and 3.25 cm in length. It is observed in its normal position cranial to the left renal artery. The caudal pole is somewhat irregular in that there is a hyperechoic area within the normal parenchyma measuring 0.85 cm x 0.59 cm. This does not appear to deform the adrenal gland.

## HOSPITAL NAME

South Reno VH

The right adrenal gland is normal in size measuring 0.77 cm at the caudal pole. It is observed in its normal position between the cranial aspect of the right kidney and the caudal vena cava. It is normal in appearance (uniformly hypoechoic) and shape with no evidence of a mass effect.

## REFERRING VET

Dr. Schmitt

### Spleen

The spleen is subjectively normal in size. The spleen echotexture is heterogenous and mottled, the splenic capsule is smooth with no irregularities. The blood flow through the hilus and splenic parenchyma appears normal. There is a hypoechoic cystic lesion visualized in the caudal third of the spleen, measuring 0.60 cm x 0.73 cm. Additionally, there is some mottling and irregularity in the cranial pole with a hypoechoic, ill-defined region measuring 0.86 cm.

## INVOICE

40611

## DATE

8/18/22



## PATIENT

Maisie Maheu

### **Liver**

The liver is large in size and irregular. The parenchyma is heterogenous in echotexture with subtle, indistinct focal mottling. The visible portions of the vasculature and biliary tract appear normal. There is a very large, irregular, mixed echogenic, primarily solid mass effect on the left side of the liver, measuring >8.6 cm x 8.8 cm.

## SPECIES

Canine

## BREED

Shep/Newfoundland

The gall bladder lumen is moderately distended. The wall of the gall bladder is not thickened and has a smooth mucosal surface. There is a moderate amount of non-organized echogenic debris. The cystic and common bile ducts are normal/not visible.

### **Gastrointestinal**

The stomach contains minimal luminal contents. It measures at a normal thickness of <0.7cm with some variability due to the presence of rugal folds. The distinction of the gastric wall layers is adequate and there is no impression of reduced peristaltic activity. No masses or focal lesions were observed.

## SEX

Spayed Female

## AGE

14 Years

The visualized areas of duodenum, jejunum and ileum have a relatively uniform diameter with minimal fluid distension. Wall thickness is normal. Bowel loops follow a curvilinear path with distinct wall layering maintaining the typical 1:3 muscularis:mucosa layer ratio. The duodenum measured as normal (between 0.3-0.5cm in wall thickness) and the jejunum measured as normal (between 0.2-0.47cm.) Visualized peristalsis appears appropriate. There were no focal lesions consistent with obstruction or a mass effect observed.

## WEIGHT

48 Pounds

The ileocecal junction was visualized and exhibited normal intact wall layering and is subjectively of normal thickness. Sections of colon are visualized with formed fecal material and gas shadowing distally. There is no observed focal or generalized colon wall thickening or loss of layering.

## INTERPRETED BY

Kathleen Sennello DVM,  
MS, Diplomate ACVIM  
(Small Animal Internal  
Medicine)

### **Pancreas**

The pancreas is normal and isoechoic to surrounding mesentery. There is no evidence of nodules or cystic lesions. There is no evidence of regional mesenteric inflammation or fluid.

### **Free Abdomen**

There is scant free abdominal fluid. No lymphadenopathy. The omentum is hyperechoic around the liver mass.

## IMAGING BY

Loetitia Saint-Jacques,  
LVT

## PRIMARY FINDINGS

## HOSPITAL NAME

South Reno VH

- Hyperechoic region within the caudal pole of the left adrenal gland – Left/right adrenomegaly could be consistent with neoplasia (e.g., adenoma, carcinoma, pheochromocytoma), hyperplasia, inflammation, other.

## REFERRING VET

Dr. Schmitt

- Mildly mottled spleen with a hypoechoic cystic lesion and hypoechoic mottling towards the head of the spleen – The diffuse splenic changes are non-specific and could be consistent with lymphoid hyperplasia, extramedullary hematopoiesis, infiltrative neoplasia, inflammation, other. Cytology or histopathology would be necessary to get a definitive diagnosis.

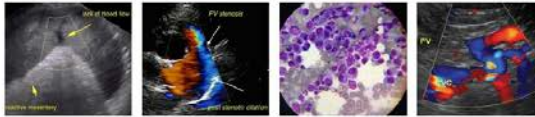
## INVOICE

40611

- Large, irregular mass effect on the left side of the liver – most consistent with a primary

## DATE

8/18/22



## PATIENT

Maisie Maheu hepatic mass (adenoma or carcinoma).

## SPECIES

Canine

- Moderate gallbladder debris – The significance of the aggregated gallbladder sludge is unclear. This could represent an early mucocele, cholestasis, or may be secondary to fasting.

## BREED

Shep/Newfoundland

- Scant free abdominal fluid

## SECONDARY FINDINGS

- Decreased corticomedullary distinction in both kidneys – The bilateral renal findings are consistent with age-related change.

## SEX

Spayed Female

## INTERPRETATION OF THE FINDINGS & FURTHER RECOMMENDATIONS

## AGE

14 Years

There is a large, irregular mass effect arising from the left side of the liver. This is most consistent with a primary hepatic mass. These can be benign or cancerous lesions, but they tend to be somewhat benign in nature in that they are slow to metastasize and often slow growing. I suspect this is the cause for the extreme ALP elevation. If these mass lesions can be removed, they carry a favorable prognosis. Recommend a contrast CT scan to further evaluate the lesion and its suitability for surgical removal.

## WEIGHT

48 Pounds

There is a hyperechoic region present in the left adrenal gland. This does not appear to be deforming the gland, which favors a more benign lesion. Unfortunately, an early neoplastic lesion is possible as well. These are my recommendations for evaluation of a lesion in the adrenal gland.

## INTERPRETED BY

Kathleen Sennello DVM,  
MS, Diplomate ACVIM  
(Small Animal Internal  
Medicine)

There is nodule present on the Left/right adrenal gland. This nodule is relatively small and is not deforming the adrenal gland significantly and doesn't appear to have any evidence of vascular invasion.

These nodules can be benign or malignant and can secrete hormones or be non-active. Options moving forward include:

## IMAGING BY

Loetitia Saint-Jacques,  
LVT

- If signs of Cushings are present, consider adrenal function testing. I prefer an ACTH stimulation test combined with an adrenal panel to the University of Tennessee's endocrine lab to look for atypical adrenal hormones as well as cortisol. (other testing can suffice)

## HOSPITAL NAME

South Reno VH

- If adrenal dependent Cushings is suspected and supported by adrenal function testing consider medical therapy with lysodren or trilostane or consider surgical removal (recommend referral to a board certified veterinary surgeon and possible pre op CT)

## REFERRING VET

Dr. Schmitt

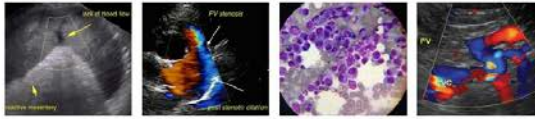
- Recommend blood pressure evaluation-if hypertensive consider testing catecholamine levels for a possible pheochromocytoma
- If no symptoms of Cushings are present, consider either referral for surgery or continued monitoring with ultrasound (in 3-4 months).

## INVOICE

40611

## DATE

8/18/22



**PATIENT**

Maisie Maheu

- Many of these nodules can be benign and incidental in nature, unfortunately that is difficult to determine with a single ultrasound.

**SPECIES**

Canine

Consider three view thoracic radiographs to rule out concurrent thoracic disease/involvement.

**BREED**

Shep/Newfoundland

There are some ill-defined lesions visualized within the spleen. These could be benign or neoplastic lesions, although metastatic disease seems less likely. Consider a fine needle aspirate of the hypoechoic lesion towards the head of the spleen. Removal could be considered at the time of surgery for the liver mass if there is concern about this lesion.

**SEX**

Spayed Female

**AGE**

14 Years

**WEIGHT**

48 Pounds

**INTERPRETED BY**

Kathleen Sennello DVM,  
MS, Diplomate ACVIM  
(Small Animal Internal  
Medicine)

**IMAGING BY**

Loetitia Saint-Jacques,  
LVT

**HOSPITAL NAME**

South Reno VH

**REFERRING VET**

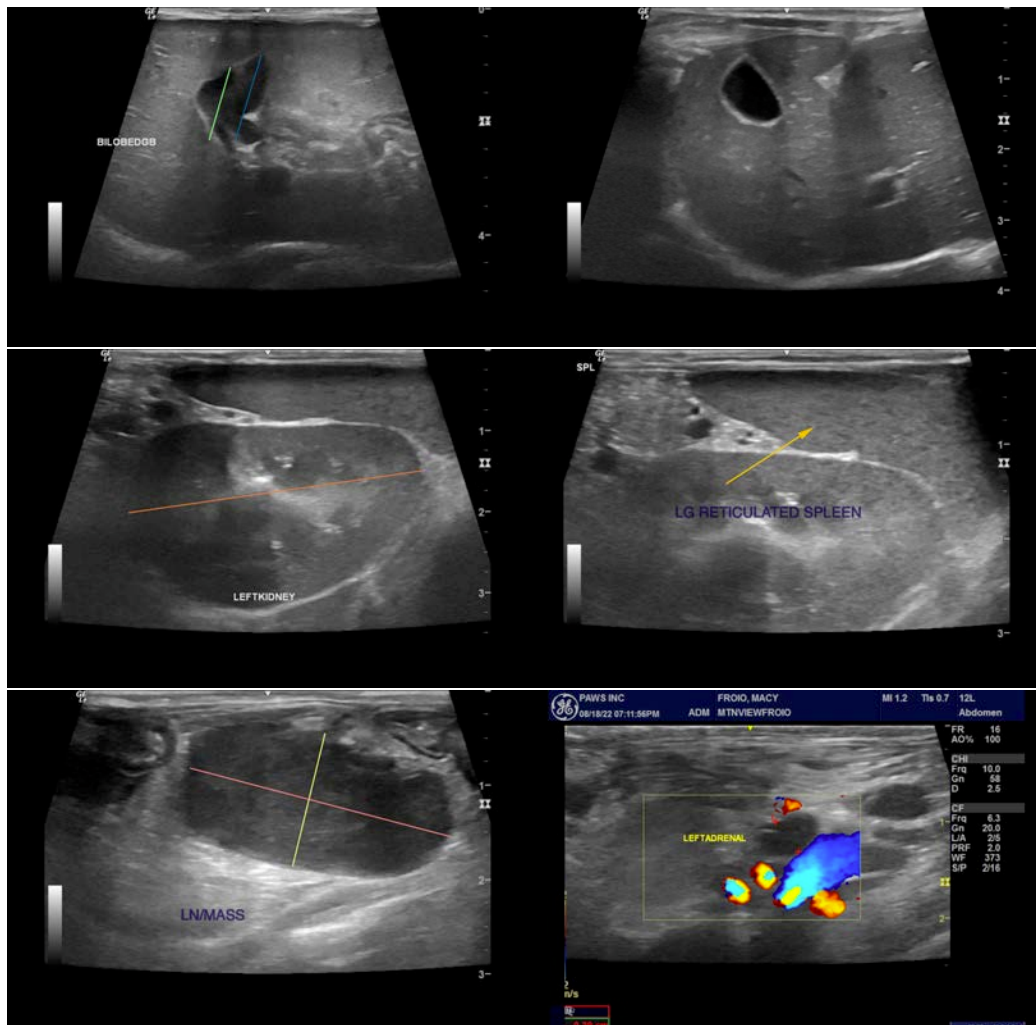
Dr. Schmitt

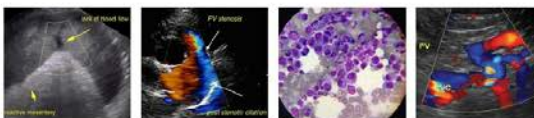
**INVOICE**

40611

**DATE**

8/18/22





**PATIENT**

Maisie Maheu

**SPECIES**

Canine

**BREED**

Shep/Newfoundland

**SEX**

Spayed Female

**AGE**

14 Years

**WEIGHT**

48 Pounds

**INTERPRETED BY**

Kathleen Sennello DVM,  
MS, Diplomate ACVIM  
(Small Animal Internal  
Medicine)

**IMAGING BY**

Loetitia Saint-Jacques,  
LVT

**HOSPITAL NAME**

South Reno VH

**REFERRING VET**

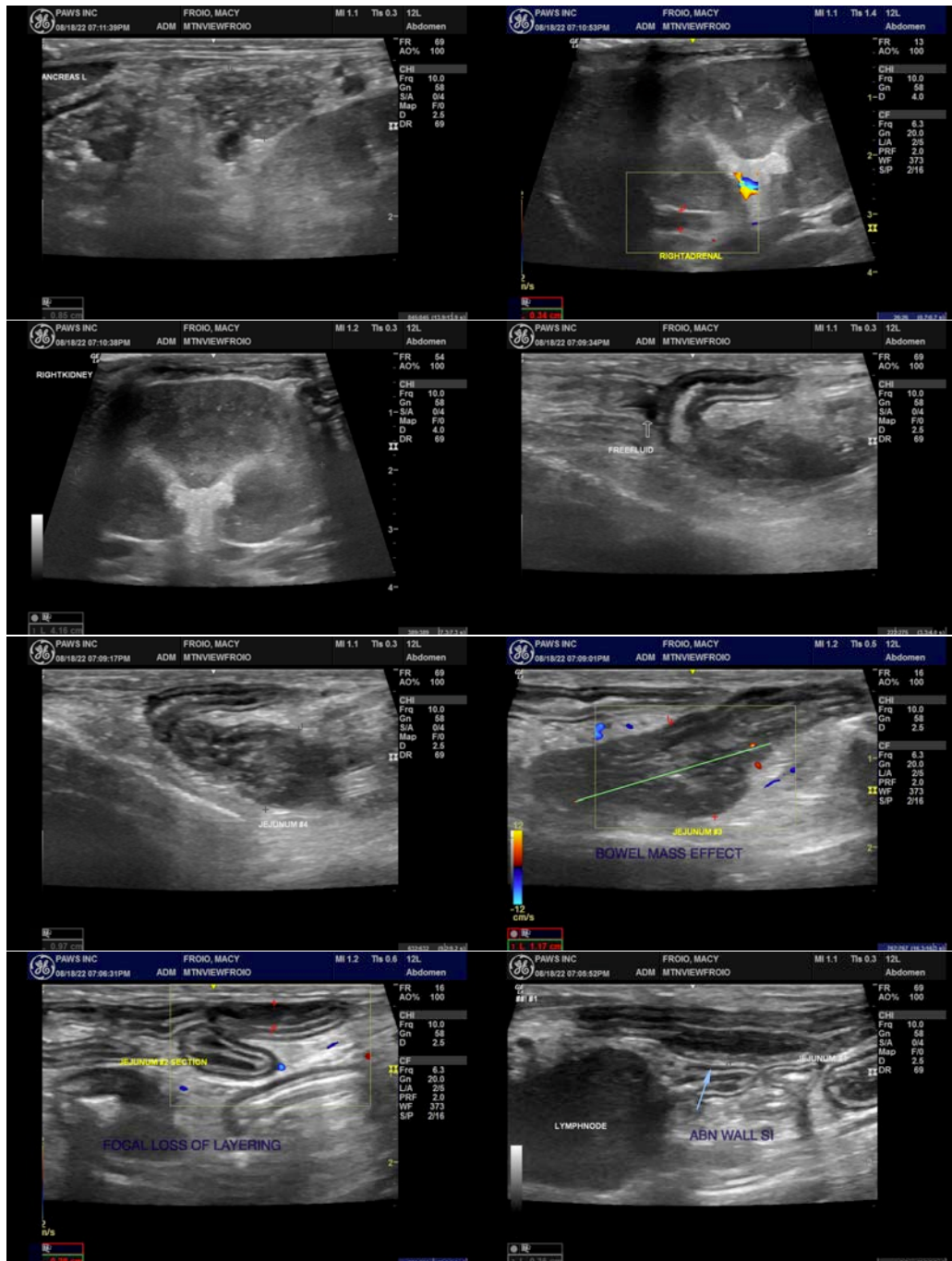
Dr. Schmitt

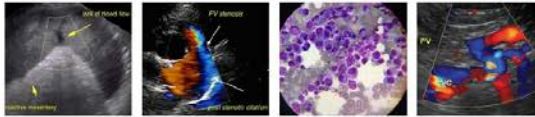
**INVOICE**

40611

**DATE**

8/18/22





**PATIENT**

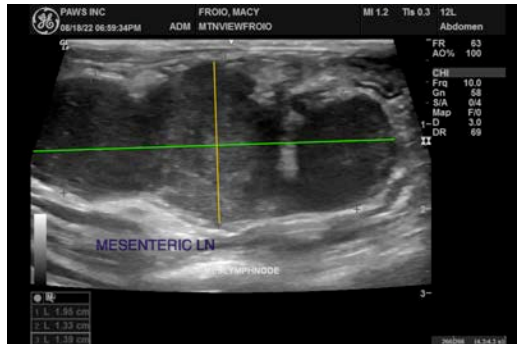
Maisie Maheu

**SPECIES**

Canine

**BREED**

Shep/Newfoundland



**SEX**

Spayed Female

The information and recommendations provided are based on the images presented by the referring veterinarian/sonographer. No evaluation can be communicated regarding pathology that was not visible in the image/video clips provided.

**AGE**

14 Years

Thank you for this referral. If the clinical or image interpretation does not parallel your findings or if I can be of any further assistance please contact me.

**WEIGHT**

48 Pounds

Kathleen Sennello DVM,MS, Diplomate ACVIM (Small animal Internal Medicine)  
kathleen.sennello@sonopath.com

**INTERPRETED BY**

Kathleen Sennello DVM,  
MS, Diplomate ACVIM  
(Small Animal Internal  
Medicine)

**IMAGING BY**

Loetitia Saint-Jacques,  
LVT

**HOSPITAL NAME**

South Reno VH

**REFERRING VET**

Dr. Schmitt

**INVOICE**

40611

**DATE**

8/18/22