



PATIENT

Hank Asbill

SPECIES

Canine

BREED

Lab

SEX

Neutered Male

AGE

8 Years

WEIGHT

85 Pounds

INTERPRETED BY

Kathleen Sennello DVM,
MS, Diplomate ACVIM
(Small Animal Internal
Medicine)

IMAGING PERFORMED BY

Dr. Ray Caughman

HOSPITAL NAME

Dogwood AH

REFERRING VET

Dr. Ray Caughman

INVOICE

40595

DATE

8/18/22

PRESENTING CLINICAL SIGNS

Hank presented 8/1/22 for vomiting and diarrhea. Bloody diarrhea noted and pet treated for HBE. Pet did well until the last 48 hours and has been vomiting a green/ yellow food and grass.
Abnormal PE/Chem/CBC/UA Results: 5lb weight loss in last 2 weeks.

ULTRASONOGRAPHIC EXAMINATION OF THE ABDOMEN

Urinary System

The urinary bladder is moderately distended with anechoic urine. The Bladder wall, trigone, ureteral papillae and visible urethra (to a depth of 2cm) appear normal with no evidence of wall thickening, mucosal irregularities, masses or cystic calculi.

The visualized areas of prostate and surrounding tissue appear normal. Unfortunately, the prostate is not fully visualized likely due to its intrapelvic location. Correlate with rectal exam findings.

The left kidney has a normal shape and size (5.18 cm). Overall echogenicity is normal with adequate corticomedullary distinction and a typical 1:3 cortex:medulla ratio. There is no evidence of perinephric inflammation or effusion. There is no evidence of pyelectasia, nephroliths, infarcts or hydroureter. Renal vasculature is normal.

The right kidney has a normal shape and size (6.94 cm). Overall echogenicity is normal with adequate corticomedullary distinction and a typical 1:3 cortex:medulla ratio. There is no evidence of perinephric inflammation or effusion. There is no evidence of pyelectasia, nephroliths, infarcts or hydroureter. Renal vasculature is normal.

Adrenal Glands

The left adrenal gland is normal in size measuring 0.60 cm at the caudal pole. It is observed in its normal position cranial to the left renal artery. It is normal in appearance (uniformly hypoechoic) and shape with no evidence of a mass effect.

The region of the right adrenal (between right cranial kidney and vena cava) is unremarkable, but the adrenal is not distinctly visualized. No evidence of a mass effect.

Spleen

The spleen is subjectively normal in size, echotexture is homogenous, and the splenic capsule is smooth with no irregularities. The blood flow through the hilus and splenic parenchyma appears normal. No focal parenchymal abnormalities are visualized.

Liver

The liver is subjectively normal in size, and echogenicity with smooth peripheral margins. The parenchyma is homogenous echotexture. The visible portions of the vasculature and biliary tract appear normal. No focal nodules or cystic lesions are observed.

The gall bladder lumen is moderately distended. The wall of the gall bladder is not thickened and has a smooth mucosal surface. There is a moderate amount of non-organized echogenic debris. The cystic and common bile ducts are normal/not visible.



PATIENT

Hank Asbill

Gastrointestinal

The stomach contains minimal luminal contents. It measures at a normal thickness of <0.7cm with some variability due to the presence of rugal folds. The distinction of the gastric wall layers is adequate and there is no impression of reduced peristaltic activity. No masses or focal lesions were observed.

SPECIES

Canine

The visualized areas of duodenum, jejunum and ileum have a relatively uniform diameter with minimal fluid distension. Wall thickness is normal. Bowel loops follow a curvilinear path with distinct wall layering maintaining the typical 1:3 muscularis:mucosa layer ratio. Jejunum wall measured 0.36 cm.

BREED

Lab

Visualized peristalsis appears appropriate. There were no focal lesions consistent with obstruction or a mass effect observed.

SEX

Neutered Male

The ileocecal junction was visualized and exhibited normal intact wall layering and is subjectively of normal thickness. Sections of colon are visualized with formed fecal material and gas shadowing distally. There is no observed focal or generalized colon wall thickening or loss of layering.

Pancreas

AGE

8 Years

The pancreas is normal and isoechoic to surrounding mesentery. There is no evidence of nodules or cystic lesions. There is no evidence of regional mesenteric inflammation or fluid.

Free Abdomen

WEIGHT

85 Pounds

Evaluation of the peritoneal cavity did not reveal any evidence of effusion, or subjective lymphadenomegaly. The Medial iliac nodes appear normal and there was no evidence of a caudal aortic thrombus at the bifurcation. The omentum is of normal uniform echogenicity.

ULTRASONOGRAPHIC FINDINGS

- Moderate gallbladder debris – The significance of the aggregated gallbladder sludge is unclear. This could represent an early mucocele, cholestasis, or may be secondary to fasting.

INTERPRETED BY

Kathleen Sennello DVM,
MS, Diplomate ACVIM
(Small Animal Internal
Medicine)

INTERPRETATION OF THE FINDINGS & FURTHER RECOMMENDATIONS

No focal lesions are visualized associated with the gastrointestinal tract. Unfortunately, not all causes for vomiting and diarrhea can be definitively diagnosed by ultrasound alone.

IMAGING PERFORMED BY

Dr. Ray Caughman

- Consider metabolic causes based on routine bloodwork.
- Consider an ACTH stimulation test or baseline cortisol to rule out Addison's.
- If metabolic disease is thought unlikely based on these test results, then consider primary gastrointestinal disease.

HOSPITAL NAME

Dogwood AH

Based on the acute nature of this presentation, I would consider such differentials as dietary intolerance/food allergy, dietary indiscretion, GI parasitism, pancreatitis, dysbiosis, infectious causes for colitis, and much less likely IBD or underlying neoplasia.

REFERRING VET

Dr. Ray Caughman

- Consider a novel protein/hydrolyzed protein prescription diet.
- Recommend screening and treatment for GI parasitism.
- Recommend chronic probiotic therapy.
- Consider screening for infectious causes of colitis (clostridia, etc.).
- Recommend screening for Addison's.
- If symptoms persist despite symptomatic treatment and additional testing, you could consider evaluation with GI biopsies.

INVOICE

40595

DATE

8/18/22



PATIENT

Hank Asbill

SPECIES

Canine

BREED

Lab

SEX

Neutered Male

AGE

8 Years

WEIGHT

85 Pounds

INTERPRETED BY

Kathleen Sennello DVM,
MS, Diplomate ACVIM
(Small Animal Internal
Medicine)

**IMAGING
PERFORMED BY**

Dr. Ray Caughman

HOSPITAL NAME

Dogwood AH

REFERRING VET

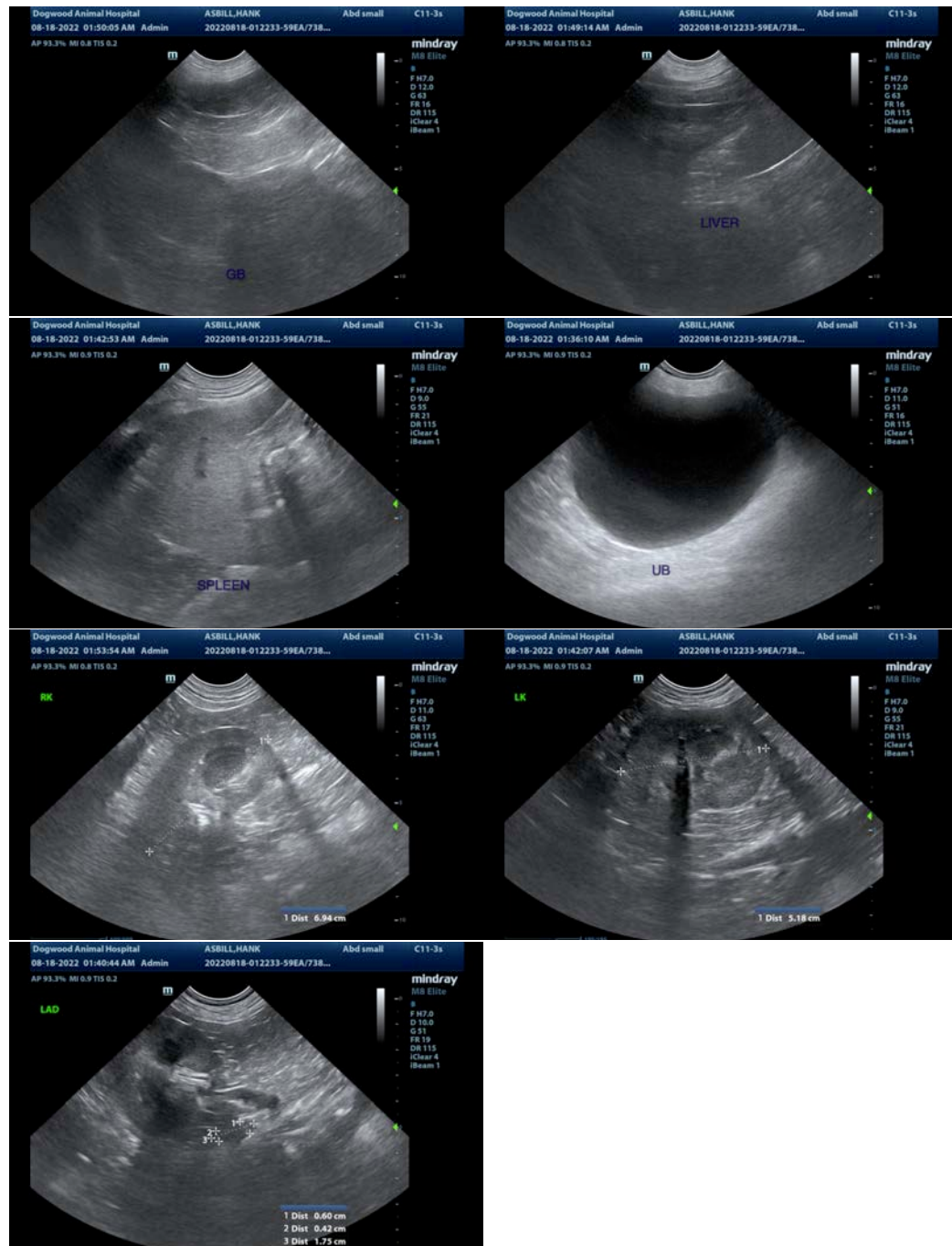
Dr. Ray Caughman

INVOICE

40595

DATE

8/18/22



The information and recommendations provided are based on the images presented by the referring veterinarian/sonographer. No evaluation can be communicated regarding pathology that was not visible in the image/video clips provided.

Thank you for this referral. If the clinical or image interpretation does not parallel your findings or if I can be of any further assistance please contact me.

Kathleen Sennello DVM,MS, Diplomate ACVIM (Small animal Internal Medicine)

kathleen.sennello@sonopath.com