



PATIENT

Dutchess Cain

PRESENTING CLINICAL SIGNS

History of recurrent UTI was last treated with Clavamox for 3 weeks. C and S run in March is attached. History of crystals in urine.

SPECIES

Canine

Abnormal PE/Chem/CBC/UA Results: U/A WBC>50/hpf, RBC >50/hpf proteinuria 500

BREED

English Bulldog

ULTRASONOGRAPHIC EXAMINATION OF THE ABDOMEN

Urinary System

The urinary bladder is moderately distended with a large amount of intraluminal echogenic debris. The Bladder wall appears mildly diffusely irregular and thickened at 0.44 cm. The area of the trigone, ureteral papillae and visible urethra (to a depth of 2cm) appear free of any mass effects or calculi.

SEX

Spayed Female

The left kidney has a normal shape and size (5.12 cm). Overall echogenicity is normal with adequate corticomedullary distinction and a typical 1:3 cortex:medulla ratio. There is no evidence of perinephric inflammation or effusion. There is no evidence of pyelectasia, nephroliths, infarcts or hydroureter. Renal vasculature is normal.

AGE

9 Years

The right kidney has a normal shape and size (6.91 cm). Overall echogenicity is normal with adequate corticomedullary distinction and a typical 1:3 cortex:medulla ratio. There is no evidence of perinephric inflammation or effusion. There is no evidence of pyelectasia, nephroliths, infarcts or hydroureter. Renal vasculature is normal.

WEIGHT

55 Pounds

Adrenal Glands

The left adrenal gland is normal in size measuring 0.65 cm at the caudal pole. It is observed in its normal position cranial to the left renal artery. It is normal in appearance (uniformly hypoechoic) and shape with no evidence of a mass effect.

INTERPRETED BY

Kathleen Sennello DVM,
MS, Diplomate ACVIM
(Small Animal Internal
Medicine)

The right adrenal gland is normal in size measuring 0.59 cm at the caudal pole. It is observed in its normal position between the cranial aspect of the right kidney and the caudal vena cava. It is normal in appearance (uniformly hypoechoic) and shape with no evidence of a mass effect.

IMAGING

PERFORMED BY

Dr. Ray Caughman

Spleen

The spleen is subjectively normal in size, echotexture is homogenous, and the splenic capsule is smooth with no irregularities. The blood flow through the hilus and splenic parenchyma appears normal. There is a discrete hypoechoic nodule visualized within the parenchyma measuring 0.52 cm.

HOSPITAL NAME

Dogwood AH

Liver

The liver is subjectively normal in size, and echogenicity with smooth peripheral margins. The parenchyma is homogenous echotexture. The visible portions of the vasculature and biliary tract appear normal. No focal nodules or cystic lesions are observed.

REFERRING VET

Dr. Ray Caughman

The gallbladder lumen is moderately distended. The wall of the gall bladder is not thickened and has a smooth mucosal surface. Luminal contents are primarily anechoic. The cystic and common bile ducts are normal/not visible.

INVOICE

40597

Gastrointestinal

The stomach contains minimal luminal contents. It measures at a normal thickness of <0.7cm with some variability due to the presence of rugal folds. The distinction of the gastric wall layers is adequate and there is no impression of reduced peristaltic activity. No masses or focal lesions were observed.

DATE

8/18/22



PATIENT

Dutchess Cain

The visualized areas of duodenum, jejunum and ileum have a relatively uniform diameter with minimal fluid distension. Wall thickness is normal. Bowel loops follow a curvilinear path with distinct wall layering maintaining the typical 1:3 muscularis:mucosa layer ratio. The duodenum measured as normal (between 0.3-0.5cm in wall thickness) and the jejunum measured as normal (between 0.2-0.47cm.) Visualized peristalsis appears appropriate. There were no focal lesions consistent with obstruction or a mass effect observed.

SPECIES

Canine

The ileocecal junction was visualized and exhibited normal intact wall layering and is subjectively of normal thickness. Sections of colon are visualized with formed fecal material and gas shadowing distally. There is no observed focal or generalized colon wall thickening or loss of layering.

BREED

English Bulldog

Pancreas

The pancreas is normal and isoechoic to surrounding mesentery. There is no evidence of nodules or cystic lesions. There is no evidence of regional mesenteric inflammation or fluid.

SEX

Spayed Female

Free Abdomen

Evaluation of the peritoneal cavity did not reveal any evidence of effusion, or subjective lymphadenomegaly. The Medial iliac nodes appear normal and there was no evidence of a caudal aortic thrombus at the bifurcation. The omentum is of normal uniform echogenicity.

AGE

9 Years

ULTRASONOGRAPHIC FINDINGS

WEIGHT

55 Pounds

- Irregular thickened wall with large amount of echogenic debris – most consistent with cystitis. Recommend urinalysis and culture.
- Small, discrete hypoechoic nodule visualized within the spleen – There is a non-cavitated, hypoechoic splenic nodule visualized. Differentials include lymphoid hyperplasia, extramedullary hematopoiesis, infiltrative neoplasia, inflammation, other. Cytology or histopathology would be necessary to get a definitive diagnosis.

INTERPRETED BY

Kathleen Sennello DVM,
MS, Diplomate ACVIM
(Small Animal Internal
Medicine)

INTERPRETATION OF THE FINDINGS & FURTHER RECOMMENDATIONS

The changes in the urinary bladder are consistent with the historical urinary tract infections reported. No obvious anatomic abnormalities are visualized to explain the recurrence.

IMAGING

PERFORMED BY

Dr. Ray Caughman

Consider possible metabolic causes. Recommend full bloodwork to look for evidence of diabetes, Cushing's disease, underlying renal disease, etc.

HOSPITAL NAME

Dogwood AH

Consider anatomic abnormalities. Nothing was observed on today's scan. This does not definitively rule out the possibility of some subtle urachal diverticuli, ectopic ureters, etc., but makes it much less likely. Additionally, consider vaginal and vulvar irregularities/abnormalities.

REFERRING VET

Dr. Ray Caughman

In a bulldog, also strongly consider the possibility of a juvenile vulva or excessive skin folds trapping moisture and bacteria.

INVOICE

40597

- Recommend diligent urinalysis and culturing to make sure appropriate antibiotic therapy is pursued, so as to try and reduce resistance issues.
- Recommend chronic probiotic therapy.
- Recommend using wipes and frequent urination/walks
- If external genitalia appears normal and there are no metabolic abnormalities, you could consider a vaginoscopy/cystoscopy to further evaluate the urogenital tract.
- Additionally, consider reimaging of the urinary bladder mid or at the end of antibiotic therapy to ensure the bladder wall irregularity and debris has cleared.

DATE

8/18/22



PATIENT

Dutchess Cain

There is a small hypo echoic nodule visualized in the spleen. This could be a benign lesion or an early neoplastic lesion. Options moving forward include continued monitoring with ultrasound or a fine Needle aspirate of the nodule.

SPECIES

Canine

BREED

English Bulldog

SEX

Spayed Female

AGE

9 Years

WEIGHT

55 Pounds

INTERPRETED BY

Kathleen Sennello DVM,
MS, Diplomate ACVIM
(Small Animal Internal
Medicine)

**IMAGING
PERFORMED BY**

Dr. Ray Caughman

HOSPITAL NAME

Dogwood AH

REFERRING VET

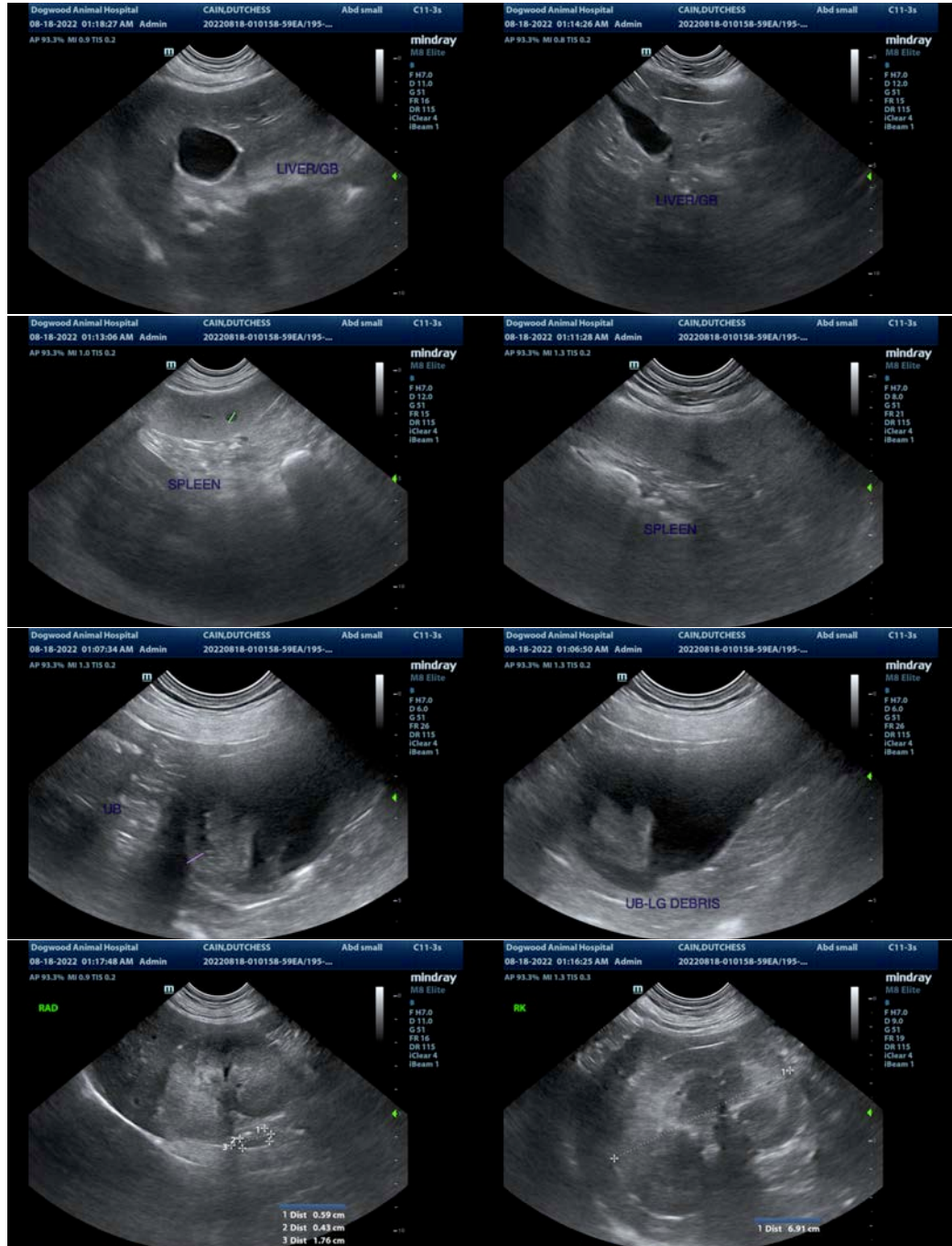
Dr. Ray Caughman

INVOICE

40597

DATE

8/18/22





PATIENT

Dutchess Cain

SPECIES

Canine

BREED

English Bulldog

SEX

Spayed Female

AGE

9 Years

WEIGHT

55 Pounds

INTERPRETED BY

Kathleen Sennello DVM,
MS, Diplomate ACVIM
(Small Animal Internal
Medicine)

**IMAGING
PERFORMED BY**

Dr. Ray Caughman

HOSPITAL NAME

Dogwood AH

REFERRING VET

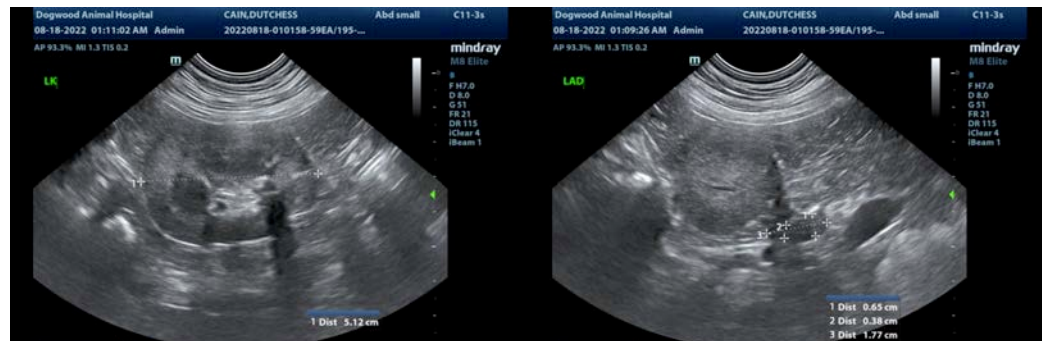
Dr. Ray Caughman

INVOICE

40597

DATE

8/18/22



The information and recommendations provided are based on the images presented by the referring veterinarian/sonographer. No evaluation can be communicated regarding pathology that was not visible in the image/video clips provided.

Thank you for this referral. If the clinical or image interpretation does not parallel your findings or if I can be of any further assistance please contact me.

Kathleen Sennello DVM,MS, Diplomate ACVIM (Small animal Internal Medicine)

kathleen.sennello@sonopath.com