



PATIENT

Sally Wilder

PRESENTING CLINICAL SIGNS

attempted to drain a very large mass on leg- thick yellow tinged fluid- is this surgical? Steps? LABS
WNL= VIDEO of mass sent via text

SPECIES

Canine

ULTRASONOGRAPHIC EXAMINATION OF THE ABDOMEN

BREED

GSD

Urinary System

The urinary bladder is moderately distended with anechoic urine. The Bladder wall, trigone, ureteral papillae and visible urethra (to a depth of 2cm) appear normal with no evidence of wall thickening, mucosal irregularities, masses or cystic calculi.

SEX

Spayed Female

The left kidney has a normal shape and size (5.0 cm). Overall echogenicity is normal with adequate corticomedullary distinction and a typical 1:3 cortex:medulla ratio. There is no evidence of perinephric inflammation or effusion. There is no evidence of pyelectasia, nephroliths, infarcts or hydroureter. Renal vasculature is normal.

AGE

8 Years

The right kidney has a normal shape and size (6.3 cm). Overall echogenicity is normal with adequate corticomedullary distinction and a typical 1:3 cortex:medulla ratio. There is no evidence of perinephric inflammation or effusion. There is no evidence of pyelectasia, nephroliths, infarcts or hydroureter. Renal vasculature is normal.

WEIGHT

138 Pounds

Adrenal Glands

The left adrenal gland is normal in size measuring 0.46 cm at the caudal pole. It is observed in its normal position cranial to the left renal artery. It is normal in appearance (uniformly hypoechoic) and shape with no evidence of a mass effect.

INTERPRETED BY

Kathleen Sennello DVM,
MS, Diplomate ACVIM
(Small Animal Internal
Medicine)

The right adrenal gland is normal in size measuring 0.64 cm at the caudal pole. It is observed in its normal position between the cranial aspect of the right kidney and the caudal vena cava. It is normal in appearance (uniformly hypoechoic) and shape with no evidence of a mass effect.

IMAGING PERFORMED BY

Loetitia Saint-Jacques, RVT

Spleen

The spleen is subjectively normal in size, echotexture is homogenous, and the splenic capsule is smooth with no irregularities. The blood flow through the hilus and splenic parenchyma appears normal. No focal parenchymal abnormalities are visualized.

HOSPITAL NAME

Pine Creek VC

Liver

The liver is subjectively normal in size, and echogenicity with smooth peripheral margins. The parenchyma is homogenous echotexture. The visible portions of the vasculature and biliary tract appear normal. No focal nodules or cystic lesions are observed.

REFERRING VET

Dr. Denny Nolet

The gallbladder lumen is moderately distended. The wall of the gall bladder is not thickened and has a smooth mucosal surface. Luminal contents are primarily anechoic. The cystic and common bile ducts are normal/not visible.

INVOICE

24820

Gastrointestinal

The stomach contains minimal luminal contents. It measures at a normal thickness of <0.7cm with some variability due to the presence of rugal folds. The distinction of the gastric wall layers is adequate and there is no impression of reduced peristaltic activity. No masses or focal lesions were observed.

DATE

8/18/21



PATIENT

Sally Wilder

SPECIES

Canine

The visualized areas of duodenum, jejunum and ileum have a relatively uniform diameter with minimal fluid distension. Wall thickness is normal. Bowel loops follow a curvilinear path with distinct wall layering maintaining the typical 1:3 muscularis:mucosa layer ratio. Jejunum wall measured 0.26 cm. Visualized peristalsis appears appropriate. There were no focal lesions consistent with obstruction or a mass effect observed.

BREED

GSD

The ileocecal junction was visualized and exhibited normal intact wall layering and is subjectively of normal thickness. Sections of colon are visualized with formed fecal material and gas shadowing distally. There is no observed focal or generalized colon wall thickening or loss of layering.

SEX

Spayed Female

Pancreas

The area of the pancreas is normal and isoechoic to surrounding mesentery. There is no evidence of nodules or cystic lesions. There is no evidence of regional mesenteric inflammation or fluid.

AGE

8 Years

Free Abdomen

Evaluation of the peritoneal cavity did not reveal any evidence of effusion, or subjective lymphadenomegaly. The Medial iliac nodes appear normal and there was no evidence of a caudal aortic thrombus at the bifurcation. The omentum is of normal uniform echogenicity.

WEIGHT

138 Pounds

Mass Effect Right Pelvic Limb

There is a large, well circumscribed, subcutaneous and cystic appearing mass in the right pelvic limb. The exact dimensions are difficult to ascertain, but it appears to be at least 5.4 cm deep and >10 cm x 9 cm in circumference. This mass lesion appears relatively mildly vascular and has large cystic components varying in size from 1.0 cm – 7.0 cm in diameter. The findings are most consistent with a mass effect, an abscess is possible but seems less likely.

INTERPRETED BY

Kathleen Sennello DVM,
MS, Diplomate ACVIM
(Small Animal Internal
Medicine)

ULTRASONOGRAPHIC FINDINGS

- No significant ultrasonographic lesions observed in the abdomen
- Large, cystic, well circumscribed right pelvic limb mass

IMAGING PERFORMED BY

Loetitia Saint-Jacques, RVT

INTERPRETATION OF THE FINDINGS & FURTHER RECOMMENDATIONS

This lesion could be benign or malignant. The size favors a benign mass, but it may be locally invasive. The margins appear fairly well circumscribed, but removal would be a challenge due to the size of the mass. Recommendations moving forward include 3-view chest radiographs, a CT scan of the pelvis and pelvic limb, and a biopsy of the abnormal tissue at the time of anesthesia for the CT scan. Based on this information, a surgical and oncologic consultation can be obtained for the best outcome. There is no evidence of an obvious metastatic lesion in the abdomen.

HOSPITAL NAME

Pine Creek VC

REFERRING VET

Dr. Denny Nolet

INVOICE

24820

DATE

8/18/21



PATIENT

Sally Wilder

SPECIES

Canine

BREED

GSD

SEX

Spayed Female

AGE

8 Years

WEIGHT

138 Pounds

INTERPRETED BY

Kathleen Sennello DVM,
MS, Diplomate ACVIM
(Small Animal Internal
Medicine)

IMAGING PERFORMED BY

Loetitia Saint-Jacques, RVT

HOSPITAL NAME

Pine Creek VC

REFERRING VET

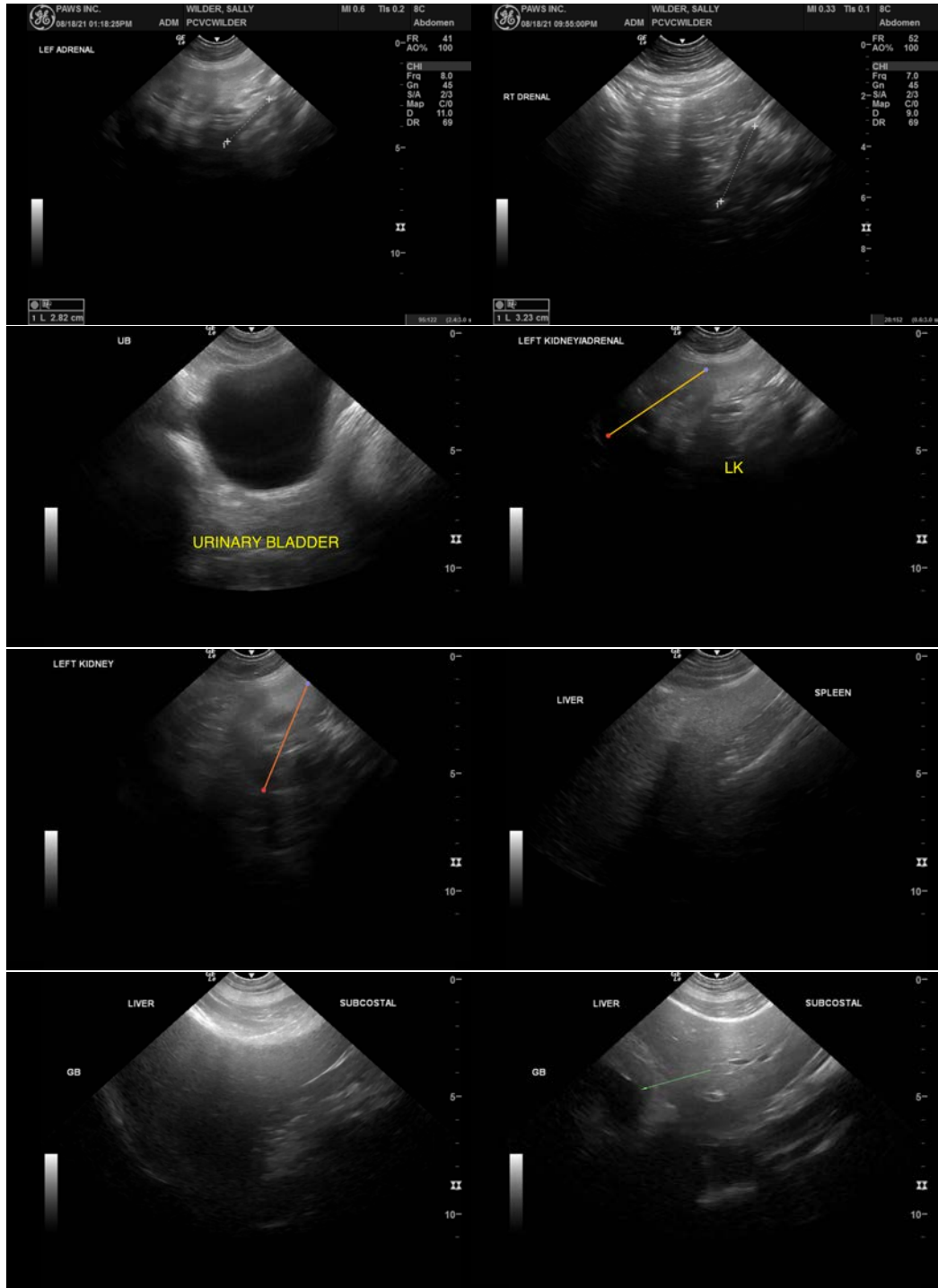
Dr. Denny Nolet

INVOICE

24820

DATE

8/18/21





PATIENT

Sally Wilder

SPECIES

Canine

BREED

GSD

SEX

Spayed Female

AGE

8 Years

WEIGHT

138 Pounds

INTERPRETED BY

Kathleen Sennello DVM,
MS, Diplomate ACVIM
(Small Animal Internal
Medicine)

IMAGING PERFORMED BY

Loetitia Saint-Jacques, RVT

HOSPITAL NAME

Pine Creek VC

REFERRING VET

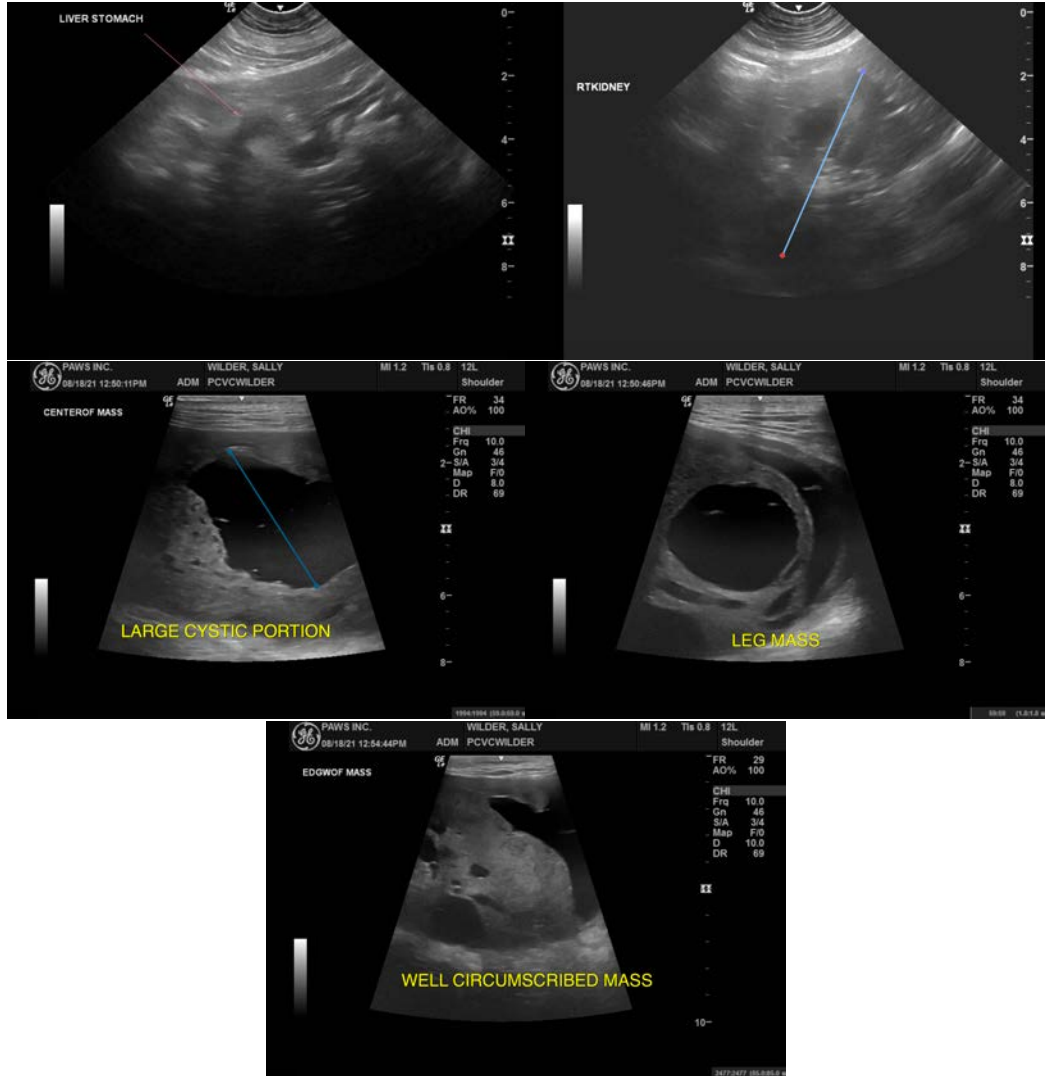
Dr. Denny Nolet

INVOICE

24820

DATE

8/18/21



The information and recommendations provided are based on the images presented by the referring veterinarian. No evaluation can be communicated regarding pathology that was not visible in the image/video clips provided.

Thank you for this referral. If the clinical or image interpretation does not parallel your findings or if I can be of any further assistance please contact me.

Kathleen Sennello DVM,MS, Diplomate ACVIM (Small animal Internal Medicine)

kathleen.sennello@sonopath.com