



**PATIENT**

Marshmallow  
Dellaterza

**SPECIES**

Canine

**BREED**

Standard Poodle

**SEX**

Spayed Female

**AGE**

5 Years

**WEIGHT**

52.5 Pounds

**INTERPRETED BY**

Kathleen Sennello DVM,  
MS, Diplomate ACVIM  
(Small Animal Internal  
Medicine)

**IMAGING  
PERFORMED BY**

Shari Reffi, CVT

**HOSPITAL NAME**

Whippany VH

**REFERRING VET**

Dr. Van Beveren

**INVOICE**

44778

**DATE**

8/17/23

**PRESENTING CLINICAL SIGNS**

CaOx crystals seen on UA. O prefers ultrasound vs radiographs. Vomiting every other day (mid-day) undigested food or bile.

Abnormal PE/Chem/CBC/UA Results: BW WNL 5/5/2023. USG 1.055; PH 6; Protein +1; Bili +1; CaOx 21-50 (repeatable)

**ULTRASONOGRAPHIC EXAMINATION OF THE ABDOMEN**

**Urinary System**

The urinary bladder is moderately distended with anechoic urine. The Bladder wall, trigone, ureteral papillae and visible urethra (to a depth of 2cm) appear normal with no evidence of wall thickening, mucosal irregularities, masses or cystic calculi.

The left kidney has a normal shape and size (5.52 cm). Overall echogenicity is normal with adequate corticomedullary distinction and a typical 1:3 cortex:medulla ratio. There is no evidence of focal perinephric inflammation or effusion. There is no evidence of pyelectasia, nephroliths, infarcts or hydroureter. Renal vasculature is normal.

The right kidney has a normal shape and size (6.74 cm). Overall echogenicity is normal with adequate corticomedullary distinction and a typical 1:3 cortex:medulla ratio. There is no evidence of focal perinephric inflammation or effusion. There is no evidence of pyelectasia, nephroliths, infarcts or hydroureter. Renal vasculature is normal.

**Adrenal Glands**

The left adrenal gland is normal/borderline flat, measuring 0.21 cm at the caudal pole. It is observed in its normal position cranial to the left renal artery. It is normal in appearance (uniformly hypoechoic) and shape with no evidence of a mass effect.

The right adrenal gland is normal in size measuring 0.55 cm at the caudal pole. It is observed in its normal position between the cranial aspect of the right kidney and the caudal vena cava. It is normal in appearance (uniformly hypoechoic) and shape with no evidence of a mass effect.

**Spleen**

The spleen is subjectively normal in size, echotexture is homogenous, and the splenic capsule is smooth with no irregularities. The blood flow through the hilus and splenic parenchyma appears normal. No focal parenchymal abnormalities are visualized.

**Liver**

The liver is subjectively normal in size, and echogenicity with smooth peripheral margins. The parenchyma is homogenous echotexture. The visible portions of the vasculature and biliary tract appear normal. No focal nodules or cystic lesions are observed.

The gallbladder lumen is moderately distended. The wall of the gall bladder is not thickened and has a smooth mucosal surface. Luminal contents are mild and primarily anechoic. The cystic and common bile ducts are normal/not visible.



**PATIENT**

***Gastrointestinal***

Marshmallow  
Dellaterza

The stomach contains minimal luminal contents. It measures at a normal thickness of <0.7cm with some variability due to the presence of rugal folds. The distinction of the gastric wall layers is adequate and there is no impression of reduced peristaltic activity. No masses or focal lesions were observed.

**SPECIES**

Canine

The visualized areas of duodenum, jejunum and ileum have a relatively uniform diameter with minimal fluid distension. Wall thickness is normal. Bowel loops follow a curvilinear path with distinct wall layering maintaining the typical 1:3 muscularis:mucosa layer ratio. Jejunum wall measures 0.32 cm. Visualized peristalsis appears appropriate. There were no focal lesions consistent with obstruction or a mass effect observed.

**BREED**

Standard Poodle

**SEX**

Spayed Female

The ileocecal junction was visualized and exhibited normal intact wall layering and is subjectively of normal thickness. Sections of colon are visualized with formed fecal material and gas shadowing distally. There is no observed focal or generalized colon wall thickening or loss of layering.

**AGE**

5 Years

***Pancreas***

The area of the pancreas is normal and isoechoic to surrounding mesentery. There is no evidence of nodules or cystic lesions. There is no evidence of regional mesenteric inflammation or fluid.

**WEIGHT**

52.5 Pounds

***Free Abdomen***

Evaluation of the peritoneal cavity did not reveal any evidence of effusion, or subjective lymphadenomegaly. The Medial iliac nodes appear normal and there was no evidence of a caudal aortic thrombus at the bifurcation. The omentum is of normal uniform echogenicity.

**INTERPRETED BY**

Kathleen Sennello DVM,  
MS, Diplomate ACVIM  
(Small Animal Internal  
Medicine)

**ULTRASONOGRAPHIC FINDINGS**

- Subjectively small adrenal glands – This could be within normal limits for this individual. Consider screening for Addison’s disease.

**IMAGING PERFORMED BY**

Shari Reffi, CVT

**INTERPRETATION OF THE FINDINGS & FURTHER RECOMMENDATIONS**

No focal lesions are visualized associated with the urinary tract to explain the calcium oxalate crystals identified. Correlate with abdominal radiographs, which can pick up some small stones in the area of the ureters, distal urethra, etc., which cannot always be easily seen with ultrasound.

**HOSPITAL NAME**

Whippany VH

No focal lesions are visualized associated with the gastrointestinal tract to explain the chronic intermittent vomiting reported. Unfortunately, there are many causes for vomiting that cannot be diagnosed by ultrasound alone.

**REFERRING VET**

Dr. Van Beveren

Consider such differentials as food allergy/dietary intolerance, GI parasitism, pancreatitis, dysbiosis, recurrent dietary indiscretion, IBD and less likely neoplasia, etc....

**INVOICE**

44778

- Consider a novel protein/hydrolyzed protein diet (exclusively at least 4-6 weeks)
- Consider a GI panel to Texas A&M for evaluation of B12 levels, folate, PLI/TLI etc.. to further evaluate for pancreatic/small intestinal disease.

**DATE**

8/17/23

- Recommend chronic probiotic therapy.

If symptoms persist or worsen, it may be necessary to obtain GI biopsies and obtain further information.



**PATIENT**

Marshmallow  
Dellaterza

**SPECIES**

Canine

**BREED**

Standard Poodle

**SEX**

Spayed Female

**AGE**

5 Years

**WEIGHT**

52.5 Pounds

**INTERPRETED BY**

Kathleen Sennello DVM,  
MS, Diplomate ACVIM  
(Small Animal Internal  
Medicine)

**IMAGING  
PERFORMED BY**

Shari Reffi, CVT

**HOSPITAL NAME**

Whippany VH

**REFERRING VET**

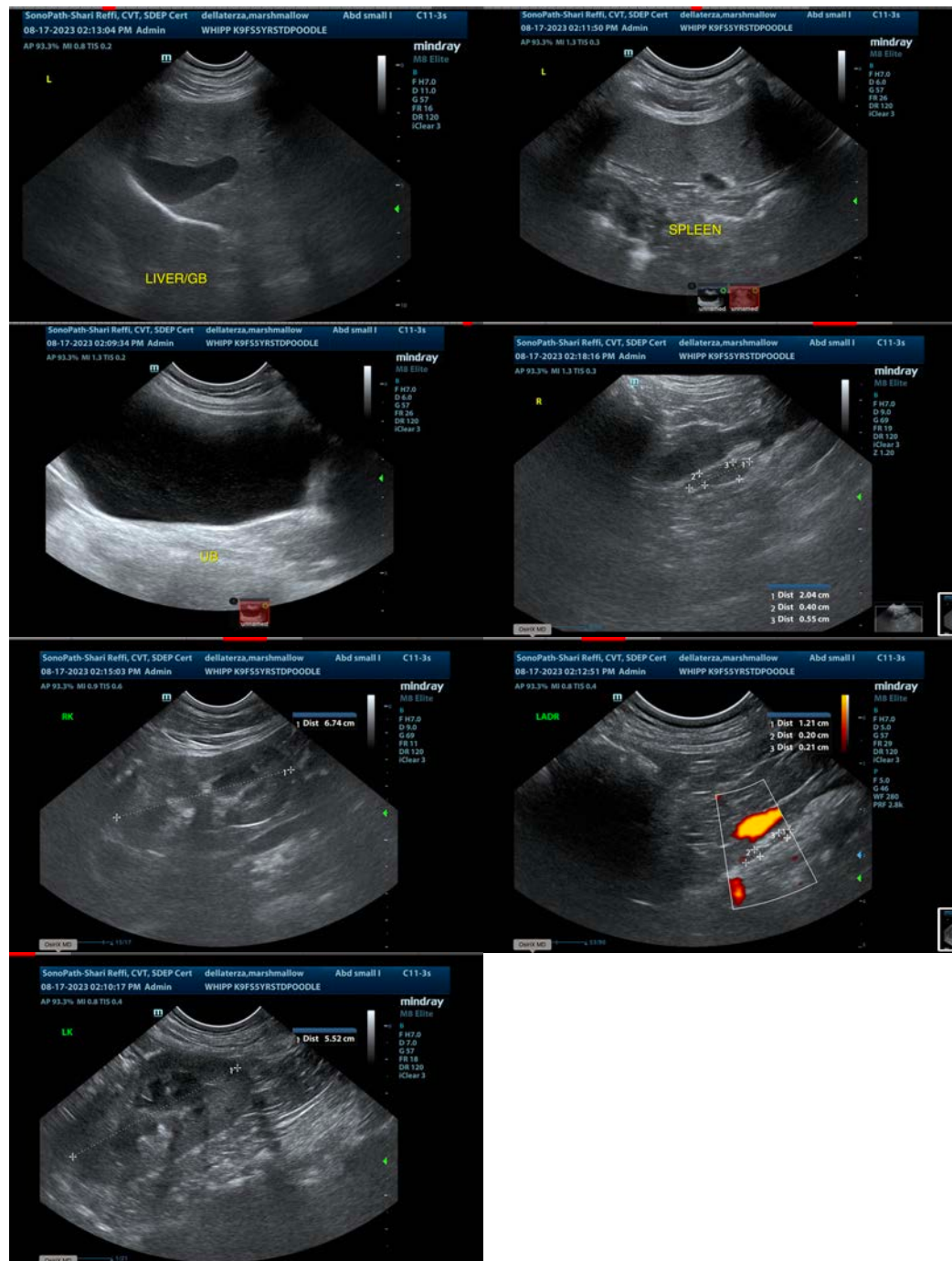
Dr. Van Beveren

**INVOICE**

44778

**DATE**

8/17/23





**PATIENT**

Marshmallow  
Dellaterza

**SPECIES**

Canine

**BREED**

Standard Poodle

**SEX**

Spayed Female

**AGE**

5 Years

**WEIGHT**

52.5 Pounds

**INTERPRETED BY**

Kathleen Sennello DVM,  
MS, Diplomate ACVIM  
(Small Animal Internal  
Medicine)

**IMAGING  
PERFORMED BY**

Shari Reffi, CVT

**HOSPITAL NAME**

Whippany VH

**REFERRING VET**

Dr. Van Beveren

**INVOICE**

44778

**DATE**

8/17/23

The information and recommendations provided are based on the images presented by the referring veterinarian/sonographer. No evaluation can be communicated regarding pathology that was not visible in the image/video clips provided.

Thank you for this referral. If the clinical or image interpretation does not parallel your findings or if I can be of any further assistance please contact me.

Kathleen Sennello DVM,MS, Diplomate ACVIM (Small animal Internal Medicine)

info@sonopath.com