

**PATIENT**

Mittens Kulcher

SPECIES

Feline

BREED

DSH

SEX

Spayed Female

AGE

14 Years

WEIGHT

6 Pounds

INTERPRETED BYKathleen Sennello DVM,
MS, Diplomate ACVIM
(Small Animal Internal
Medicine)**IMAGING
PERFORMED BY**

Amy Mayhew, LVT

HOSPITAL NAME

SVS Imaging MI

REFERRING VETTown Center Vet
Associates**INVOICE**

40558

DATE

8/17/22

PRESENTING CLINICAL SIGNS

Mittens is here for loss of appetite and lethargy. Started about 1-2 weeks ago, they are not sure if she is eating at all because they have another cat at an automatic feeder, but she does not want to eat her treats or any table scraps. She is also very lethargic. O is pretty sure that Mitten's is drinking. No v/c/s/d. Still using the litterbox. She only gets dry food. No medications currently. Other cat at home is acting completely normal.

Abnormal PE/Chem/CBC/UA Results: Abdominal mass. Diagnostics: PE TBF to antech Tx: 150mL SQ LRS Plan: Begin empiric prednisolone and monitor for improvement. We will call with BW results tomorrow and discuss next steps from there. Difficult to chart prognosis without knowing the etiology of the mass. Bloodwork may help us determine origin. Rx: Prednisolone 5mg minimelts - 1/4 T 7 day taper with eod extension

ULTRASONOGRAPHIC EXAMINATION OF THE ABDOMEN**Urinary System**

The urinary bladder is minimally distended with anechoic urine. The Bladder wall, trigone, ureteral papillae and visible urethra (to a depth of 2cm) appear normal with no evidence of wall thickening, mucosal irregularities, masses or cystic calculi. Full evaluation is limited due to lack of urine distention.

The left kidney has a normal shape and size (3.81 cm). Overall echogenicity is normal with adequate corticomedullary distinction and a typical 1:3 cortex:medulla ratio. There is no evidence of perinephric inflammation or effusion. There is no evidence of pyelectasia, nephroliths, infarcts or hydroureter. Renal vasculature is normal.

The right kidney has a normal shape and size (4.39 cm). Overall echogenicity is normal with adequate corticomedullary distinction and a typical 1:3 cortex:medulla ratio. There is no evidence of perinephric inflammation or effusion. There is no evidence of pyelectasia, nephroliths, infarcts or hydroureter. Renal vasculature is normal.

Adrenal Glands

The left adrenal gland is not clearly visualized.

The right adrenal gland is not clearly visualized.

Spleen

The spleen is subjectively normal in size (0.51 cm), echotexture is homogenous, and the splenic capsule is smooth with no irregularities. The blood flow through the hilus and splenic parenchyma appears normal. No focal parenchymal abnormalities are visualized.

Liver

The liver is subjectively normal in size, and echogenicity with smooth peripheral margins. The parenchyma is homogenous echotexture. The visible portions of the vasculature and biliary tract appear normal. There is a hyperechoic nodule visualized within the liver measuring 1.37 cm x 1.2 cm.

The gallbladder lumen is moderately distended. The wall of the gall bladder is not thickened and has a smooth mucosal surface. Luminal contents are primarily anechoic. The cystic and common bile ducts are normal/not visible.

**PATIENT**

Mittens Kulcher

SPECIES

Feline

BREED

DSH

SEX

Spayed Female

AGE

14 Years

WEIGHT

6 Pounds

INTERPRETED BYKathleen Sennello DVM,
MS, Diplomate ACVIM
(Small Animal Internal
Medicine)**IMAGING
PERFORMED BY**

Amy Mayhew, LVT

HOSPITAL NAME

SVS Imaging MI

REFERRING VETTown Center Vet
Associates**INVOICE**

40558

DATE

8/17/22

Gastrointestinal

The stomach contains minimal luminal contents. It measures at a normal thickness of <0.36cm with some variability due to the presence of rugal folds. The distinction of the gastric wall layers is adequate and there is no impression of reduced peristaltic activity. No masses or focal lesions were observed.

The visualized areas of duodenum, jejunum and ileum have a uniform diameter with minimal fluid distension. Wall thickness is normal to slightly increased. Bowel loops follow a typical curvilinear path with distinct wall layering, but some areas display a prominent muscularis layer which does not display the typical 1:3 muscularis:mucosa layer ratio. Jejunum wall measured 0.26 cm. Visualized peristalsis appears appropriate. There is an extensive bowel mass visualized with diameter of the bowel being 2.28 cm and wall thickness of 0.88 cm with a complete loss of layering. This abnormal tissue extends for greater than 6.0 cm of bowel and is surrounded by hyperechoic mesentery, free fluid and lymph nodes.

The ileocecal junction was visualized and exhibited normal intact wall layering and is subjectively of normal thickness. Sections of colon are visualized with formed fecal material and gas shadowing distally. There is no observed focal or generalized colon wall thickening or loss of layering.

Pancreas

The pancreas is large and hypoechoic to surrounding mesentery. There is no evidence of nodules or cystic lesions. There is evidence of regional mesenteric inflammation. Consistent with moderate pancreatitis.

Free Abdomen

There is a small volume of free abdominal fluid. There is a significant mesenteric lymphadenopathy with lymph nodes measuring 0.64 cm and 1.08 cm in diameter. The omentum is diffusely hyperechoic.

ULTRASONOGRAPHIC FINDINGS

- Large, hypoechoic and prominent pancreas surrounded by hyperechoic mesentery – The pancreatic changes are most consistent with moderate pancreatitis/pancreatic inflammation. Recommend fPLI testing and continued monitoring for improvement or possible development of a pancreatic abscess. Consider fine needle aspirate if not improving. This also could be consistent with infiltrative disease of the pancreas.
- Hyperechoic nodule in the liver – This could represent a benign or neoplastic process.
- Severely thickened small intestinal wall with complete loss of layering – consistent with a bowel mass. Likely differentials include round cell neoplasia, carcinoma, etc.
- Small volume free abdominal fluid.
- Mesenteric lymphadenopathy – The moderate mesenteric lymphadenopathy could be consistent with a neoplastic process, although you can see significant lymphadenopathy in some cases of autoimmune/inflammatory disease, infectious disease (tick born disease-such as bartonella, fungal infections, FIP (cats)) etc. A fine needle aspirate with cytology is recommended for further evaluation.

INTERPRETATION OF THE FINDINGS & FURTHER RECOMMENDATIONS

There is an extensive bowel mass visualized with complete loss of layering. This would be very concerning for possible lymphoma or other secondary neoplastic process. Recommend a fine needle aspirate of the bowel wall and an enlarged mesenteric lymph node.

The pancreas is prominent and hypoechoic. This could be consistent with moderate pancreatitis or with

IMAGING PERFORMED BY

SVS Mobile Imaging MI 734-637-7711
svsimagingmi@gmail.com



PATIENT

Mittens Kulcher

infiltrative disease to the pancreas.

Consider three view thoracic radiographs to rule out concurrent thoracic disease/involvement.

SPECIES

Feline

BREED

DSH

SEX

Spayed Female

AGE

14 Years

WEIGHT

6 Pounds

INTERPRETED BY

Kathleen Sennello DVM,
MS, Diplomate ACVIM
(Small Animal Internal
Medicine)

IMAGING PERFORMED BY

Amy Mayhew, LVT

HOSPITAL NAME

SVS Imaging MI

REFERRING VET

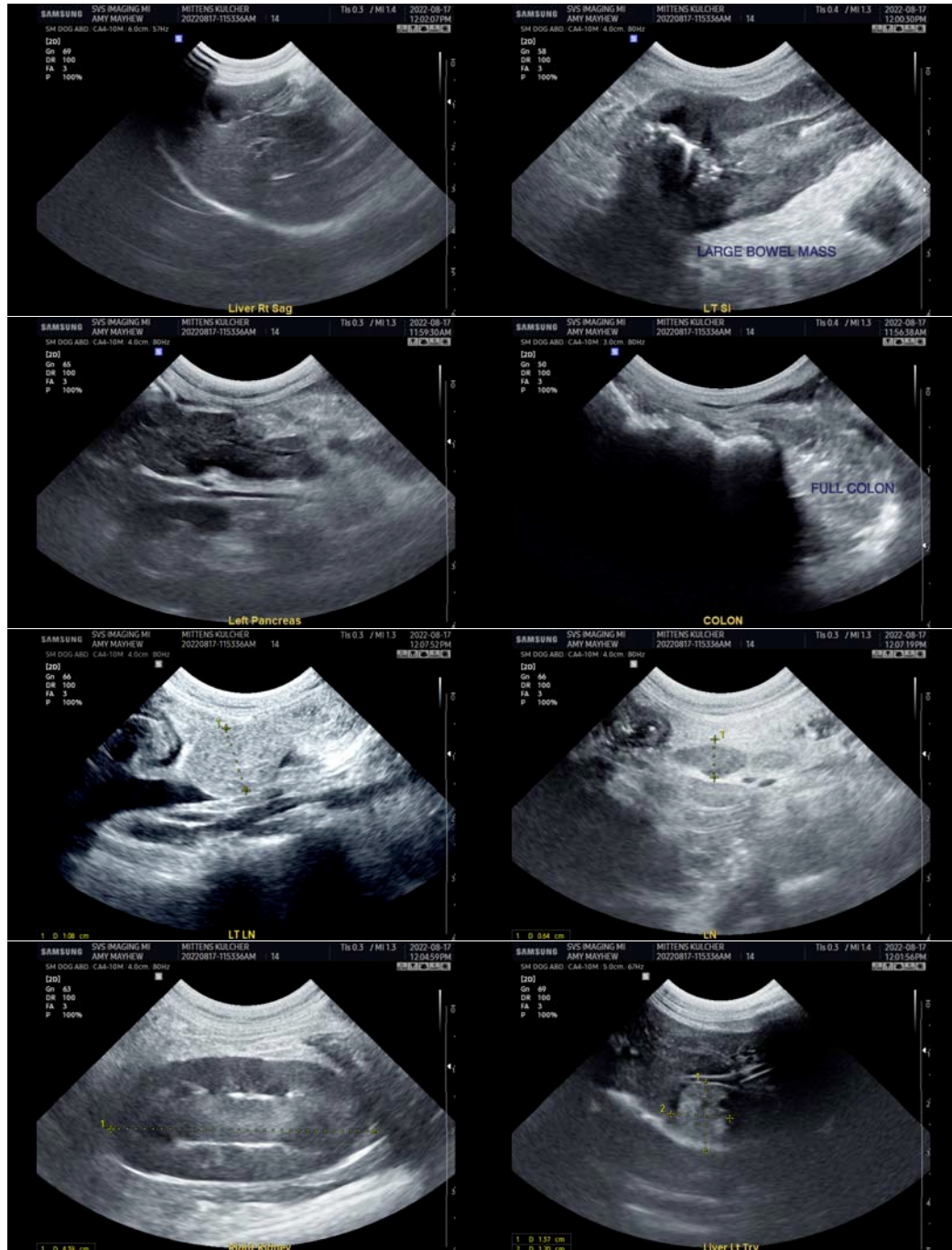
Town Center Vet
Associates

INVOICE

40558

DATE

8/17/22



IMAGING PERFORMED BY

SVS Mobile Imaging MI 734-637-7711
svsimagingmi@gmail.com



PATIENT

Mittens Kulcher

SPECIES

Feline

BREED

DSH

SEX

Spayed Female

AGE

14 Years

WEIGHT

6 Pounds

INTERPRETED BY

Kathleen Sennello DVM,
MS, Diplomate ACVIM
(Small Animal Internal
Medicine)

**IMAGING
PERFORMED BY**

Amy Mayhew, LVT

HOSPITAL NAME

SVS Imaging MI

REFERRING VET

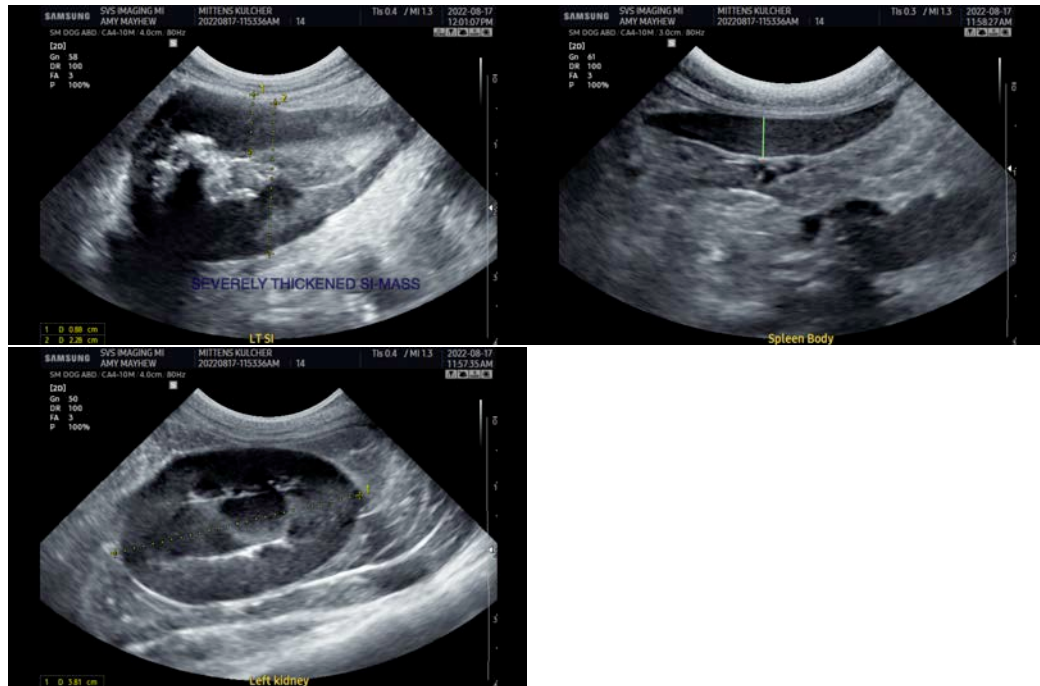
Town Center Vet
Associates

INVOICE

40558

DATE

8/17/22



The information and recommendations provided are based on the images presented by the referring veterinarian/sonographer. No evaluation can be communicated regarding pathology that was not visible in the image/video clips provided.

Thank you for this referral. If the clinical or image interpretation does not parallel your findings or if I can be of any further assistance please contact me.

Kathleen Sennello DVM,MS, Diplomate ACVIM (Small animal Internal Medicine)

kathleen.sennello@sonopath.com