

**PATIENT**

Gracie Leirstein

**SPECIES**

Canine

**BREED**

Mixed

**SEX**

Spayed Female

**AGE**

14 Years

**WEIGHT**

44 Pounds

**INTERPRETED BY**Kathleen Sennello DVM,  
MS, Diplomate ACVIM  
(Small Animal Internal  
Medicine)**IMAGING PERFORMED BY**

Amy Mayhew, LVT

**HOSPITAL NAME**

SVS Imaging MI

**REFERRING VET**Town Center Vet  
Associates**INVOICE**

40554

**DATE**

8/17/22

**PRESENTING CLINICAL SIGNS**

Hasn't been eating well for the past 2 months, but for a few days last week she wasn't eating much at all. Yesterday and today she has eaten both her meals. Her activity level is normal for her, she isn't very active to begin with. P is also pretty anxious at home, she will sit and stare into the corner of the room, also pants and paces a lot. We tried gabapentin in march and O said it didn't make a difference. O thinks she is losing weight and looks bonier than several months ago.

Abnormal PE/Chem/CBC/UA Results: Diagnostics: Lateral thoracic and abdominal- no obvious masses noted Total body function to antech- mildly elevated calcium, malignancy profile submitted and NSF.

**ULTRASONOGRAPHIC EXAMINATION OF THE ABDOMEN****Urinary System**

The urinary bladder is moderately distended with anechoic urine. The Bladder wall, trigone, ureteral papillae and visible urethra (to a depth of 2cm) appear normal with no evidence of wall thickening, mucosal irregularities, masses or cystic calculi.

The left kidney has a normal shape and size (5.97 cm). Overall echogenicity is normal with adequate corticomedullary distinction and a typical 1:3 cortex:medulla ratio. There is no evidence of perinephric inflammation or effusion. There is no evidence of pyelectasia, nephroliths, infarcts or hydroureter. Renal vasculature is normal.

The right kidney has a normal shape and size (6.43 cm). Overall echogenicity is normal with adequate corticomedullary distinction and a typical 1:3 cortex:medulla ratio. There is no evidence of perinephric inflammation or effusion. There is no evidence of pyelectasia, nephroliths, infarcts or hydroureter. Renal vasculature is normal.

**Adrenal Glands**

The left adrenal gland is normal in size measuring 0.55 cm at the caudal pole. It is observed in its normal position cranial to the left renal artery. It is normal in appearance (uniformly hypoechoic) and shape with no evidence of a mass effect.

The right adrenal gland is normal in size measuring 0.67 cm at the caudal pole. It is observed in its normal position between the cranial aspect of the right kidney and the caudal vena cava. It is normal in appearance (uniformly hypoechoic) and shape with no evidence of a mass effect.

**Spleen**

The spleen is subjectively normal in size. The spleen echotexture is heterogenous and mottled, the splenic capsule is smooth with no irregularities. The blood flow through the hilus and splenic parenchyma appears normal. There are numerous very subtle, ill-defined, hypoechoic nodules visualized within the parenchyma measuring 0.65, 0.56, 0.46, and 0.74 cm. These do not appear to deviate the splenic capsule.

**Liver**

The liver is subjectively normal in size, and echogenicity with smooth peripheral margins. The parenchyma is homogenous echotexture. The visible portions of the vasculature and biliary tract appear normal. No focal nodules or cystic lesions are observed.

The gallbladder lumen is moderately distended. The wall of the gall bladder is not thickened and has a smooth mucosal surface. Luminal contents are primarily anechoic. The cystic and common bile ducts are normal/not visible.

**PATIENT**

Gracie Leirstein

**SPECIES**

Canine

**BREED**

Mixed

**SEX**

Spayed Female

**AGE**

14 Years

**WEIGHT**

44 Pounds

**INTERPRETED BY**Kathleen Sennello DVM,  
MS, Diplomate ACVIM  
(Small Animal Internal  
Medicine)**IMAGING  
PERFORMED BY**

Amy Mayhew, LVT

**HOSPITAL NAME**

SVS Imaging MI

**REFERRING VET**Town Center Vet  
Associates**INVOICE**

40554

**DATE**

8/17/22

***Gastrointestinal***

The stomach is moderately dilated with fluid and irregular shadowing material most consistent with normal ingesta and gas. It measures at a normal thickness of <0.7cm with some variability due to the presence of rugal folds. The distinction of the gastric wall layering is adequate and there is no impression of reduced peristaltic activity. No masses or focal lesions were observed.

The visualized areas of duodenum, jejunum and ileum have a uniform diameter with minimal fluid distension. Wall appears subjectively, mildly increased. Bowel loops follow a typical curvilinear path with distinct wall layering. Duodenum wall measured 0.45 cm. Jejunum wall measured 0.37 cm. Visualized peristalsis appears appropriate. There were no focal lesions consistent with obstruction or a mass effect observed.

The ileocecal junction was visualized and exhibited normal intact wall layering and is subjectively of normal thickness. Sections of colon are visualized with formed fecal material and gas shadowing distally. There is no observed focal or generalized colon wall thickening or loss of layering.

***Pancreas***

The pancreas is prominent and mottled compared to the surrounding isoechoic mesentery. There is no evidence of nodules or cystic lesions. There is no evidence of regional mesenteric inflammation or fluid.

***Free Abdomen***

Evaluation of the peritoneal cavity did not reveal any evidence of effusion, or subjective lymphadenomegaly. The Medial iliac nodes appear normal and there was no evidence of a caudal aortic thrombus at the bifurcation. The omentum is of normal uniform echogenicity.

**ULTRASONOGRAPHIC FINDINGS**

- Mottled spleen with subtle hypoechoic nodules – The diffuse splenic changes are non-specific and could be consistent with lymphoid hyperplasia, extramedullary hematopoiesis, infiltrative neoplasia, inflammation, other. Cytology or histopathology would be necessary to get a definitive diagnosis.
- Prominent, mottled pancreas – The pancreatic changes are most consistent with age-related parenchymal remodeling, potentially secondary to a prior inflammatory episode, early fibrosis or chronic pancreatitis.
- Subjectively thickened small intestine – The mild small intestinal wall changes may be a normal variant in this patient or could be consistent with an inflammatory process (e.g., inflammatory bowel disease).

**INTERPRETATION OF THE FINDINGS & FURTHER RECOMMENDATIONS**

The lesions observed on today's scan are relatively mild and subjective. There are very subtle hypoechoic nodules visualized throughout the spleen. These do not appear to deviate the capsule. Recommend a fine needle aspirate of the spleen and a hypoechoic nodule if possible.

The small intestine appears subjectively thickened and prominent. No focal lesions are observed. If metabolic disease is thought likely based on normal lab work, then consider the possibility of primary gastrointestinal disease, and consider a GI panel to Texas A&M for a qualitative PLI, TLI, cobalamin and folate to further evaluate the pancreas and small intestine.

Consider three view thoracic radiographs to rule out concurrent thoracic disease/involvement.

IMAGING PERFORMED BY

SVS Mobile Imaging MI 734-637-7711  
svsimagingmi@gmail.com



**PATIENT**

Gracie Leirstein

**SPECIES**

Canine

**BREED**

Mixed

**SEX**

Spayed Female

**AGE**

14 Years

**WEIGHT**

44 Pounds

**INTERPRETED BY**

Kathleen Sennello DVM,  
MS, Diplomate ACVIM  
(Small Animal Internal  
Medicine)

**IMAGING  
PERFORMED BY**

Amy Mayhew, LVT

**HOSPITAL NAME**

SVS Imaging MI

**REFERRING VET**

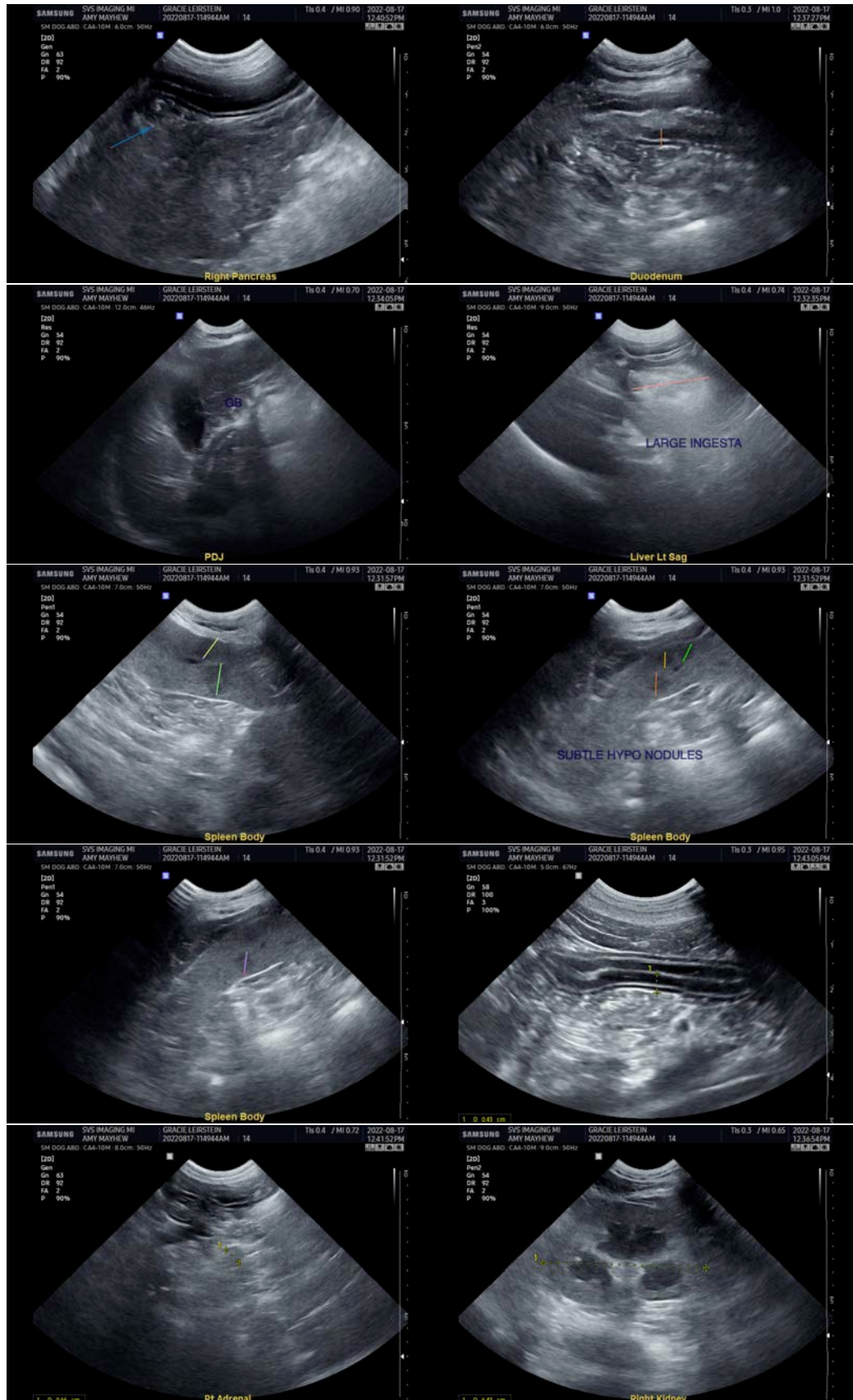
Town Center Vet  
Associates

**INVOICE**

40554

**DATE**

8/17/22



**IMAGING PERFORMED BY**

SVS Mobile Imaging MI 734 - 637 - 7711  
svsimagingmi@gmail.com



EDUCATIONAL TELECONSULTATION SERVICES™  
1-800-838-4268 info@sonopath.com SonoPath.com

**PATIENT**

Gracie Leirstein

**SPECIES**

Canine

**BREED**

Mixed

**SEX**

Spayed Female

**AGE**

14 Years

**WEIGHT**

44 Pounds

**INTERPRETED BY**

Kathleen Sennello DVM,  
MS, Diplomate ACVIM  
(Small Animal Internal  
Medicine)

**IMAGING  
PERFORMED BY**

Amy Mayhew, LVT

**HOSPITAL NAME**

SVS Imaging MI

**REFERRING VET**

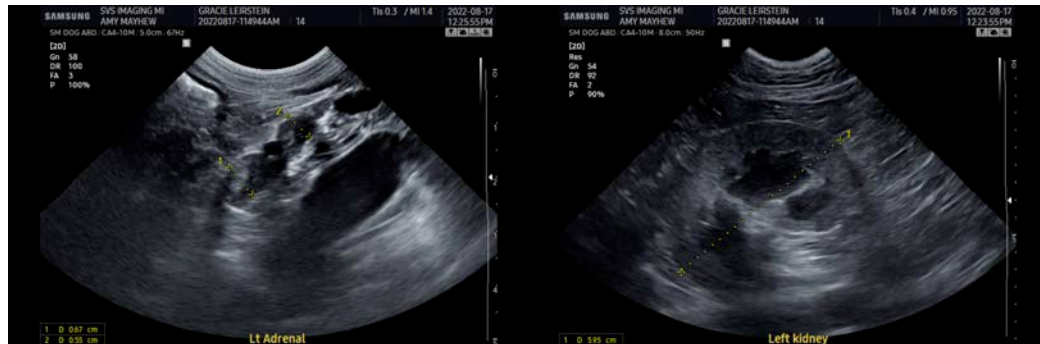
Town Center Vet  
Associates

**INVOICE**

40554

**DATE**

8/17/22



The information and recommendations provided are based on the images presented by the referring veterinarian/sonographer. No evaluation can be communicated regarding pathology that was not visible in the image/video clips provided.

Thank you for this referral. If the clinical or image interpretation does not parallel your findings or if I can be of any further assistance please contact me.

Kathleen Sennello DVM,MS, Diplomate ACVIM (Small animal Internal Medicine)  
kathleen.sennello@sonopath.com