

**DATE PRESENTING CLINICAL SIGNS**

8/17/22 Weight loss from 13.26 to 6.38 over two years. Chronic intermittent vomiting.

PATIENT

Emily Walker

Current Medications: None.
 Lab Results: Albumin 2.7.
 Date of Previous IntraPet Ultrasound: No previous.
 Sedation: Not required to complete full diagnostic ultrasound.
 Stat Report: Not requested.

SPECIES

Feline

ULTRASONOGRAPHIC EXAMINATION OF THE ABDOMEN**BREED**

DLH

Urinary System

The urinary bladder is moderately distended with anechoic urine. The Bladder wall, trigone, ureteral papillae and visible urethra (to a depth of 2cm) appear normal with no evidence of wall thickening, mucosal irregularities, masses or cystic calculi.

SEX

Spayed Female

The left kidney has a normal shape and size (3.22 cm). Overall echogenicity is normal with adequate corticomedullary distinction and a typical 1:3 cortex:medulla ratio. There is no evidence of perinephric inflammation or effusion. There is no evidence of pyelectasia, nephroliths, infarcts or hydroureter. Renal vasculature is normal.

AGE

6/7/10

The right kidney has a normal shape and size (3.45 cm). Overall echogenicity is normal with adequate corticomedullary distinction and a typical 1:3 cortex:medulla ratio. There is no evidence of perinephric inflammation or effusion. There is no evidence of pyelectasia, nephroliths, infarcts or hydroureter. Renal vasculature is normal.

WEIGHT

6.38 Pounds

INTERPRETED BY

Kathleen Sennello DVM,
 MS, Diplomate ACVIM
 (Small Animal Internal
 Medicine)

Adrenal Glands

The left adrenal gland is normal in size measuring 0.49 cm at the caudal pole. It is observed in its normal position cranial to the left renal artery. It is normal in appearance (uniformly hypoechoic) and shape with no evidence of a mass effect. Pinpoint mineralization noted.

The right adrenal gland is normal in size measuring 0.50 cm at the caudal pole. It is observed in its normal position between the cranial aspect of the right kidney and the caudal vena cava. It is normal in appearance (uniformly hypoechoic) and shape with no evidence of a mass effect.

IMAGING PERFORMED BY

Stephanie Warga
 RDCS, RVT

Spleen

The spleen is subjectively normal in size, echotexture is homogenous, and the splenic capsule is smooth with no irregularities. The blood flow through the hilus and splenic parenchyma appears normal. No focal parenchymal abnormalities are visualized.

HOSPITAL NAME

Northwind AH

Liver

The liver is subjectively normal in size, and echogenicity with smooth peripheral margins. The parenchyma is homogenous echotexture. The visible portions of the vasculature and biliary tract appear normal. No focal nodules or cystic lesions are observed.

REFERRING VET

Dr. Miller

The gallbladder lumen is moderately distended. The wall of the gall bladder is not thickened and has a smooth mucosal surface. Luminal contents are primarily anechoic. The bile duct appears somewhat dilated and tortuous, measuring at 0.29 cm. No focal obstruction is observed.

INVOICE

40547

Gastrointestinal

The stomach contains minimal luminal contents. It measures at a normal thickness of <0.36cm with some variability due to the presence of rugal folds. The distinction of the gastric wall layers is adequate and there is no impression of reduced peristaltic activity. No masses or focal lesions were observed.

The visualized areas of duodenum, jejunum and ileum have a uniform diameter with minimal to mild fluid distension. Wall thickness is normal to slightly increased. Bowel loops follow a typical curvilinear path with distinct wall layering, but some areas display a prominent muscularis layer which does not display the typical 1:3 muscularis:mucosa layer ratio. Jejunum wall measured 0.35 cm. Visualized peristalsis appears appropriate. There are some focal sections of bowel that appear more prominent and thickened, and there is a focal area of asymmetric thickening with reduced layering, which measures 0.47 cm. The focal area of thickening measures at 0.80 cm.

The ileocecal junction was visualized and exhibited normal intact wall layering and is subjectively of normal thickness. Sections of colon are visualized with formed fecal material and gas shadowing distally. There is no observed focal or generalized colon wall thickening or loss of layering.

Pancreas

The pancreas is normal and isoechoic to surrounding mesentery. There is no evidence of nodules or cystic lesions. There is no evidence of regional mesenteric inflammation or fluid.

Free Abdomen

There is scant free abdominal fluid. There are significantly enlarged mesenteric lymph nodes with lymph nodes measuring 0.88, 0.44 cm. The omentum is generally hyperechoic.

Other

A brief view of the heart was submitted. No significant pericardial effusion was seen.

ULTRASONOGRAPHIC FINDINGS

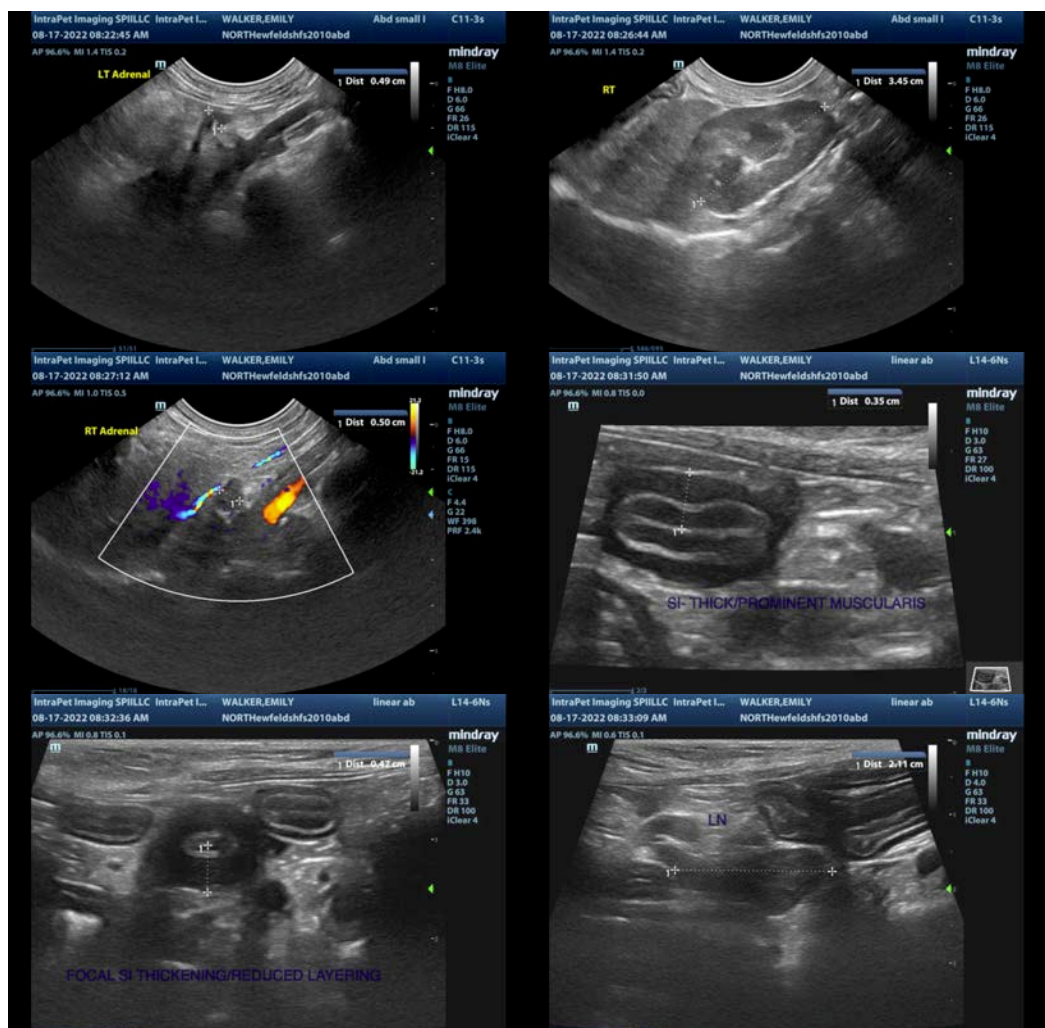
- Diffusely prominent muscularis layer to the small intestine – The small intestinal wall changes are most consistent with an inflammatory process (i.e., inflammatory bowel disease) with a low possibility of emerging lymphoma.
- Focal areas of small intestine with reduced distinction of layering and asymmetrical wall thickening – Findings are concerning for possible infiltrative disease. Recommend a fine needle aspirate (see images).
- Moderate mesenteric lymphadenopathy – The prominent abdominal lymph nodes are most consistent with reactive lymphadenitis or lymphoid hyperplasia. Neoplastic infiltration is considered less likely.
- Scant free abdominal fluid.

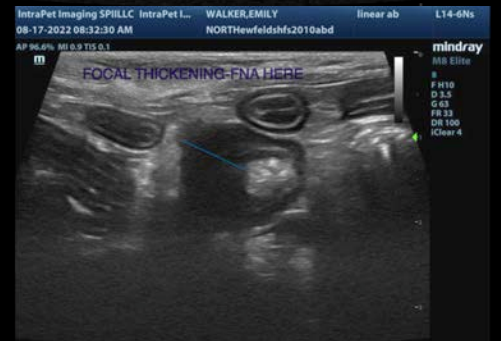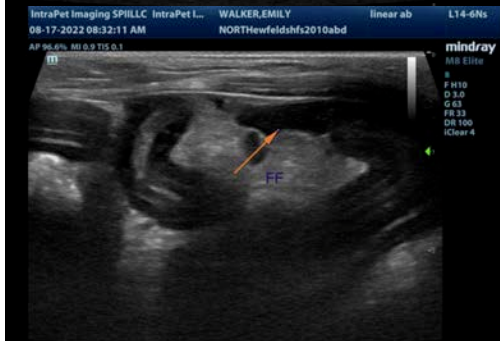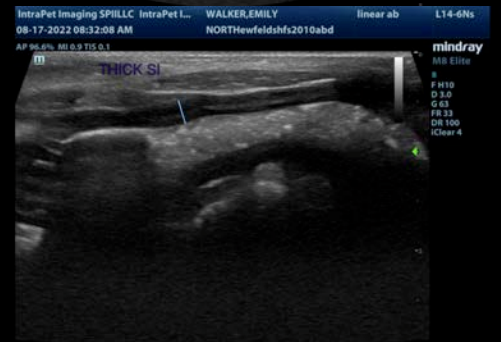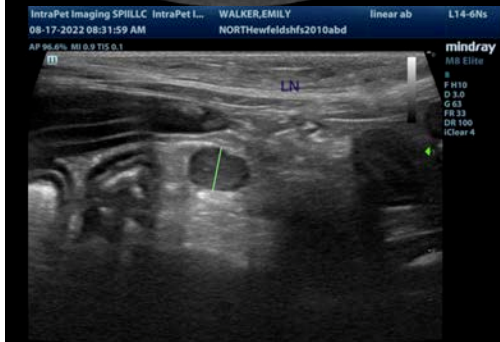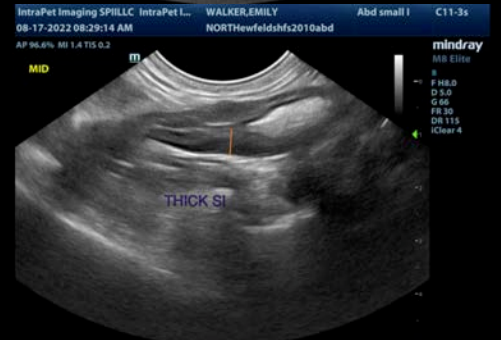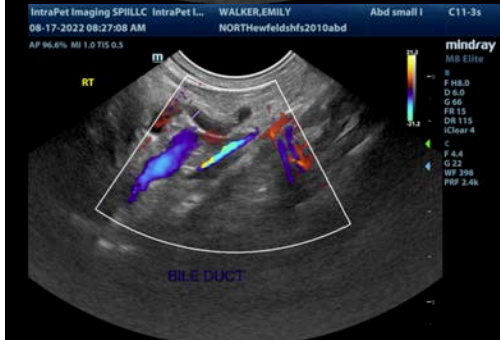
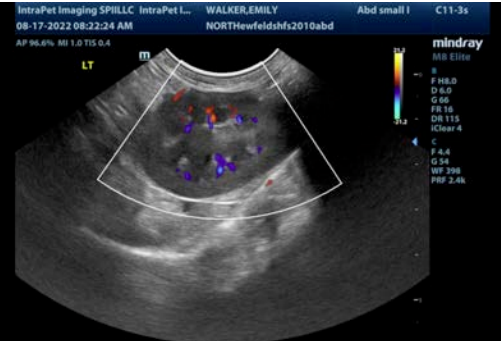
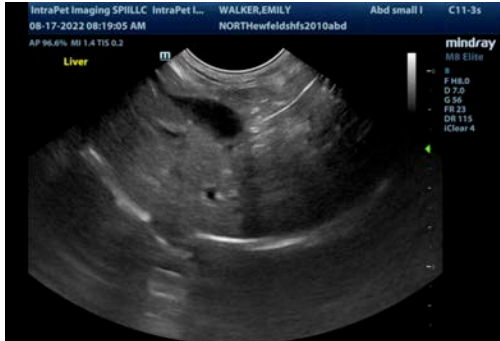
INTERPRETATION OF THE FINDINGS & FURTHER RECOMMENDATIONS

There is the general appearance of “ropey” small intestine with some focal areas with reduced distinction of wall layering and more severe thickening verging on a “mass effect”. Recommend a fine needle aspirate of an enlarged mesenteric lymph node and a section of focal bowel wall thickening. Additionally, consider symptomatic therapy while waiting for cytology results.

- Recommend a novel protein/hydrolyzed protein prescription diet.

- Recommend chronic probiotic therapy.
- Consider a GI panel to Texas A&M for a qualitative fPLI, TLI, cobalamin and folate to determine if additional therapy is necessary.
- If cytology is not diagnostic, consider obtaining GI biopsies (likely surgical).
- Consider three view thoracic radiographs to rule out concurrent thoracic disease/involvement.





The information and recommendations provided are based on the images presented by the referring veterinarian/sonographer. No evaluation can be communicated regarding pathology that was not visible in the image/video clips provided.

Thank you for this referral. If the clinical or image interpretation does not parallel your findings or if I can be of any further assistance please contact me.

Kathleen Sennello DVM,MS, Diplomate ACVIM (Small animal Internal Medicine)
kathleen.sennello@sonopath.com