
**PATIENT PRESENTING CLINICAL SIGNS**

**PATIENT** Daisy Mae Ernst

**SPECIES** Canine

**BREED** Miniature Schnauzer

**SEX** Spayed Female

**AGE** 16 years

**WEIGHT** 17 Pounds

**HISTORY:** Canine Miniature Schnauzer Spayed Female 16.3 17 lb Medication Strength Dosing Instructions Last given Vetmedin 5 mg 1/2 T PO BID Furosemide 12.5 mg 1/2 T PO BID Metronidazole 250 mg 1/2 T PO BID Entyce 30 mg/mL 0.8 mL PO SID PRN Cerenia 16 mg 1 T PO SID PRN Novox 25 mg 1/2 T PO SID, O told to d/c, gave an additional week. 8/15/21 Current Problem List: 2/6 systolic heart murmur - DDx DVD (started on Vetmedin, Enalapril, Lasix by pDVM, no echo) Hx of severe pancreatitis Chronic bronchitis Osteoarthritis Elevated liver values (7/28/21) Low T4: DDx HypoT4 disease vs euthyroid illness (has been on Carprofen chronically) Presenting Complaint: Presented on July 27th 2021 for an examination, O was going to be out of the country for a few weeks and just wanted Daisy Mae evaluated for peace of mind before leaving for trip. She has a history of osteoarthritis and pDVM had her on Novox, O felt that recently she seemed weaker in the hind end. Labwork was submitted and results relayed to Os daughter (as owner had already left the country). She had elevated liver values. Daughter was told to stop the Carprofen and to have Daisy evaluated if clinical signs developed and to have owner follow up with me when she was back in town to discuss next diagnostic steps. Daughter noted that after a few days off the Carprofen her limp became noticeably worse so she restarted the Carprofen. Daisy presented to me on 8/16/21, she has not eaten since 8/11/21. She is not vomiting, but she is anorexic and having diarrhea since 8/15/21. She was dehydrated and possibly has abdominal pain on palpation (grunts on palpation). She has a 2/6 systolic heart murmur. She has severe periodontal disease. Daisy was given 150 mL SQ LRS, Cerenia 1 mg/kg SQ. Daisy was scheduled for an abdominal ultrasound 8/17/21 Daisy was sent home with Metronidazole 15 mg/kg PO BID x7d, Cerenia 2 mg/kg PO SID PRN to start tomorrow, Entyce 3 mg/kg PO SID PRN, Hill's i/d LF can diet Pertinent Diagnostic Results: Labwork 7/28/21: Senior Basic CHEM - BUN 37(H) - Ca 11.8 - K 6.4 H - TP 7.8 - GLOB 4.1 - ALT 478 - AST 57 - ALP 906 - GGt 19 - CHOL 822 T4 <0.5 CBC PLTs 630

**ULTRASONOGRAPHIC EXAMINATION OF THE ABDOMEN**
**Urinary System**

The urinary bladder is moderately distended with anechoic urine. The bladder wall, trigone, ureteral papillae and visible urethra (to a depth of 2cm) appear normal with no evidence of wall thickening, mucosal irregularities, masses or cystic calculi.

The left kidney has a normal shape and size (4.5 cm). Overall echogenicity is slightly hyperechoic with poor corticomedullary distinction and a typical 1:3 cortex:medulla ratio. There is no evidence of perinephric inflammation or effusion. Pinpoint, non-obstructive nephroliths were noted. There is no evidence of pyelectasia, infarcts or hydroureter. Renal vasculature is normal.

The right kidney has a normal shape and size (4.5 cm). Overall echogenicity is slightly hyperechoic with poor corticomedullary distinction and a typical 1:3 cortex:medulla ratio. There is no evidence of perinephric inflammation or effusion. Non-obstructive, pinpoint nephroliths were noted at. Non-obstructive nephroliths were noted. There is no evidence of pyelectasia, infarcts or hydroureter. Renal vasculature is normal.

**INTERPRETED BY**

Kathleen Sennello DVM,  
 MS, Diplomate ACVIM  
 (Small Animal Internal  
 Medicine)

**IMAGING PERFORMED BY**

Loetitia Saint-Jacques, RVT

**HOSPITAL NAME**

Donner Truckee VH

**REFERRING VET**

Dr. Kuester

**INVOICE**

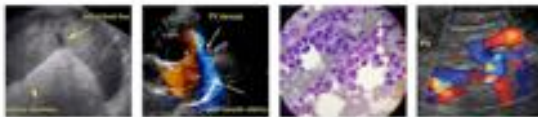
91317

**DATE**

8/17/21

**Adrenal Glands**

The left adrenal gland is large in size measuring 0.72 cm at the cranial pole and 0.99 cm at the caudal pole. It is observed in its normal position cranial to the left renal artery. It is normal in appearance (uniformly hypoechoic), but irregular in shape with a large, irregular, hypoechoic caudal pole and a lack of color flow observed in the phrenicoabdominal vein, which causes concern for possible early invasion.



**PATIENT**

Daisy Mae Ernst

The right adrenal gland is normal in size measuring 0.58 cm at the caudal pole It is observed in its normal position between the cranial aspect of the right kidney and the caudal vena cava. It is normal in appearance (uniformly hypoechoic) and shape with no evidence of a mass effect.

**SPECIES**

Canine

**Spleen**

The spleen is subjectively normal in size, echotexture is homogenous, and the splenic capsule is smooth with no irregularities. The blood flow through the hilus and splenic parenchyma appears normal. No focal parenchymal abnormalities are visualized.

**BREED**

Minature Schnauzer

**Liver**

**SEX**

Spayed Female

The liver is subjectively normal in size, and echogenicity with smooth peripheral margins. The parenchyma is heterogenous in echotexture with subtle, indistinct focal mottling. The visible portions of the vasculature and biliary tract appear normal. There is a 0.5 cm hepatic cyst visualized. The gallbladder lumen is moderately distended with echogenic debris that appears to be starting to organize into the characteristics of an early mucocele. The wall of the gallbladder is relatively normal and there is no surrounding inflammation. The bile duct is prominent and moderately dilated and tortuous measuring 0.47 cm.

**AGE**

16 years

**WEIGHT**

17 Pounds

**Gastrointestinal**

The stomach contains minimal luminal contents. It measures at a normal thickness of <0.7cm with some variability due to the presence of rugal folds. The distinction of the gastric wall layers is adequate and there is no impression of reduced peristaltic activity. No masses or focal lesions were observed.

**INTERPRETED BY**

Kathleen Sennello DVM,  
MS, Diplomate ACVIM  
(Small Animal Internal  
Medicine)

The visualized areas of duodenum, jejunum and ileum have a relatively uniform diameter with minimal fluid distension. Wall thickness is normal. Bowel loops follow a curvilinear path with distinct wall layering maintaining the typical 1:3 muscularis:mucosa layer ratio. The duodenum measured as normal (between 0.3-0.5cm in wall thickness) and the jejunum measured as normal (between 0.2-0.47cm.)

**IMAGING PERFORMED BY**

Loetitia Saint-Jacques, RVT

Visualized peristalsis appears appropriate. There were no focal lesions consistent with obstruction or a mass effect observed.

**HOSPITAL NAME**

Donner Truckee VH

The ileocecal junction was visualized and exhibited normal intact wall layering and is subjectively of normal thickness. Sections of colon are visualized with formed fecal material and gas shadowing distally. There is no observed focal or generalized colon wall thickening or loss of layering.

**REFERRING VET**

Dr. Kuester

**Pancreas**

The pancreas is prominent and mottled compared to the surrounding isoechoic mesentery. There is no evidence of nodules or cystic lesions. There is no evidence of regional mesenteric inflammation or fluid.

**INVOICE**

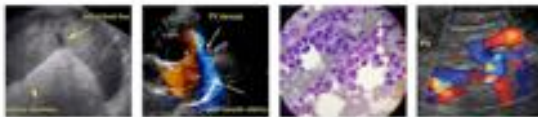
91317

**Free Abdomen**

**DATE**

8/17/21

Evaluation of the peritoneal cavity did not reveal any evidence of effusion, or subjective lymphadenomegally. The Medial iliac nodes appear normal and there was no evidence of a caudal aortic thrombus at the bifurcation. The omentum is of normal uniform echogenicity.



**PATIENT**      **ULTRASONOGRAPHIC FINDINGS**

Daisy Mae Ernst

**PRIMARY FINDINGS:**

**SPECIES**

Canine

**BREED**

Minature Schnauzer

**SEX**

Spayed Female

**AGE**

16 years

**WEIGHT**

17 Pounds

- Enlarged left adrenal gland, most consistent with a left adrenal mass. There is concern for possible phrenicoabdominal vein invasion. Unilateral adrenomegaly could be consistent with neoplasia (e.g., adenoma, carcinoma, pheochromocytoma), hyperplasia, inflammation, other.
- Mottled irregular pancreas. The pancreatic changes are most consistent with mild pancreatitis or a recent episode of pancreatic inflammation.
- Heterogenous liver with small, anechoic cyst. The diffuse hepatic changes are non-specific and could be consistent with vacuolar hepatopathy, nodular hyperplasia, inflammatory/immune-mediated disease, fibrosis, extramedullary hematopoiesis, toxic hepatopathy (e.g., copper), infiltrative neoplasia (less likely) or other hepatopathy.
- Early gallbladder mucocele with mild bile duct dilation. Correlate this finding with recent blood work. I see no focal inflammation around the gallbladder to indicate a crisis, but it should be closely monitored.
- Decreased corticomedullary distinction in both kidneys with non-obstructive, pinpoint nephroliths. Mild loss of corticomedullary distinction in both kidneys could be consistent with chronic degenerative disease or interstitial nephrosis.

**INTERPRETATION OF THE FINDINGS & FURTHER RECOMMENDATIONS**

**INTERPRETED BY**

Kathleen Sennello DVM,  
MS, Diplomate ACVIM  
(Small Animal Internal  
Medicine)

Current blood work will be helpful in this case due to the number of medications that the patient is on and possible complications with dehydration, etc. There is an early mucocele present, but I do not see any evidence of localized inflammation. Therefore, it is difficult to determine if this is the cause for the abdominal discomfort described. Consider quantitative PLI measurement to get more information on the pancreatic changes observed.

**IMAGING PERFORMED BY**

Loetitia Saint-Jacques, RVT

The kidneys have changes consistent with chronic, age related change and progressive disease. Current lab values will evaluate for azotemia, acute on chronic renal failure or electrolyte disturbances.

**HOSPITAL NAME**

Donner Truckee VH

I recommend continued supportive care. If the patient is not currently on Ursodiol consider starting this in addition to Denamarin and a broad spectrum antibiotic. Close monitoring of gallbladder, renal and liver values is recommended.

**REFERRING VET**

Dr. Kuester

The left adrenal gland is very irregular. This can be consistent with a benign or a malignant lesion, but there is concern about possible lack of blood flow through the phrenicoabdominal vein. Options moving forward regarding this issue include:

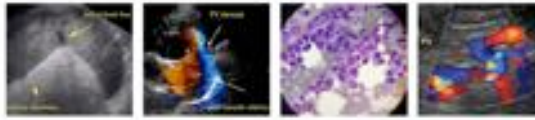
- Blood pressure evaluation.
- Possible adrenal function testing if the patient starts to feel better.
- Evaluation for possible surgery, likely including pre-operative CT to help with surgical planning.
- Three view thoracic radiographs are recommended.

**INVOICE**

91317

**DATE**

8/17/21



**PATIENT**

Daisy Mae Ernst

**SPECIES**

Canine

**BREED**

Miniature Schnauzer

**SEX**

Spayed Female

**AGE**

16 years

**WEIGHT**

17 Pounds

**INTERPRETED BY**

Kathleen Sennello DVM,  
MS, Diplomate ACVIM  
(Small Animal Internal  
Medicine)

**IMAGING PERFORMED BY**

Loetitia Saint-Jacques, RVT

**HOSPITAL NAME**

Donner Truckee VH

**REFERRING VET**

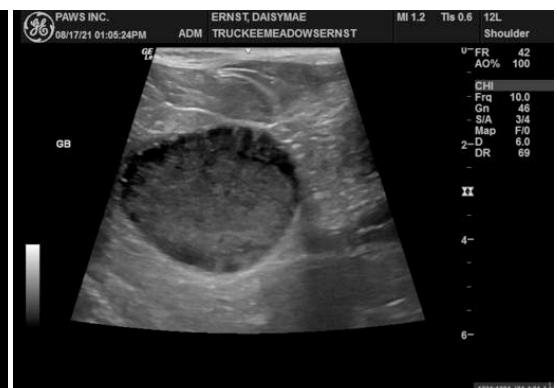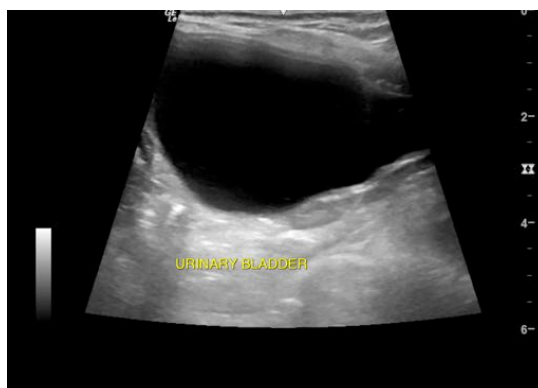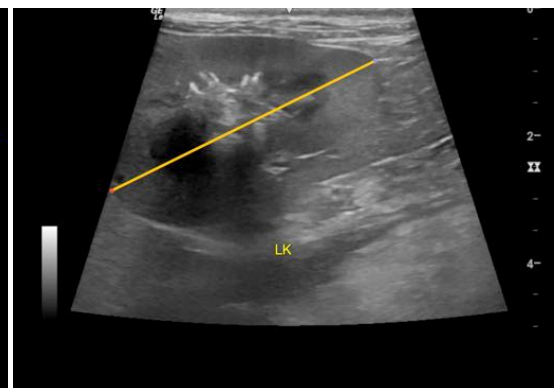
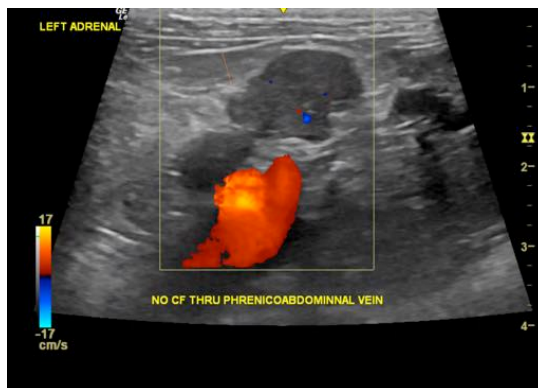
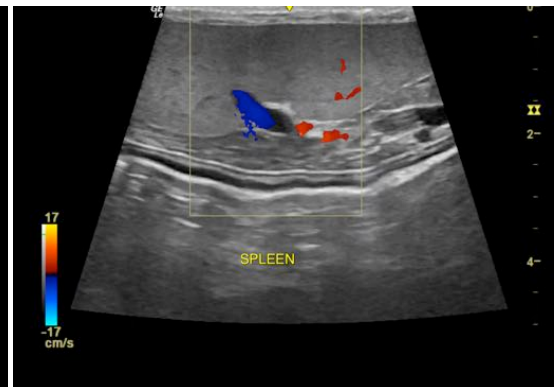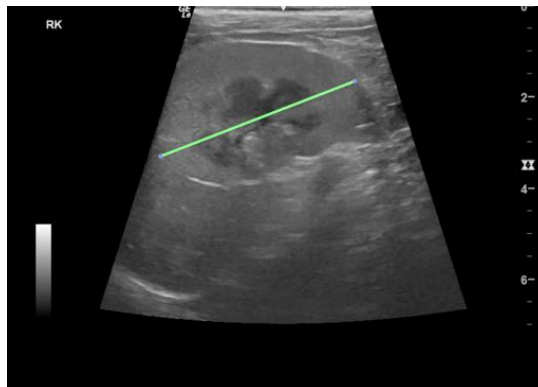
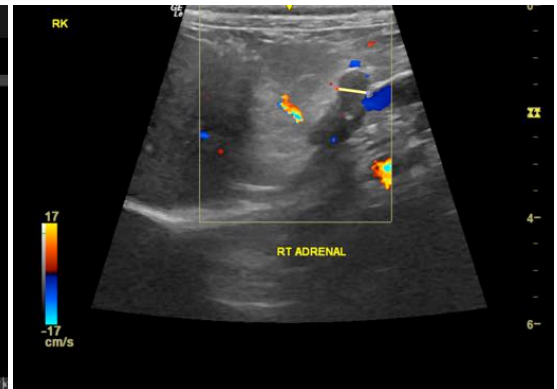
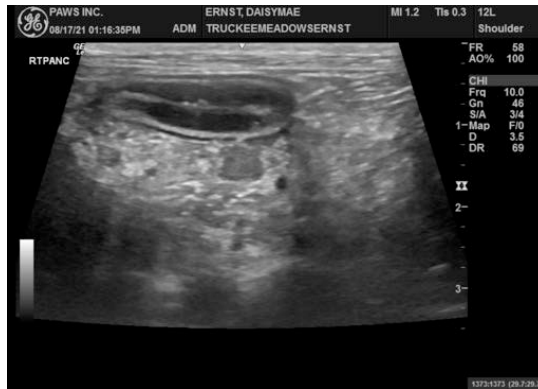Dr. Kuester

**INVOICE**

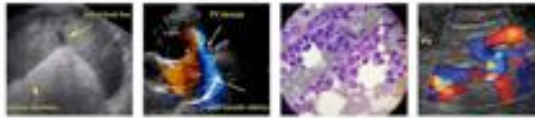
91317

**DATE**

8/17/21



The information and recommendations provided are based on the images presented by the referring



**PATIENT**

Daisy Mae Ernst

veterinarian. No evaluation can be communicated regarding pathology that was not visible in the image/video clips provided.

Thank you for this referral. If the clinical or image interpretation does not parallel your findings or if I can be of any further assistance please contact me.

**SPECIES**

Canine

Kathleen Sennello DVM,MS, Diplomate ACVIM (Small animal Internal Medicine)

**BREED**

Minaiture Schnauzer

kathleen.sennello@sonopath.com

**SEX**

Spayed Female

**AGE**

16 years

**WEIGHT**

17 Pounds

**INTERPRETED BY**

Kathleen Sennello DVM,  
MS, Diplomate ACVIM  
(Small Animal Internal  
Medicine)

**IMAGING PERFORMED  
BY**

Loetitia Saint-Jacques, RVT

**HOSPITAL NAME**

Donner Truckee VH

**REFERRING VET**

Dr. Kuester

**INVOICE**

91317

**DATE**

8/17/21