



PATIENT PRESENTING CLINICAL SIGNS

Maddie Macniven

1. skin infection- treating with chlorhex and viaderm- is getting better 2. cardiomegaly (mild) with mild increase probnp 3. splenic mass 4. lumbar spondylosis 5. suspect c5/6 and T1/2 IVDD or dehydrated discs 6. mild stifle DJD mild on left, mild/mod on right 7. left med patellar luxation, suspect right also 8, bone cyst right and left tibias 9. intertarsal DJD bilaterally 10. lipomas

SPECIES

Canine

BREED

Cairn Terrier

Abnormal PE/Chem/CBC/UA Results: Cardiopet BNP 253 (N 0-900), Prev 309, 576 CBC and Chem Normal. SDMA and TT4 Normal

ULTRASONOGRAPHIC EXAMINATION OF THE ABDOMEN

SEX *Urinary System*

Spayed Female

The urinary bladder is moderately distended with anechoic urine. The Bladder wall, trigone, ureteral papillae and visible urethra (to a depth of 2cm) appear normal with no evidence of wall thickening, mucosal irregularities, masses or cystic calculi.

AGE

11 Years

The left kidney has a normal shape and size (5.03 cm). Overall echogenicity is normal with adequate corticomedullary distinction and a typical 1:3 cortex:medulla ratio. There is no evidence of focal perinephric inflammation or effusion. There is no evidence of pyelectasia, nephroliths, infarcts or hydroureter. Renal vasculature is normal.

WEIGHT

10.85 kg

The right kidney has a normal shape and size (4.97 cm). Overall echogenicity is normal with adequate corticomedullary distinction and a typical 1:3 cortex:medulla ratio. There is no evidence of focal perinephric inflammation or effusion. There is no evidence of pyelectasia, nephroliths, infarcts or hydroureter. Renal vasculature is normal.

INTERPRETED BY

Kathleen Sennello DVM,
MS, Diplomate ACVIM
(Small Animal Internal
Medicine)

Adrenal Glands

IMAGING PERFORMED BY

Dr. Brian Barnes

The left adrenal gland is normal in size measuring 0.37 cm at the caudal pole. It is observed in its normal position cranial to the left renal artery. It is normal in appearance (uniformly hypoechoic) and shape with no evidence of a mass effect.

HOSPITAL NAME

Westview Vet Hospital

The right adrenal gland is normal in size measuring 0.35 cm at the caudal pole. It is observed in its normal position between the cranial aspect of the right kidney and the caudal vena cava. It is normal in appearance (uniformly hypoechoic) and shape with no evidence of a mass effect.

REFERRING VET

Dr. Brian Barnes

Spleen

The spleen is large and irregular in shape. The blood flow through the hilus and splenic parenchyma appears normal. There is an isoechoic to slightly hyperechoic solid homogeneous mass effect visualized towards the caudal aspect of the spleen, measuring 5.19 cm x 3.53 cm. **See additional info under other.

INVOICE

44731

Liver

DATE

8/16/23

The liver is subjectively normal in size, and echogenicity with smooth peripheral margins. The parenchyma is homogenous echotexture. The visible portions of the vasculature and biliary tract appear normal. No focal nodules or cystic lesions are observed.



PATIENT

Maddie Macniven

The gall bladder lumen is moderately distended. The wall of the gall bladder has irregular polypoid projections and there is a moderate amount of non-organized echogenic debris. The cystic and common bile ducts are normal/not visible.

SPECIES

Canine

Gastrointestinal

The stomach contains minimal luminal contents. It measures at a normal thickness of <0.7cm with some variability due to the presence of rugal folds. The distinction of the gastric wall layers is adequate and there is no impression of reduced peristaltic activity. No masses or focal lesions were observed.

BREED

Cairn Terrier

The visualized areas of duodenum, jejunum and ileum have a relatively uniform diameter with minimal fluid distension. Wall thickness is normal. Bowel loops follow a curvilinear path with distinct wall layering maintaining the typical 1:3 muscularis:mucosa layer ratio. The duodenum measured as normal (between 0.3-0.5cm in wall thickness) and the jejunum measured as normal (between 0.2-0.47cm.)

SEX

Spayed Female

Visualized peristalsis appears appropriate. There were no focal lesions consistent with obstruction or a mass effect observed.

AGE

11 Years

The ileocecal junction was visualized and exhibited normal intact wall layering and is subjectively of normal thickness. Sections of colon are visualized with formed fecal material and gas shadowing distally. There is no observed focal or generalized colon wall thickening or loss of layering.

WEIGHT

10.85 kg

Pancreas

The area of the pancreas is normal and isoechoic to surrounding mesentery. There is no evidence of nodules or cystic lesions. There is no evidence of regional mesenteric inflammation or fluid.

INTERPRETED BY

Kathleen Sennello DVM,
MS, Diplomate ACVIM
(Small Animal Internal
Medicine)

Free Abdomen

Evaluation of the peritoneal cavity did not reveal any evidence of effusion, or subjective lymphadenomegaly. The Medial iliac nodes appear normal and there was no evidence of a caudal aortic thrombus at the bifurcation. The omentum is of normal uniform echogenicity.

IMAGING PERFORMED BY

Dr. Brian Barnes

Other

There is an isoechoic, poorly defined mass effect visualized situated between the liver and spleen, measuring 2.49 cm x 3.58 cm. I suspect this could represent a lipoma or irregularity of falciform fat, but a primary hepatic or splenic mass lesion cannot be ruled out.

HOSPITAL NAME

Westview Vet Hospital

ULTRASONOGRAPHIC FINDINGS

REFERRING VET

Dr. Brian Barnes

- Large, solid iso- to slightly hyperechoic splenic mass – A focal solid mixed echogenicity mass is visualized associate with the spleen. This mass distorts the splenic capsule. Differentials include: benign lesions (lymphoid hyperplasia, hemangioma etc..) or cancerous lesions (hemangiosarcoma, lymphoma, histiocytic sarcoma etc..)

INVOICE

44731

- Moderate gallbladder debris with gallbladder polyps – The significance of the gall bladder polyps and debris is unclear. This could represent an early mucocele, cholestasis, or chronic inflammation, or could be an incidental finding.

DATE

8/16/23

- Isoechoic mass effect visualized between the liver and spleen – A fatty mass lesion is suspected, but a primary hepatic or splenic mass cannot be ruled out. Recommend a fine needle aspirate.



PATIENT

Maddie Macniven

SPECIES

Canine

BREED

Cairn Terrier

SEX

Spayed Female

AGE

11 Years

WEIGHT

10.85 kg

INTERPRETED BY

Kathleen Sennello DVM,
MS, Diplomate ACVIM
(Small Animal Internal
Medicine)

IMAGING PERFORMED BY

Dr. Brian Barnes

HOSPITAL NAME

Westview Vet Hospital

REFERRING VET

Dr. Brian Barnes

INVOICE

44731

DATE

8/16/23

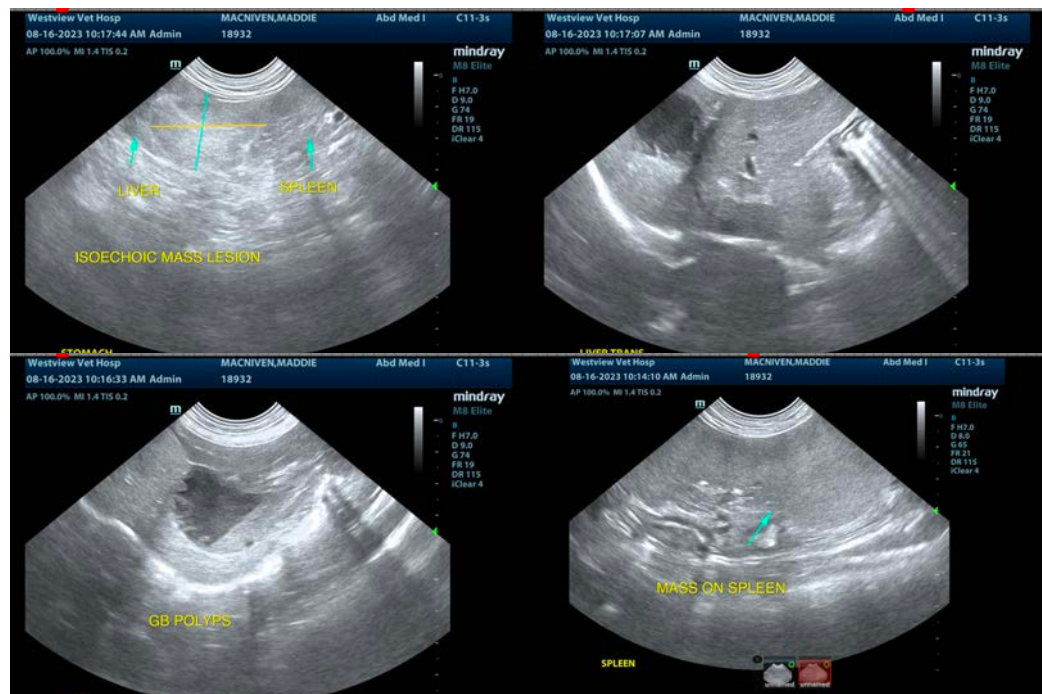
INTERPRETATION OF THE FINDINGS & FURTHER RECOMMENDATIONS

There is a large solid mass effect visualized associated with the spleen. This could represent a benign or neoplastic process. Consider a splenectomy for both diagnostic and therapeutic purposes. Alternately, a fine needle aspirate could be considered, but a risk for rupture can persist despite this being a benign or neoplastic lesion.

Additionally, there is an ill-defined isoechoic mass effect visualized between the liver and spleen in some images. This is poorly defined, and it is difficult to associate it directly with the liver or the spleen. This could represent a lipoma or irregular appearance of falciform fat, but I cannot rule out the possibility of a hepatic or splenic lesion. Consider a fine needle aspirate of this tissue, as it is superficial and ventral.

There is moderate gallbladder debris present with gallbladder polyps. There is minimal surrounding inflammation, and this could be incidental at this time, but this could be an indicator of underlying cholecystitis/inflammation. Consider Ursodiol therapy +/- a course of antibiotics (with concurrent probiotics). Continued monitoring of the liver enzymes and the gallbladder is warranted.

Recommend three view thoracic radiographs to evaluate for possible concurrent thoracic disease/involvement.





PATIENT

Maddie Macniven

SPECIES

Canine

BREED

Cairn Terrier

SEX

Spayed Female

AGE

11 Years

WEIGHT

10.85 kg

INTERPRETED BY

Kathleen Sennello DVM,
MS, Diplomate ACVIM
(Small Animal Internal
Medicine)

IMAGING PERFORMED BY

Dr. Brian Barnes

HOSPITAL NAME

Westview Vet Hospital

REFERRING VET

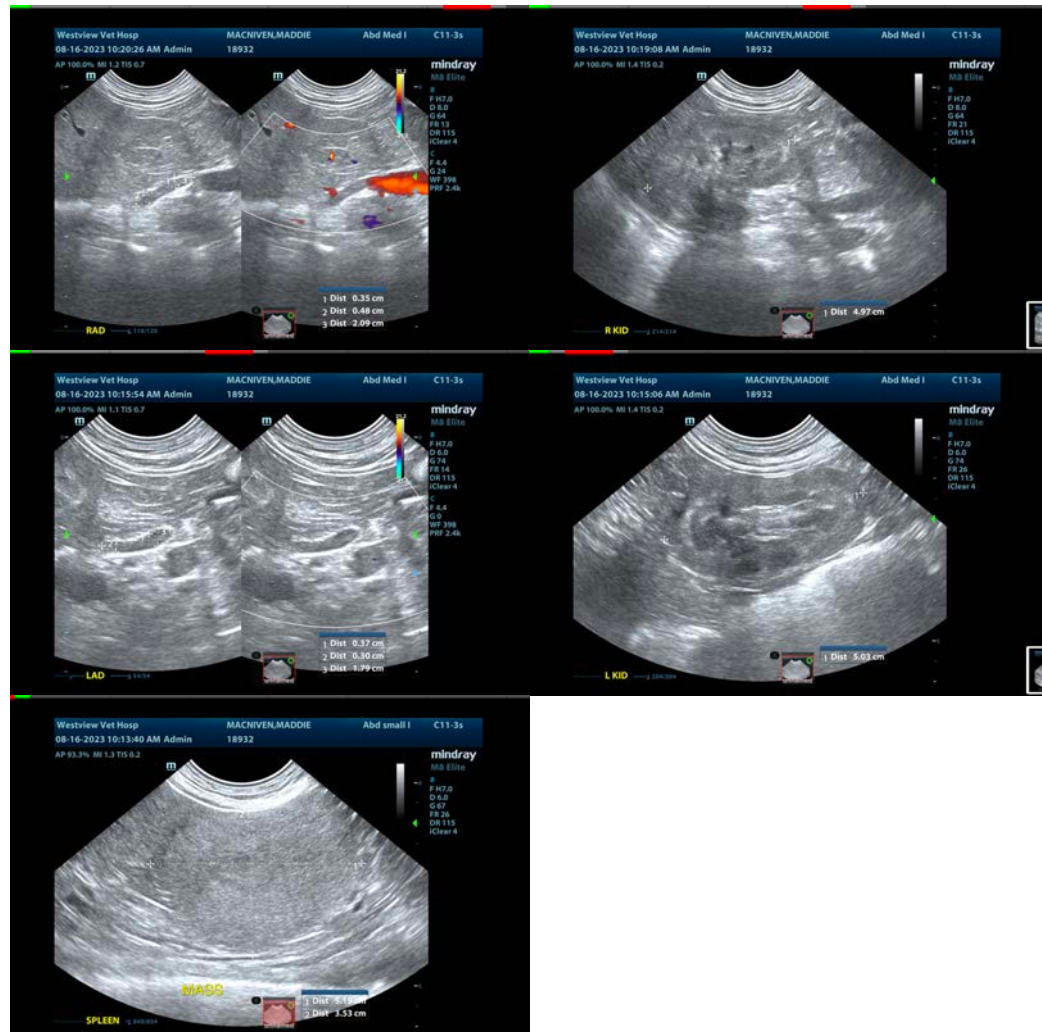
Dr. Brian Barnes

INVOICE

44731

DATE

8/16/23



The information and recommendations provided are based on the images presented by the referring veterinarian/sonographer. No evaluation can be communicated regarding pathology that was not visible in the image/video clips provided.

Thank you for this referral. If the clinical or image interpretation does not parallel your findings or if I can be of any further assistance please contact me.

Kathleen Sennello DVM,MS, Diplomate ACVIM (Small animal Internal Medicine)

info@sonopath.com