



PATIENT PRESENTING CLINICAL SIGNS

Dwayne Dalton Chronic vomiting past few weeks, eating slightly less.

SPECIES ULTRASONOGRAPHIC EXAMINATION OF THE ABDOMEN

Feline

Urinary System

BREED

DSH

The urinary bladder is moderately distended with anechoic urine. The Bladder wall, trigone, ureteral papillae and visible urethra (to a depth of 2cm) appear normal with no evidence of wall thickening, mucosal irregularities, masses or cystic calculi.

SEX

Neutered Male

The left kidney has a normal shape and size (3.86 cm). Overall echogenicity is normal with adequate corticomedullary distinction and a typical 1:3 cortex:medulla ratio. There is no evidence of focal perinephric inflammation or effusion. There is no evidence of pyelectasia, nephroliths, infarcts or hydroureter. Renal vasculature is normal.

AGE

1 Year

The right kidney has a normal shape and size (4.21 cm). Overall echogenicity is normal with adequate corticomedullary distinction and a typical 1:3 cortex:medulla ratio. There is no evidence of focal perinephric inflammation or effusion. There is no evidence of pyelectasia, nephroliths, infarcts or hydroureter. Renal vasculature is normal.

WEIGHT

5.36 kg

Adrenal Glands

INTERPRETED BY

Kathleen Sennello DVM,
MS, Diplomate ACVIM
(Small Animal Internal
Medicine)

The left adrenal gland is normal in size measuring 0.29 cm at the caudal pole. It is observed in its normal position cranial to the left renal artery. It is normal in appearance (uniformly hypoechoic) and shape with no evidence of a mass effect.

The right adrenal gland is normal in size measuring 0.41 cm at the caudal pole. It is observed in its normal position between the cranial aspect of the right kidney and the caudal vena cava. It is normal in appearance (uniformly hypoechoic) and shape with no evidence of a mass effect.

IMAGING PERFORMED BY

Kelly Reschny

Spleen

The spleen is borderline large (1.1 cm) The spleen echotexture is heterogenous and mildly mottled, the splenic capsule is smooth with no irregularities. The blood flow through the hilus and splenic parenchyma appears normal. No focal parenchymal abnormalities are visualized.

HOSPITAL NAME

BPH East Hamilton

Liver

The liver is subjectively normal in size, and echogenicity with smooth peripheral margins. The parenchyma is homogenous echotexture. The visible portions of the vasculature and biliary tract appear normal. No focal nodules or cystic lesions are observed.

REFERRING VET

Dr. Elzaabalawy

INVOICE

44734

The gallbladder lumen is moderately distended. The wall of the gall bladder is not thickened and has a smooth mucosal surface. Luminal contents are mild and primarily anechoic. The cystic and common bile ducts are normal/not visible.

DATE

8/16/23



PATIENT

Gastrointestinal

Dwayne Dalton

The stomach contains minimal luminal contents. It measures at a normal thickness of <0.36cm with some variability due to the presence of rugal folds. The distinction of the gastric wall layers is adequate and there is no impression of reduced peristaltic activity. No masses or focal lesions were observed.

SPECIES

Feline

The visualized areas of duodenum, jejunum and ileum have a uniform diameter with minimal fluid distension. Wall thickness is normal to slightly increased. Bowel loops follow a typical curvilinear path with distinct wall layering, but some areas display a prominent muscularis layer which does not display the typical 1:3 muscularis:mucosa layer ratio. Jejunum wall varies from 0.26-0.32 cm. Duodenum wall measures 0.26 cm. Visualized peristalsis appears appropriate. There were no focal lesions consistent with obstruction or a mass effect observed.

BREED

DSH

SEX

Neutered Male

The ileocecal junction was visualized and exhibited normal intact wall layering and is subjectively of normal thickness. Sections of colon are visualized with formed fecal material and gas shadowing distally. There is no observed focal or generalized colon wall thickening or loss of layering.

AGE

1 Year

Pancreas

The area of the pancreas is normal and isoechoic to surrounding mesentery. There is no evidence of nodules or cystic lesions. There is no evidence of regional mesenteric inflammation or fluid.

WEIGHT

5.36 kg

Free Abdomen

INTERPRETED BY

Kathleen Sennello DVM,
MS, Diplomate ACVIM
(Small Animal Internal
Medicine)

Evaluation of the peritoneal cavity did not reveal any evidence of effusion, or subjective lymphadenomegaly. The Medial iliac nodes appear normal and there was no evidence of a caudal aortic thrombus at the bifurcation. The omentum is of normal uniform echogenicity.

IMAGING PERFORMED BY

Kelly Reschny

ULTRASONOGRAPHIC FINDINGS

- Mildly mottled, borderline large spleen – The diffuse splenic changes are non-specific and could be consistent with lymphoid hyperplasia, extramedullary hematopoiesis, infiltrative neoplasia, inflammation, other. Cytology or histopathology would be necessary to get a definitive diagnosis.
- Moderately prominent muscularis layer of the small intestine – The small intestinal wall changes could be consistent with an underlying inflammatory process. These types of changes can sometimes be seen in normal older cats. Correlate with clinical signs.

HOSPITAL NAME

BPH East Hamilton

REFERRING VET

Dr. Elzaabalawy

INTERPRETATION OF THE FINDINGS & FURTHER RECOMMENDATIONS

No focal lesions are visualized associated with the gastrointestinal tract to explain the chronic vomiting reported. Unfortunately, there are many causes for chronic vomiting that cannot be diagnosed by ultrasound alone.

INVOICE

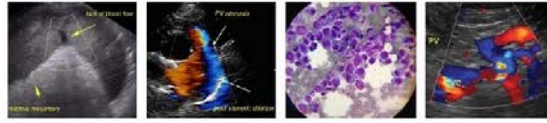
44734

Consider such differentials as food allergy/dietary indiscretion, GI parasitism, chronic pancreatitis, dysbiosis, ingested foreign material, and much less likely IBD or intestinal neoplasia.

DATE

8/16/23

The spleen appears mildly mottled and prominent. If round cell neoplasia is suspected, a fine needle aspirate could be considered. Additionally, the muscularis layer of the small intestine appears prominent in some images, but not consistently severely thickened.



PATIENT

Dwayne Dalton

SPECIES

Feline

BREED

DSH

SEX

Neutered Male

AGE

1 Year

WEIGHT

5.36 kg

INTERPRETED BY

Kathleen Sennello DVM,
MS, Diplomate ACVIM
(Small Animal Internal
Medicine)

**IMAGING
PERFORMED BY**

Kelly Reschny

HOSPITAL NAME

BPH East Hamilton

REFERRING VET

Dr. Elzaabalawy

INVOICE

44734

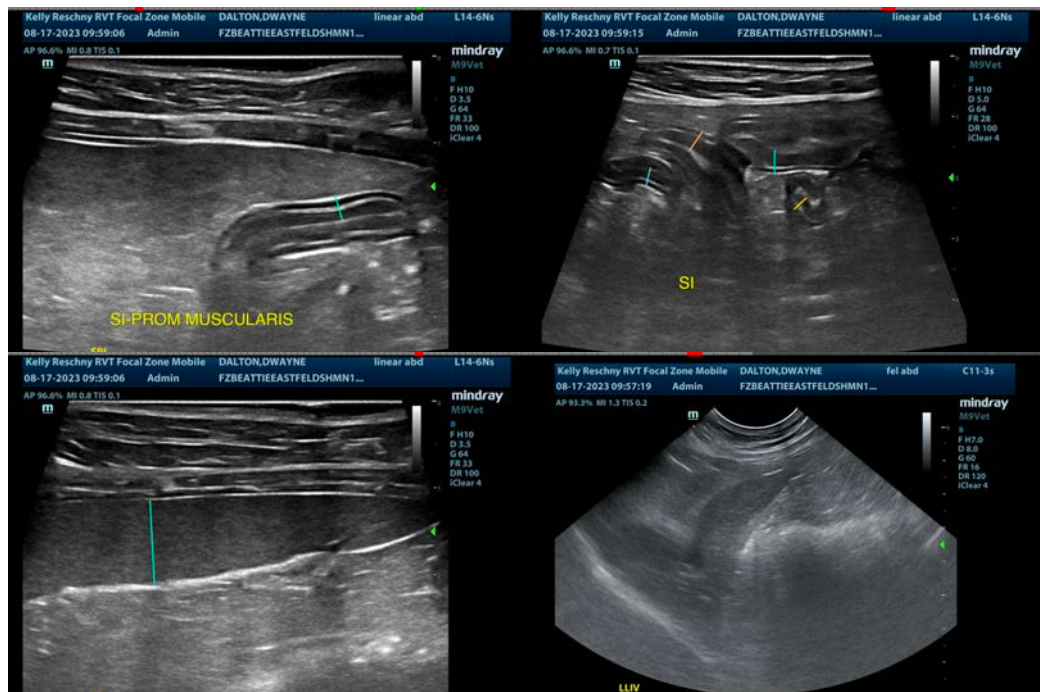
DATE

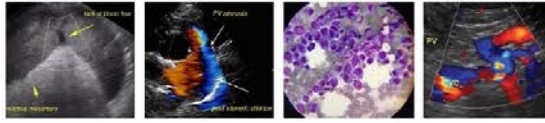
8/16/23

- Consider a novel protein/hydrolyzed protein diet (exclusively at least 4-6 weeks)
- Consider a GI panel to Texas A&M for evaluation of B12 levels, folate, PLI/TLI etc.. to further evaluate for pancreatic/small intestinal disease.
- Recommend chronic probiotic therapy.

If bloodwork is normal and metabolic disease is thought an unlikely source of the vomiting, and there is no response to symptomatic therapy as recommended, consider obtaining GI biopsies.

Recommend three view thoracic radiographs to evaluate for possible concurrent thoracic disease/involvement.





PATIENT

Dwayne Dalton

SPECIES

Feline

BREED

DSH

SEX

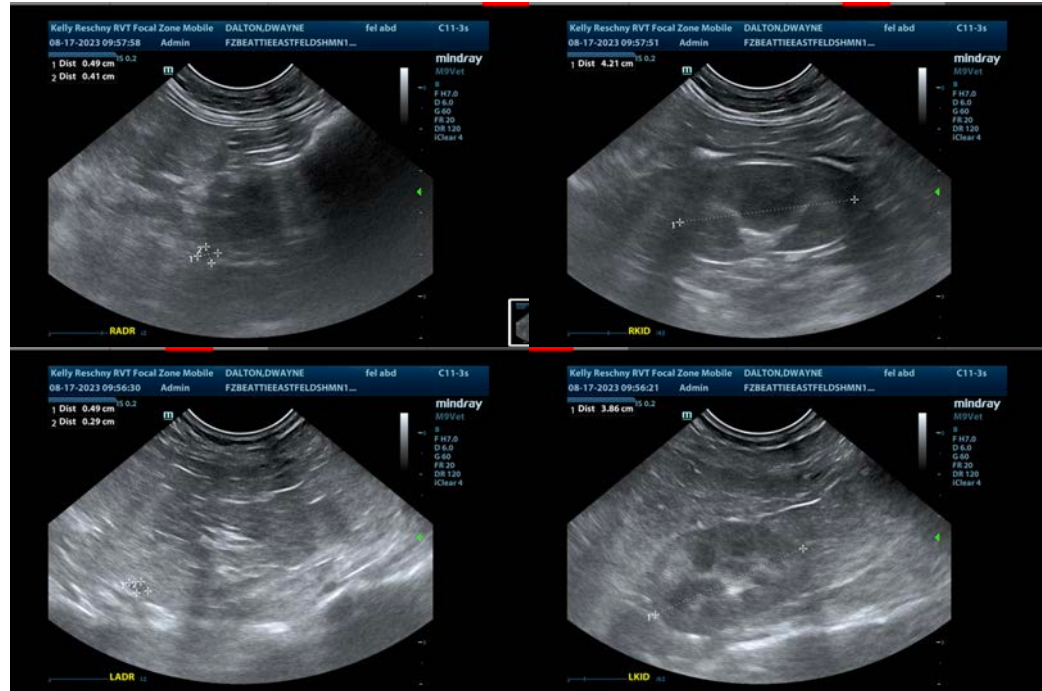
Neutered Male

AGE

1 Year

WEIGHT

5.36 kg



INTERPRETED BY

Kathleen Sennello DVM,
MS, Diplomate ACVIM
(Small Animal Internal
Medicine)

**IMAGING
PERFORMED BY**

Kelly Reschny

HOSPITAL NAME

BPH East Hamilton

REFERRING VET

Dr. Elzaabalawy

INVOICE

44734

DATE

8/16/23

The information and recommendations provided are based on the images presented by the referring veterinarian/sonographer. No evaluation can be communicated regarding pathology that was not visible in the image/video clips provided.

Thank you for this referral. If the clinical or image interpretation does not parallel your findings or if I can be of any further assistance please contact me.

Kathleen Sennello DVM,MS, Diplomate ACVIM (Small animal Internal Medicine)

info@sonopath.com