

**DATE PRESENTING CLINICAL SIGNS**

8/17/23

PATIENT

Dierks Bunce

SPECIES

Canine

BREED

Labrador Retriever

SEX

Neutered Male

AGE

8/8/18

WEIGHT

77.4 Pounds

INTERPRETED BYKathleen Sennello DVM,
MS, Diplomate ACVIM
(Small Animal Internal
Medicine)**HOSPITAL NAME**Animal Emergency
Hospital**REFERRING VET**

Dr. Kalwa

INVOICE

44738

8/14/23- AEH - PC: Lethargy, vomiting + blood, hyporexia - Initial exam: QAR, 4/9 bcs, H/L wnl, abdomen painful - DDX: DI, viral/ bacterial/parasitic, allergy, open - Discussed management of vomiting right now- SQ fluids, Cerenia, GI protectants but wants more extensive workup ie abdominal ultrasound, re-explore, GI biopsies. Risk for Severe IBD, food allergy that may resolve with right combo of meds, diet. - Xray 2 view: Stomach empty, formed stool in colon, few gas bubbles in GIT, no obvious FB - SQ fluids - Maropitant injection - Sucralfate - In discharge discussed Abdominal ultrasound, GI explore, GI biopsies, Internal medicine for endoscopy / biopsies History: - March 2022- ate daughters toy, GI obstruction, FB to remove, Rough recovery, external sutures dehiscd needed replacement - December- severe diarrhea- Multiple tests for GI issues- no answers so far - Possible salmon allergy _____ ATO today: - Left here yesterday went home gave treats, milk bone, blue buffalo with white rice- didnt eat much - Energy decreased - Tuesday 15th- ate 1/2 can of ID- picked up from rDVM - Walk- normal stool - 12:30- 1pm- phlem all over house, mucus no color - Called 2pm- large vomit, all liquid, no odor, no food - Vomiting since - NE dinner ID, not wanting treats - Very painful abdomen - Locked in kitchen with baby door - 10:30pm- vomited water smelled like sewage - O very frustrated about cost, costs > \$1,000 every time. O would like an answer to feel better - Prior to abdominal sx has ate multiple FB- bird, child sock, wife headband, 1/2 flip flop, and numerous other things - Taking metronidazole every 3rd day
Date: 08-16-2023 Notes: 2022 had surgery Diarrhea 3 days in december 1 week later greenbriar fecal, bloodwork, metronidazole, other tests Needs Q3 day metronidazole, or diarrhea comes back- talked to rDVM about that

Current Medications: Ampicillin, Protonix, Buprenorphine, Cerenia.

Lab Results: See attached.

Radiographs: no obvious foreign body or obstruction; mineralized opacity (tiny) on the lateral xray noted- in the stomach spleen prominent

Date of Previous IntraPet Ultrasound: No previous.

Sedation: IV.

Stat Report: STAT requested.

Imaging Performed By: Rachel Brillhart, RDMS.

ULTRASONOGRAPHIC EXAMINATION OF THE ABDOMEN**Urinary System**

The urinary bladder is minimally to mildly distended with anechoic urine. The Bladder wall appears normal with no evidence of any mass lesions or calculi. Full evaluation of the urinary bladder is difficult due to lack of urine distention.

Pancreas is prominent in size with swollen irregular contour. Parenchyma is heterogenous characterized by hyperechoic tissue remodeling intermixed with ill-defined hypoechoic nodules. There is no visible pancreatic duct dilation. There is no evidence of active peripancreatic inflammation.

The left kidney has a normal shape and size (6.92 cm). Overall echogenicity is normal with adequate corticomedullary distinction and a typical 1:3 cortex:medulla ratio. There is no evidence of focal perinephric inflammation or effusion. There is no evidence of pyelectasia, nephroliths, infarcts or hydroureter. Renal vasculature is normal.

The right kidney has a normal shape and size (6.88 cm). Overall echogenicity is normal with adequate corticomedullary distinction and a typical 1:3 cortex:medulla ratio. There is no evidence of focal perinephric

inflammation or effusion. There is no evidence of pyelectasia, nephroliths, infarcts or hydroureter. Renal vasculature is normal.

Adrenal Glands

The left adrenal gland is normal in size measuring 0.64 cm at the caudal pole. It is observed in its normal position cranial to the left renal artery. It is normal in appearance (uniformly hypoechoic) and shape with no evidence of a mass effect.

The right adrenal gland is normal in size measuring 0.80 cm at the caudal pole. It is observed in its normal position between the cranial aspect of the right kidney and the caudal vena cava. It is normal in appearance (uniformly hypoechoic) and shape with no evidence of a mass effect.

Spleen

The spleen is subjectively normal in size. The spleen echotexture is heterogenous and mildly mottled, the splenic capsule is smooth with no irregularities. The blood flow through the hilus and splenic parenchyma appears normal. No focal parenchymal abnormalities are visualized.

Liver

The liver is subjectively normal in size, and echogenicity with smooth peripheral margins. The parenchyma is homogenous echotexture. The visible portions of the vasculature and biliary tract appear normal. No focal nodules or cystic lesions are observed.

The gallbladder lumen is moderately distended. The wall of the gall bladder is not thickened and has a smooth mucosal surface. Luminal contents are mild and primarily anechoic. The cystic and common bile ducts are normal/not visible.

Gastrointestinal

The stomach contains minimal luminal contents. It measures at a normal thickness of <0.7cm with some variability due to the presence of rugal folds. The distinction of the gastric wall layers is adequate and there is no impression of reduced peristaltic activity. No masses or focal lesions were observed.

The visualized areas of duodenum, jejunum and ileum have a uniform diameter with minimal fluid distension. Wall thickness is increased. Jejunum wall measures 0.50 cm. Duodenum wall measures 0.65 cm. Bowel loops follow a typical curvilinear path. Some areas have reduced detail of wall layering. Visualized peristalsis appears appropriate. There is a focal section of bowel that appears severely thickened with an irregular hypoechoic wall and complete loss of layering. This creates a mass effect in the transverse view measuring 3.3 cm x 4.82 cm, which extends to involve approximately 6.0 cm of small intestine. In this area the bowel wall measures 1.6 cm in thickness. There is evidence of some mild plication in this region, possibly consistent with an early partial intussusception.

Sections of colon are visualized with formed fecal material and gas shadowing distally. There is no observed focal or generalized colon wall thickening or loss of layering.

Pancreas

The pancreas is normal and isoechoic to surrounding mesentery. There is no evidence of nodules or cystic lesions. There is no evidence of regional mesenteric inflammation or fluid.

Free Abdomen

There is a small amount of free fluid. There are prominent mesenteric lymph nodes visualized. One measures 0.48 cm in diameter. The omentum is hyperechoic around the abnormal bowel.

ULTRASONOGRAPHIC FINDINGS

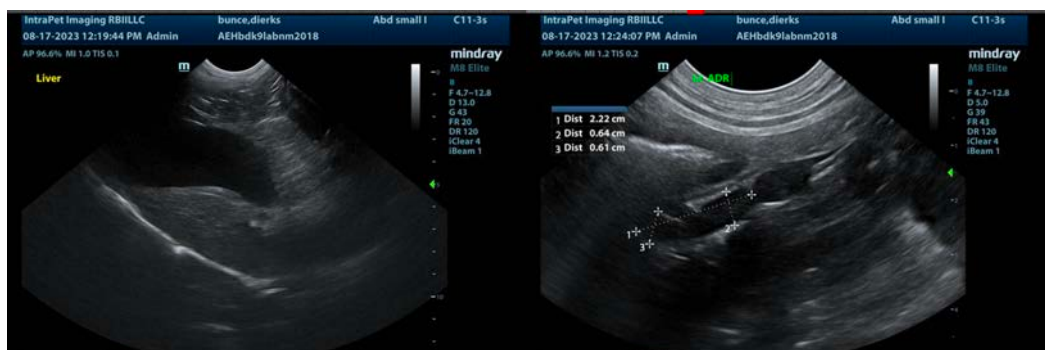
- Mildly mottled spleen – The diffuse splenic changes are non-specific and could be consistent with lymphoid hyperplasia, extramedullary hematopoiesis, infiltrative neoplasia, inflammation, other. Cytology or histopathology would be necessary to get a definitive diagnosis.
- Focal area of small intestine with severe irregular wall thickening and complete loss of layering – Findings are most consistent with a focal bowel mass. Neoplasia is the primary differential (round cell neoplasia, carcinoma, other), although other differentials are possible.
- Prominent mesenteric lymph nodes – The prominent abdominal lymph nodes are most consistent with reactive lymphadenitis or lymphoid hyperplasia. Neoplastic infiltration is considered less likely.

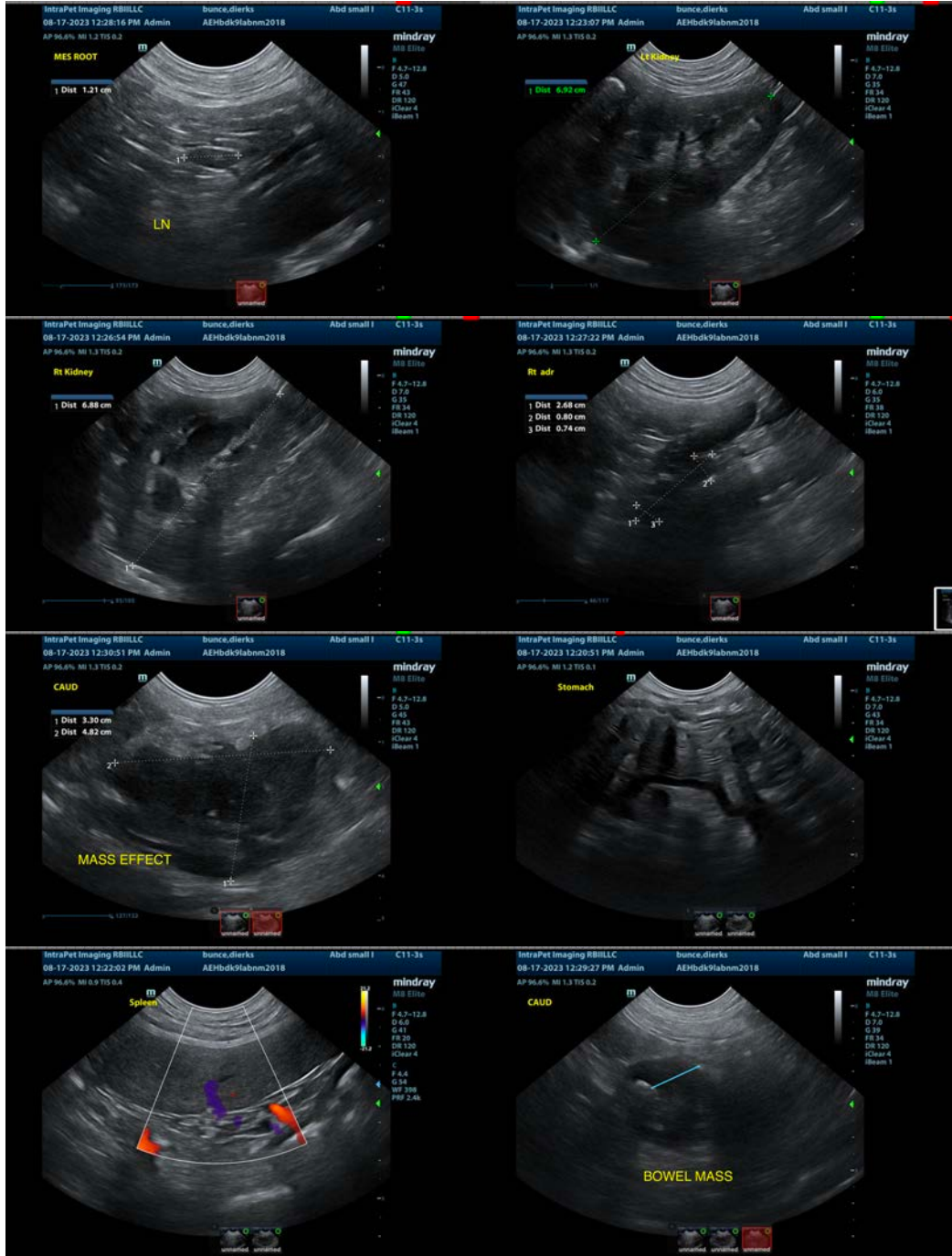
INTERPRETATION OF THE FINDINGS & FURTHER RECOMMENDATIONS

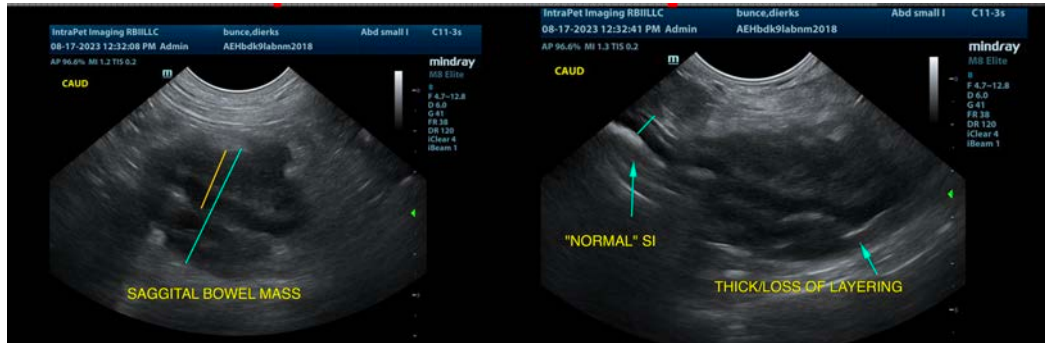
There is a focal section of small bowel that appears severely thickened with an irregular hypoechoic wall and complete loss of layering. The bowel wall creates a mass effect. These changes are concerning for infiltrative neoplasia (round cell neoplasia, carcinoma, other), although other differentials are possible. Consider a fine needle aspirate of the bowel wall.

The spleen subjectively appears slightly mottled. If a cytologic diagnosis cannot be obtained based on an aspirate of the bowel mass, consider a fine needle aspirate of the spleen. Additionally, there are occasional prominent mesenteric lymph nodes observed.

Recommend three view thoracic radiographs to evaluate for possible concurrent thoracic disease/involvement.







The information and recommendations provided are based on the images presented by the referring veterinarian/sonographer. No evaluation can be communicated regarding pathology that was not visible in the image/video clips provided.

Thank you for this referral. If the clinical or image interpretation does not parallel your findings or if I can be of any further assistance please contact me.

Kathleen Sennello DVM,MS, Diplomate ACVIM (Small animal Internal Medicine)
info@sonopath.com