

**DATE PRESENTING CLINICAL SIGNS**

8/16/22 Past few weeks appetite is decreased. Had episode of acute lethargy last week x 24 hours and recovered. On PE few pounds decrease recently- not muscle wasted, mm pink, no murmur and lungs clear.

**PATIENT**

Whiskey Fisher

Current Medications: trazadone 100mg SID-BID PRN for anxiety past year.

Lab Results: Chem 17/CBC NSF.

Radiographs: right lateral intestines displaced caudally and decreased detail cranially.

Date of Previous IntraPet Ultrasound: No previous.

**SPECIES**

Sedation: Not required to complete full diagnostic ultrasound.

Canine

Stat Report: Not requested.

**BREED**

Mixed

**ULTRASONOGRAPHIC EXAMINATION OF THE ABDOMEN****Urinary System**

The urinary bladder is moderately distended with anechoic urine. The Bladder wall, trigone, ureteral papillae and visible urethra (to a depth of 2cm) appear normal with no evidence of wall thickening, mucosal irregularities, masses or cystic calculi.

**SEX**

Neutered Male

The visualized areas of prostate and surrounding tissue appear normal. Unfortunately, the prostate is not fully visualized likely due to its intrapelvic location. Correlate with rectal exam findings.

**AGE**

1/1/09

The left kidney is borderline large (7.42 cm) Overall echogenicity is slightly hyperechoic with poor corticomedullary distinction and a typical 1:3 cortex:medulla ratio. There is no evidence of perinephric inflammation or effusion. There is no evidence of pyelectasia, nephroliths, infarcts or hydroureter. Renal vasculature is normal. There is a large 1.5 cm cyst visualized off the cranial pole of the left kidney.

**WEIGHT**

72 Pounds

The right kidney has a normal shape and size (5.79 cm). Overall echogenicity is slightly hyperechoic with poor corticomedullary distinction and a typical 1:3 cortex:medulla ratio. There is no evidence of perinephric inflammation or effusion. There is no evidence of pyelectasia, nephroliths, infarcts or hydroureter. Renal vasculature is normal.

**INTERPRETED BY**

Kathleen Sennello DVM,  
MS, Diplomate ACVIM  
(Small Animal Internal  
Medicine)

**Adrenal Glands**

The left adrenal gland is normal in size measuring 0.89 cm at the caudal pole. It is observed in its normal position cranial to the left renal artery. It is normal in appearance (uniformly hypoechoic) and shape with no evidence of a mass effect.

**IMAGING PERFORMED BY**

Rachel Brilhart RDMS

The right adrenal gland is normal in size measuring 0.83 cm at the caudal pole. It is observed in its normal position between the cranial aspect of the right kidney and the caudal vena cava. It is normal in appearance (uniformly hypoechoic) and shape with no evidence of a mass effect.

**HOSPITAL NAME**

Jacksonville VH

**Spleen**

The spleen is subjectively normal in size. The spleen echotexture is heterogenous and mildly mottled, the splenic capsule is smooth with no irregularities. The blood flow through the hilus and splenic parenchyma appears normal. There is a small, ill-defined, hypoechoic lesion visualized within the parenchyma measuring 1.24 cm.

**REFERRING VET**

Dr. Thai

**INVOICE**

40499

**Liver**

The liver is subjectively normal in size, and echogenicity with smooth peripheral margins. The parenchyma is heterogenous in echotexture with subtle, indistinct focal mottling. The visible portions of the vasculature and biliary tract appear normal. There is a small cystic lesion measuring 1.67 cm visualized deep on the left side of the liver.

The gallbladder lumen is moderately distended. The wall of the gall bladder is not thickened and has a smooth mucosal surface. Luminal contents are primarily anechoic. The cystic and common bile ducts are normal/not visible.

### ***Gastrointestinal***

The stomach contains minimal luminal contents. It measures at a normal thickness of <0.7cm with some variability due to the presence of rugal folds. The distinction of the gastric wall layers is adequate and there is no impression of reduced peristaltic activity. No masses or focal lesions were observed.

The visualized areas of duodenum, jejunum and ileum have a relatively uniform diameter with minimal fluid distension. Wall thickness is normal. Bowel loops follow a curvilinear path with distinct wall layering maintaining the typical 1:3 muscularis:mucosa layer ratio. The duodenum measured as normal (between 0.3-0.5cm in wall thickness) and the jejunum measured as normal (between 0.2-0.47cm.) Visualized peristalsis appears appropriate. There were no focal lesions consistent with obstruction or a mass effect observed.

The ileocecal junction was visualized and exhibited normal intact wall layering and is subjectively of normal thickness. Sections of colon are visualized with formed fecal material and gas shadowing distally. There is no observed focal or generalized colon wall thickening or loss of layering.

### ***Pancreas***

The pancreas is prominent and mottled compared to the surrounding isoechoic mesentery. There is no evidence of nodules or cystic lesions. There is no evidence of regional mesenteric inflammation or fluid.

### ***Free Abdomen***

Evaluation of the peritoneal cavity did not reveal any evidence of effusion. There is a prominent lymph node visualized near the pancreas in the right cranial abdomen measuring 0.33 cm x 1.58 cm. The omentum is of normal echogenicity.

## **ULTRASONOGRAPHIC FINDINGS**

- Decreased corticomedullary distinction in both kidneys with a left-sided renal cystic lesion – The bilateral renal findings are consistent with age-related change. Recommend continued monitoring of the cystic lesion for progression.
- Mottled spleen with ill-defined hypoechoic nodule – There is a non-cavitated, hypoechoic splenic nodule visualized. Differentials include lymphoid hyperplasia, extramedullary hematopoiesis, infiltrative neoplasia, inflammation, other. Cytology or histopathology would be necessary to get a definitive diagnosis.
- Mildly mottled pancreas – The pancreatic changes are most consistent with age-related parenchymal remodeling, potentially secondary to a prior inflammatory episode, early fibrosis or chronic pancreatitis.
- Heterogeneous liver with small cystic lesion on the left side – The diffuse hepatic changes are non-specific and could be consistent with vacuolar hepatopathy, nodular hyperplasia, inflammatory/immune-mediated disease, fibrosis, extramedullary hematopoiesis, toxic hepatopathy (e.g., copper), infiltrative neoplasia (less likely) or other hepatopathy. This can also be seen with age related remodeling.
- Prominent lymph node visualized in the cranial abdomen – The prominent abdominal lymph nodes are most consistent with reactive lymphadenitis or lymphoid hyperplasia. Neoplastic infiltration is considered less likely.

## INTERPRETATION OF THE FINDINGS & FURTHER RECOMMENDATIONS

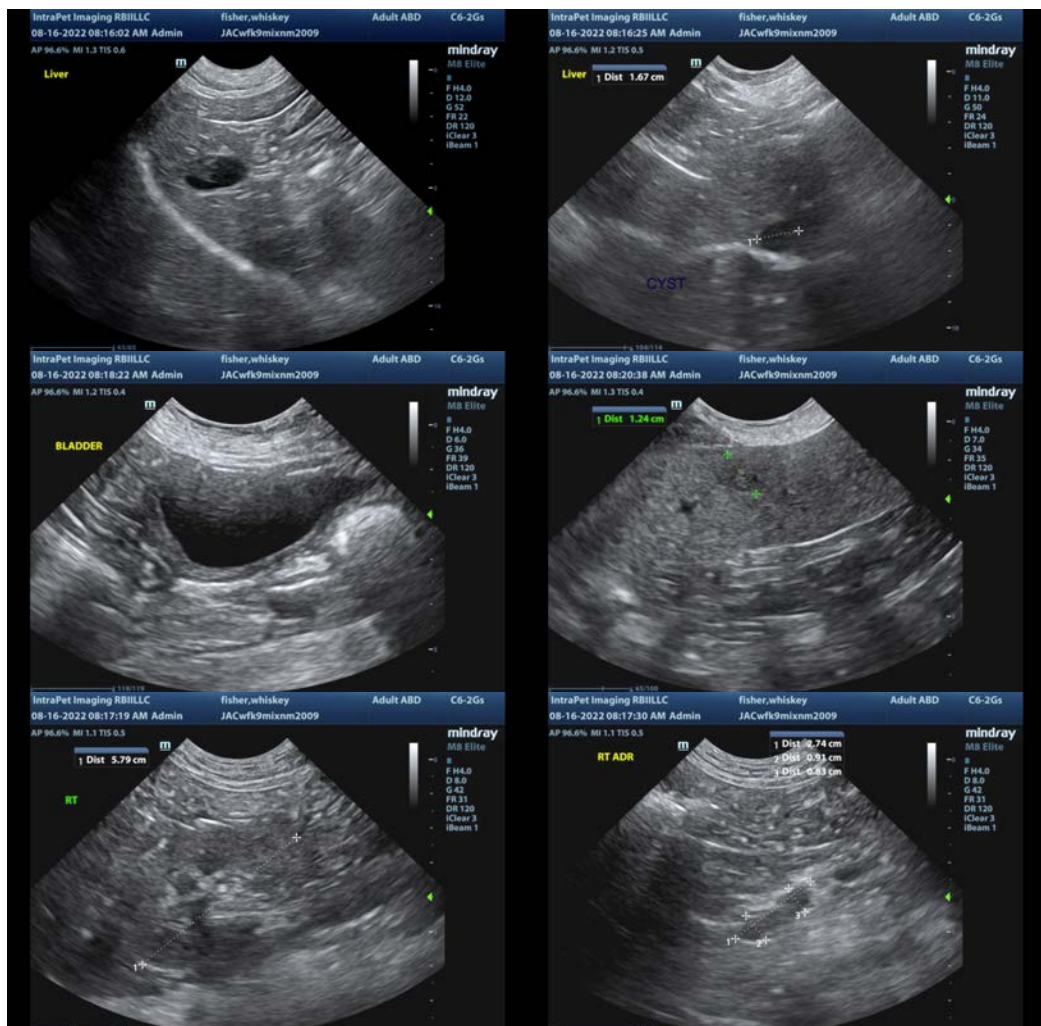
The lesions observed on today's scan were relatively non-specific. There are age related changes associated with both kidneys in addition to a left-sided renal cyst. Recommend continued monitoring of this cystic structure. Consider a blood pressure evaluation, urinalysis and culture for a baseline.

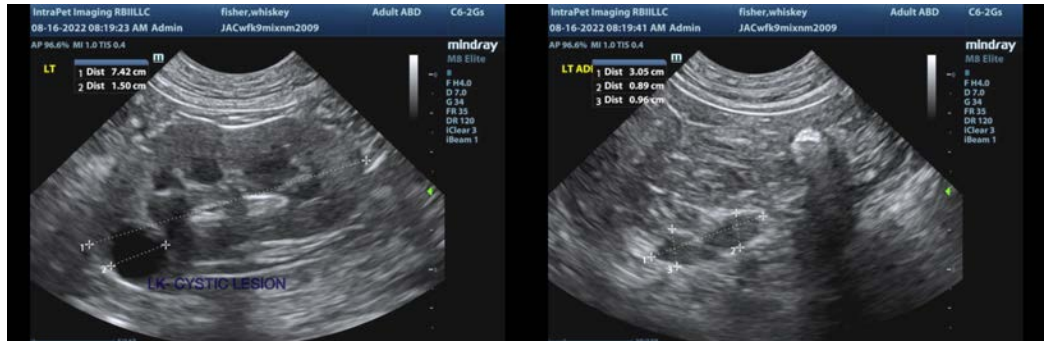
The spleen appears mildly mottled and there is a small, ill-defined, hypoechoic region. Consider a fine needle aspirate of the spleen.

The significance of the heterogeneous liver is unclear. With no liver enzyme elevations, options would include continued monitoring or a liver function test and a fine needle aspirate.

There is a small prominent lymph node visualized in the right cranial abdomen. The significance of this is unclear. Recommend continued monitoring.

The definitive source for the symptoms described is not visualized. I would consider a urinalysis, culture, and a fine needle aspirate of the spleen if coagulation parameters permit. Additionally, consider 3-view thoracic radiographs.





The information and recommendations provided are based on the images presented by the referring veterinarian/sonographer. No evaluation can be communicated regarding pathology that was not visible in the image/video clips provided.

Thank you for this referral. If the clinical or image interpretation does not parallel your findings or if I can be of any further assistance please contact me.

Kathleen Sennello DVM,MS, Diplomate ACVIM (Small animal Internal Medicine)  
kathleen.sennello@sonopath.com