

**DATE PRESENTING CLINICAL SIGNS**

8/16/22 History of decreased appetite and lethargy since 7/25. BW revealed low protein (panhypoproteinemia). Vomiting.

**PATIENT**

Nala Schleper

Current Medications: Entyce 2.7ml PO SID.

Lab Results: See attached.

Date of Previous IntraPet Ultrasound: No previous.

Sedation: Declined.

Stat Report: Not requested.

**SPECIES**

Canine

**ULTRASONOGRAPHIC EXAMINATION OF THE ABDOMEN****BREED**

Boxer

**Urinary System**

The urinary bladder is moderately distended with anechoic urine. The Bladder wall, trigone, ureteral papillae and visible urethra (to a depth of 2cm) appear normal with no evidence of wall thickening, mucosal irregularities, masses or cystic calculi.

**SEX**

Spayed Female

The left kidney has a normal shape and size (6.84 cm). Overall echogenicity is normal with adequate corticomedullary distinction and a typical 1:3 cortex:medulla ratio. There is no evidence of perinephric inflammation or effusion. There is no evidence of pyelectasia, nephroliths, infarcts or hydroureter. Renal vasculature is normal.

**AGE**

7/20/17

The right kidney has a normal shape and size (6.41 cm). Overall echogenicity is normal with adequate corticomedullary distinction and a typical 1:3 cortex:medulla ratio. There is no evidence of perinephric inflammation or effusion. There is no evidence of pyelectasia, nephroliths, infarcts or hydroureter. Renal vasculature is normal.

**WEIGHT**

61.3 Pounds

**INTERPRETED BY**

Kathleen Sennello DVM,  
MS, Diplomate ACVIM  
(Small Animal Internal  
Medicine)

**Adrenal Glands**

The left adrenal gland is normal in size measuring 0.56 cm at the caudal pole. It is observed in its normal position cranial to the left renal artery. It is normal in appearance (uniformly hypoechoic) and shape with no evidence of a mass effect.

**IMAGING PERFORMED BY**

The right adrenal gland is normal in size measuring 0.59 cm at the caudal pole. It is observed in its normal position between the cranial aspect of the right kidney and the caudal vena cava. It is normal in appearance (uniformly hypoechoic) and shape with no evidence of a mass effect.

Rachel Brilhart RDMS

**HOSPITAL NAME**

Creswell Vet Clinic

**Spleen**

The spleen is subjectively normal in size, echotexture is homogenous, and the splenic capsule is smooth with no irregularities. The blood flow through the hilus and splenic parenchyma appears normal. No focal parenchymal abnormalities are visualized.

**REFERRING VET**

Dr. Cullum

**Liver**

The liver is subjectively normal in size, and echogenicity with smooth peripheral margins. The parenchyma is homogenous echotexture. The visible portions of the vasculature and biliary tract appear normal. No focal nodules or cystic lesions are observed.

**INVOICE**

40493

The gallbladder lumen is moderately distended. The wall of the gall bladder is not thickened and has a smooth mucosal surface. Luminal contents are primarily anechoic. The cystic and common bile ducts are normal/not visible.

### ***Gastrointestinal***

The stomach contains minimal luminal contents. The body of the stomach measures at a normal thickness of <0.7cm with some variability due to the presence of rugal folds. The distinction of the gastric wall layers is adequate and there is no impression of reduced peristaltic activity. In the region of the pylorus, the gastric wall significantly thickens and becomes irregular with loss of layering and severe surrounding inflammation. In this region, the gastric wall measures at 1.65 cm in thickness. This thickening extends into the duodenum.

The majority of the visualized areas of jejunum and ileum have a relatively uniform diameter with minimal fluid distension. Wall thickness is normal. Bowel loops follow a curvilinear path with distinct wall layering maintaining the typical 1:3 muscularis:mucosa layer ratio. In the region of the proximal duodenum, the wall thickens and measures at approximately 0.57 cm with reduced detail of wall layering as it approaches the pylorus. The jejunum measures as normal between 0.2-0.47 cm and has normal peristalsis.

The ileocecal junction was visualized and exhibited normal intact wall layering and is subjectively of normal thickness. Sections of colon are visualized with formed fecal material and gas shadowing distally. There is no observed focal or generalized colon wall thickening or loss of layering.

### ***Pancreas***

The pancreas is prominent and mottled compared to the surrounding isoechoic mesentery. There is no evidence of nodules or cystic lesions. There is no evidence of regional mesenteric inflammation or fluid.

### ***Free Abdomen***

There is scant free fluid. There are numerous clusters of prominent, enlarged, hypoechoic, rounded lymph nodes at the root of the mesentery and throughout the mesentery. The largest cluster visualized coalesces into a mass effect measuring 6.18 cm x 3.86 cm. The omentum is hyperechoic around the pyloric wall and the enlarged lymph nodes.

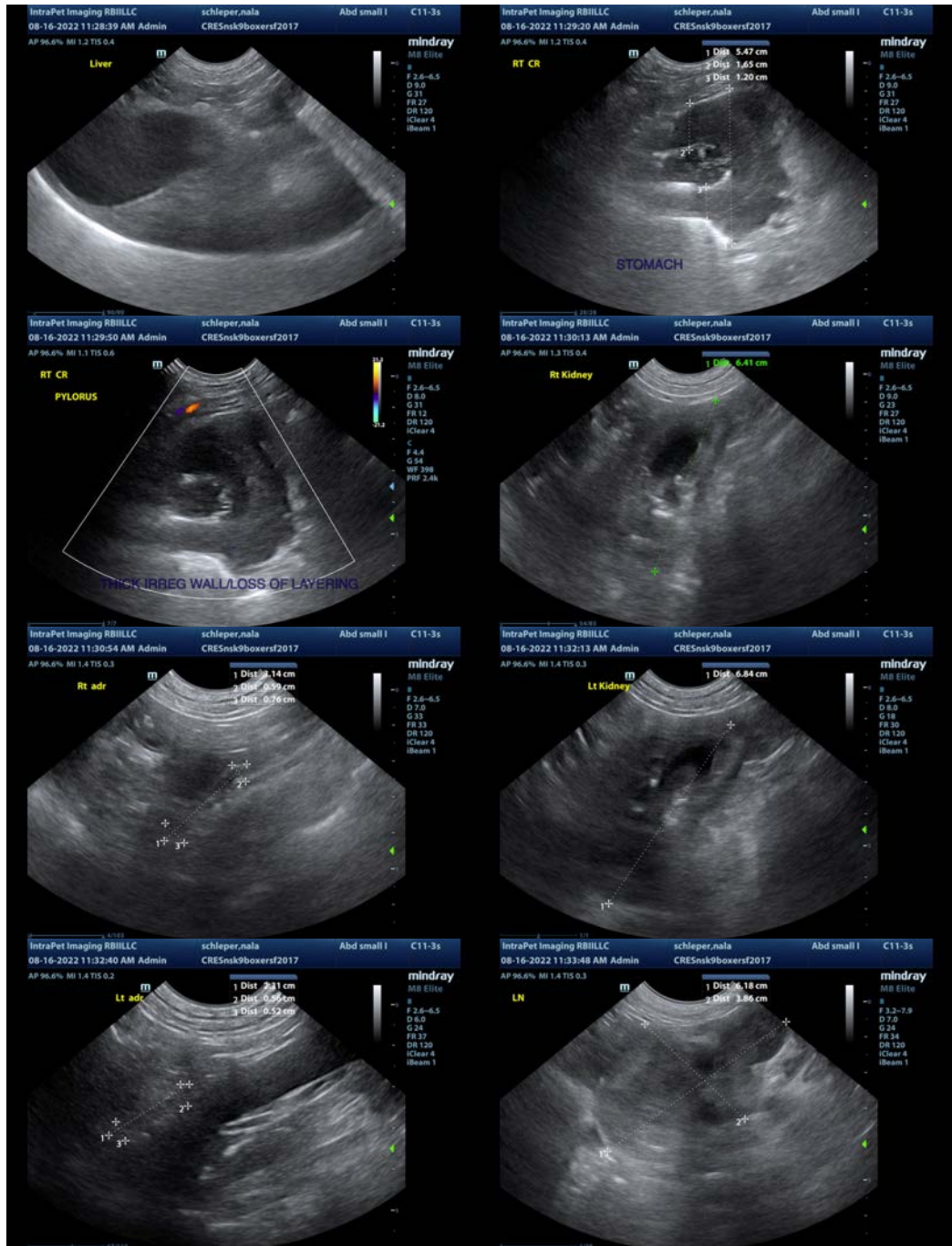
## **ULTRASONOGRAPHIC FINDINGS**

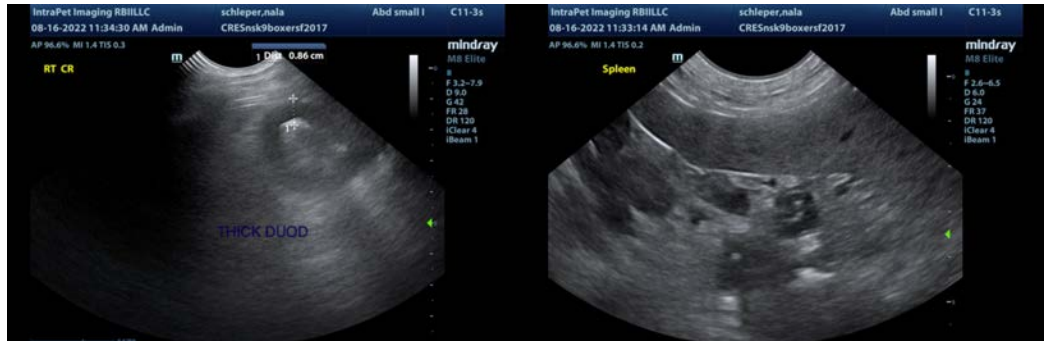
- Thickened, irregular wall in the region of the pylorus extending into the proximal duodenum and loss of layering to the pyloric wall – These changes are most consistent with infiltrative disease such as round cell neoplasia, carcinoma, severe gastritis, pythium, etc.
- Prominent, mottled pancreas - The pancreatic changes are most consistent with mild pancreatitis or a recent episode of pancreatic inflammation.
- Severe mesenteric lymphadenopathy – The severe mesenteric lymphadenopathy is most concerning for a neoplastic process, although you can see significant lymphadenopathy in some cases of autoimmune/inflammatory disease, infectious disease (tick born disease-such as bartonella, fungal infections, FIP (cats)) etc. A fine needle aspirate with cytology is recommended for further evaluation.

## **INTERPRETATION OF THE FINDINGS & FURTHER RECOMMENDATIONS**

There is severely thickened, irregular, hypoechoic GI tract visualized in the right cranial abdomen, most consistent with the pylorus extending into the duodenum. This is very concerning for a mass effect, but other differentials such as fungal disease, severe ulceration, infiltration, etc. are also possible. Consider a fine needle aspirate of the gastric wall in addition to a fine needle aspirate of a mesenteric lymph nodes. If pyogranulomatous inflammation is identified, recommend fungal titers (for pythium). If a cytologic diagnose cannot be obtained, consider surgical evaluation with biopsies and possible resection of abnormal tissue. Prognosis is guarded based on the extensive lymph node enlargement present and the concern for concurrent metastatic disease.

Consider three view thoracic radiographs to rule out concurrent thoracic disease/involvement.





The information and recommendations provided are based on the images presented by the referring veterinarian/sonographer. No evaluation can be communicated regarding pathology that was not visible in the image/video clips provided.

Thank you for this referral. If the clinical or image interpretation does not parallel your findings or if I can be of any further assistance please contact me.

Kathleen Sennello DVM,MS, Diplomate ACVIM (Small animal Internal Medicine)  
kathleen.sennello@sonopath.com