



PATIENT PRESENTING CLINICAL SIGNS

Ricochet Holfeld Recent diagnosis of IMHA

SPECIES Abnormal PE/Chem/CBC/UA Results: PE: PR Bounding pulses, Mmpi CRT<2s, BCS 3/5, Attitude: BAR Temp: 39.9C Chest auscultation: 140 bpm, no murmur, no arrhythmia, lungs clear Abdominal palpation: WNL soft and non painful Eyes, ears, nose: WNL Teeth: WNL Lymph nodes: WNL Skin + haircoat: Icteric Musculoskel: WNL Reprod: WNL Neuro: WNL PCV today: 17% (decreased from yesterday) CBC (yesterday) Agglutination -gross and microscopic Blood smear: spherocytes, polychromasia, ghost cells.

Canine

BREED

Whippet X

SEX

Spayed Female

AGE

5 Years

WEIGHT

11.5 kg

INTERPRETED BY

Kathleen Sennello DVM,
MS, Diplomate ACVIM
(Small Animal Internal
Medicine)

ULTRASONOGRAPHIC EXAMINATION OF THE ABDOMEN

Urinary System

The urinary bladder is moderately distended with anechoic urine. The Bladder wall, trigone, ureteral papillae and visible urethra (to a depth of 2cm) appear normal with no evidence of wall thickening, mucosal irregularities, masses or cystic calculi.

The left kidney has a normal shape and size (4.61 cm). Overall echogenicity is normal with adequate corticomedullary distinction and a typical 1:3 cortex:medulla ratio. There is no evidence of focal perinephric inflammation or effusion. There is no evidence of pyelectasia, nephroliths, infarcts or hydroureter. Renal vasculature is normal.

The right kidney has a normal shape and size (5.38 cm). Overall echogenicity is normal with adequate corticomedullary distinction and a typical 1:3 cortex:medulla ratio. There is no evidence of focal perinephric inflammation or effusion. There is no evidence of pyelectasia, nephroliths, infarcts or hydroureter. Renal vasculature is normal.

Adrenal Glands

The left adrenal gland is normal in size measuring 0.42 cm at the caudal pole. It is observed in its normal position cranial to the left renal artery. It is normal in appearance (uniformly hypoechoic) and shape with no evidence of a mass effect.

The right adrenal gland is normal in size measuring 0.42 cm at the caudal pole. It is observed in its normal position between the cranial aspect of the right kidney and the caudal vena cava. It is normal in appearance (uniformly hypoechoic) and shape with no evidence of a mass effect.

Spleen

The spleen is subjectively normal in size, echotexture is homogenous, and the splenic capsule is smooth with no irregularities. The blood flow through the hilus and splenic parenchyma appears normal. No focal parenchymal abnormalities are visualized.

Liver

The liver is subjectively normal in size, and echogenicity with smooth peripheral margins. The parenchyma is homogenous echotexture. The visible portions of the vasculature and biliary tract appear normal. No focal nodules or cystic lesions are observed.

IMAGING PERFORMED BY

Danielle Jaspar, RVT

HOSPITAL NAME

Orchard Vet Care

REFERRING VET

Dr. DeWalt

INVOICE

44694

DATE

8/15/23



PATIENT

Ricochet Holfeld

The gallbladder lumen is moderately distended. The wall of the gall bladder is not thickened and has a smooth mucosal surface. Luminal contents are mild and primarily anechoic. The cystic and common bile ducts are normal/not visible.

SPECIES

Canine

Gastrointestinal

The stomach contains moderate fluid/ingesta. It measures at a normal thickness of <0.7cm with some variability due to the presence of rugal folds. The distinction of the gastric wall layers is adequate and there is no impression of reduced peristaltic activity. No masses or focal lesions were observed.

BREED

Whippet X

The visualized areas of duodenum, jejunum and ileum have a relatively uniform diameter with minimal fluid distension. Wall thickness is normal. Bowel loops follow a curvilinear path with distinct wall layering maintaining the typical 1:3 muscularis:mucosa layer ratio. Jejunum wall measures 0.19 cm. Visualized peristalsis appears appropriate. There were no focal lesions consistent with obstruction or a mass effect observed.

SEX

Spayed Female

AGE

5 Years

The ileocecal junction was visualized and exhibited normal intact wall layering and is subjectively of normal thickness. Sections of colon are visualized with formed fecal material and gas shadowing distally. There is no observed focal or generalized colon wall thickening or loss of layering.

WEIGHT

11.5 kg

Pancreas

The area of the pancreas is normal and isoechoic to surrounding mesentery. There is no evidence of nodules or cystic lesions. There is no evidence of regional mesenteric inflammation or fluid.

INTERPRETED BY

Kathleen Sennello DVM,
MS, Diplomate ACVIM
(Small Animal Internal
Medicine)

Free Abdomen

Evaluation of the peritoneal cavity did not reveal any evidence of effusion, or subjective lymphadenomegaly. The Medial iliac nodes appear normal and there was no evidence of a caudal aortic thrombus at the bifurcation. The omentum is of normal uniform echogenicity.

IMAGING PERFORMED BY

Danielle Jaspar, RVT

ULTRASONOGRAPHIC FINDINGS

- Moderate fluid/ingesta visualized within the gastric lumen – Correlate these findings with the feeding history. If the patient was adequately fasted, consider such differentials as delayed gastric emptying or a pyloric outflow tract obstruction (none observed).

HOSPITAL NAME

Orchard Vet Care

INTERPRETATION OF THE FINDINGS & FURTHER RECOMMENDATIONS

Today's scan appears relatively normal. No prominent focal lesions are observed to explain the IMHA reported.

REFERRING VET

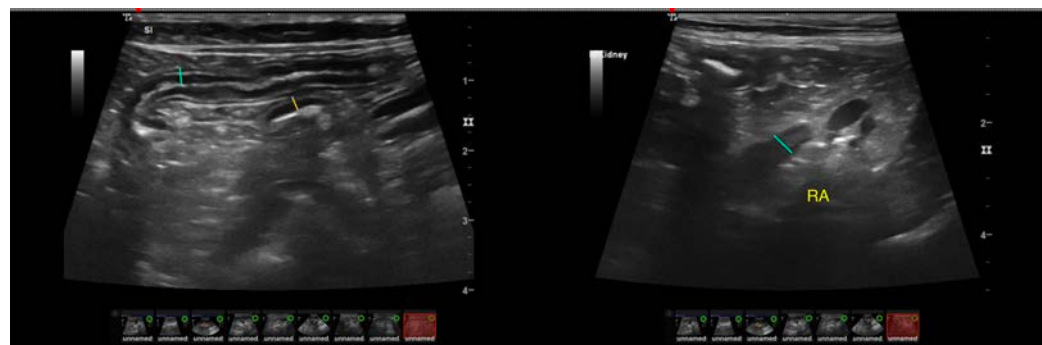Dr. DeWalt

INVOICE

44694

DATE

8/15/23





PATIENT

Ricochet Holfeld

SPECIES

Canine

BREED

Whippet X

SEX

Spayed Female

AGE

5 Years

WEIGHT

11.5 kg

INTERPRETED BY

Kathleen Sennello DVM,
MS, Diplomate ACVIM
(Small Animal Internal
Medicine)

**IMAGING
PERFORMED BY**

Danielle Jaspar, RVT

HOSPITAL NAME

Orchard Vet Care

REFERRING VET

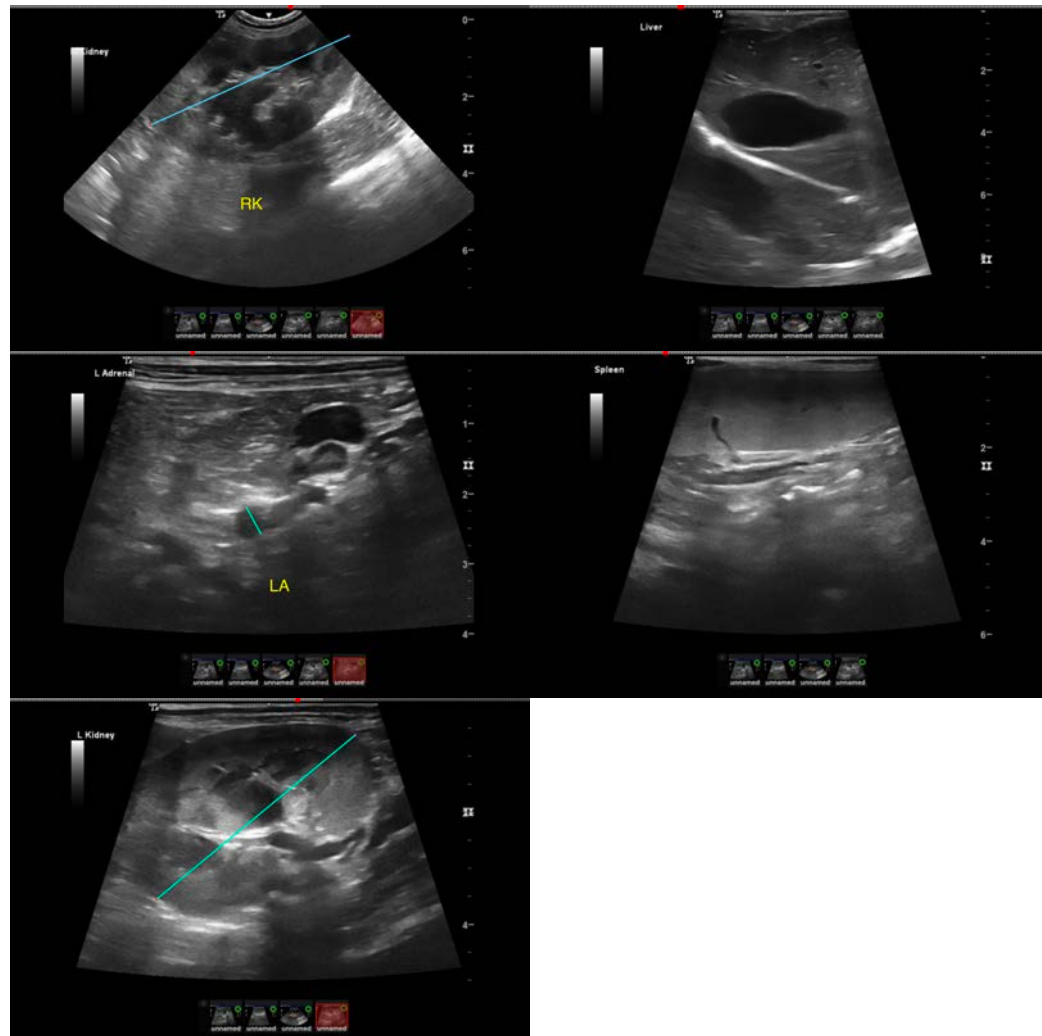
Dr. DeWalt

INVOICE

44694

DATE

8/15/23



The information and recommendations provided are based on the images presented by the referring veterinarian/sonographer. No evaluation can be communicated regarding pathology that was not visible in the image/video clips provided.

Thank you for this referral. If the clinical or image interpretation does not parallel your findings or if I can be of any further assistance please contact me.

Kathleen Sennello DVM,MS, Diplomate ACVIM (Small animal Internal Medicine)

info@sonopath.com