

**DATE PRESENTING CLINICAL SIGNS**

8/15/23

History of chronic diarrhea and possible IBD that has failed to improve with probiotics and hills w/d food, eats/drinks/urination fine, Obe has never had formed stool since O has gotten him, Obe was presented today for second opinion, bloodwork and fecal are pending but no abnormalities on exam today

PATIENT

Obe Morrison

SPECIES

Feline

Current Medications: synacore probiotics 1 packet once daily starting 8/11, Metronidazole 15 mg/kg every 12 hours by mouth starting 8/11

Date of Previous IntraPet Ultrasound: No previous.

Sedation: DKT IM.

Stat Report: Not requested.

Imaging Performed By: Rachel Brillhart, RDMS.

BREED

DLH

ULTRASONOGRAPHIC EXAMINATION OF THE ABDOMEN**SEX**

Neutered Male

Urinary System

The urinary bladder is moderately distended with anechoic urine. The Bladder wall, trigone, ureteral papillae and visible urethra (to a depth of 2cm) appear normal with no evidence of wall thickening, mucosal irregularities, masses or cystic calculi.

AGE

8/8/14

The left kidney has a normal shape and size (4.57 cm). Overall echogenicity is normal with adequate corticomedullary distinction and a typical 1:3 cortex:medulla ratio. There is no evidence of focal perinephric inflammation or effusion. There is no evidence of pyelectasia, nephroliths, infarcts or hydroureter. Renal vasculature is normal.

WEIGHT

13 Pounds

The right kidney has a normal shape and size (4.47 cm). Overall echogenicity is normal with adequate corticomedullary distinction and a typical 1:3 cortex:medulla ratio. There is no evidence of focal perinephric inflammation or effusion. There is no evidence of pyelectasia, nephroliths, infarcts or hydroureter. Renal vasculature is normal.

INTERPRETED BY

Kathleen Sennello DVM,
MS, Diplomate ACVIM
(Small Animal Internal
Medicine)

Adrenal Glands

The left adrenal gland is normal in size measuring 0.44 cm at the caudal pole. It is observed in its normal position cranial to the left renal artery. It is normal in appearance (uniformly hypoechoic) and shape with no evidence of a mass effect.

HOSPITAL NAME

Homeward Bound VS

The right adrenal gland is normal in size measuring 0.46 cm at the caudal pole. It is observed in its normal position between the cranial aspect of the right kidney and the caudal vena cava. It is normal in appearance (uniformly hypoechoic) and shape with no evidence of a mass effect.

REFERRING VET

Dr. Williams

Spleen

The spleen is subjectively normal in size (0.97 cm), echotexture is homogenous, and the splenic capsule is smooth with no irregularities. The blood flow through the hilus and splenic parenchyma appears normal. No focal parenchymal abnormalities are visualized.

INVOICE

44661

Liver

The liver is subjectively normal in size, and echogenicity with smooth peripheral margins. The parenchyma is homogenous echotexture. The visible portions of the vasculature and biliary tract appear normal. No focal nodules or cystic lesions are observed.

The gallbladder lumen is moderately distended. The wall of the gall bladder is not thickened and has a smooth mucosal surface. Luminal contents are mild and primarily anechoic. The cystic and common bile ducts are normal/not visible.

Gastrointestinal

The stomach contains minimal luminal contents. It measures at a normal thickness of <0.36cm with some variability due to the presence of rugal folds. The distinction of the gastric wall layers is adequate and there is no impression of reduced peristaltic activity. No masses or focal lesions were observed.

The visualized areas of duodenum, jejunum and ileum have a relatively uniform diameter with minimal fluid distension. Wall thickness is normal. Bowel loops follow a curvilinear path with distinct wall layering maintaining the typical 1:3 muscularis:mucosa layer ratio. Duodenum wall measures 0.27 cm. Jejunum wall measures 0.19 cm. Visualized peristalsis appears appropriate. There were no focal lesions consistent with obstruction or a mass effect observed.

The ileocecal junction was visualized and exhibited normal intact wall layering and is subjectively of normal thickness. Sections of colon are visualized with formed fecal material and gas shadowing distally. There is no observed focal or generalized colon wall thickening or loss of layering.

Pancreas

The pancreas is large and hypoechoic to surrounding mesentery. There is no evidence of nodules or cystic lesions. There is evidence of regional mesenteric inflammation. Consistent with mild pancreatitis.

Free Abdomen

Evaluation of the peritoneal cavity did not reveal any evidence of effusion. There are occasional prominent mesenteric lymph nodes. A sublumbar lymph node is visualized measuring 0.48 cm x 1.25 cm. Additionally, there are lymph nodes near the ileocecal junction measuring 0.40 cm and 0.34 cm in diameter. The mesentery is generally of normal echogenicity but slightly reactive around the pancreas.

ULTRASONOGRAPHIC FINDINGS

- Prominent, mottled pancreas with mildly reactive mesentery surrounding – The pancreatic changes are most consistent with mild pancreatitis/pancreatic inflammation. Recommend fPLI testing and continued monitoring for improvement or possible development of a pancreatic abscess. Consider fine needle aspirate if not improving.
- Prominent mesenteric lymph nodes – The prominent abdominal lymph nodes are most consistent with reactive lymphadenitis or lymphoid hyperplasia. Neoplastic infiltration is considered less likely.

INTERPRETATION OF THE FINDINGS & FURTHER RECOMMENDATIONS

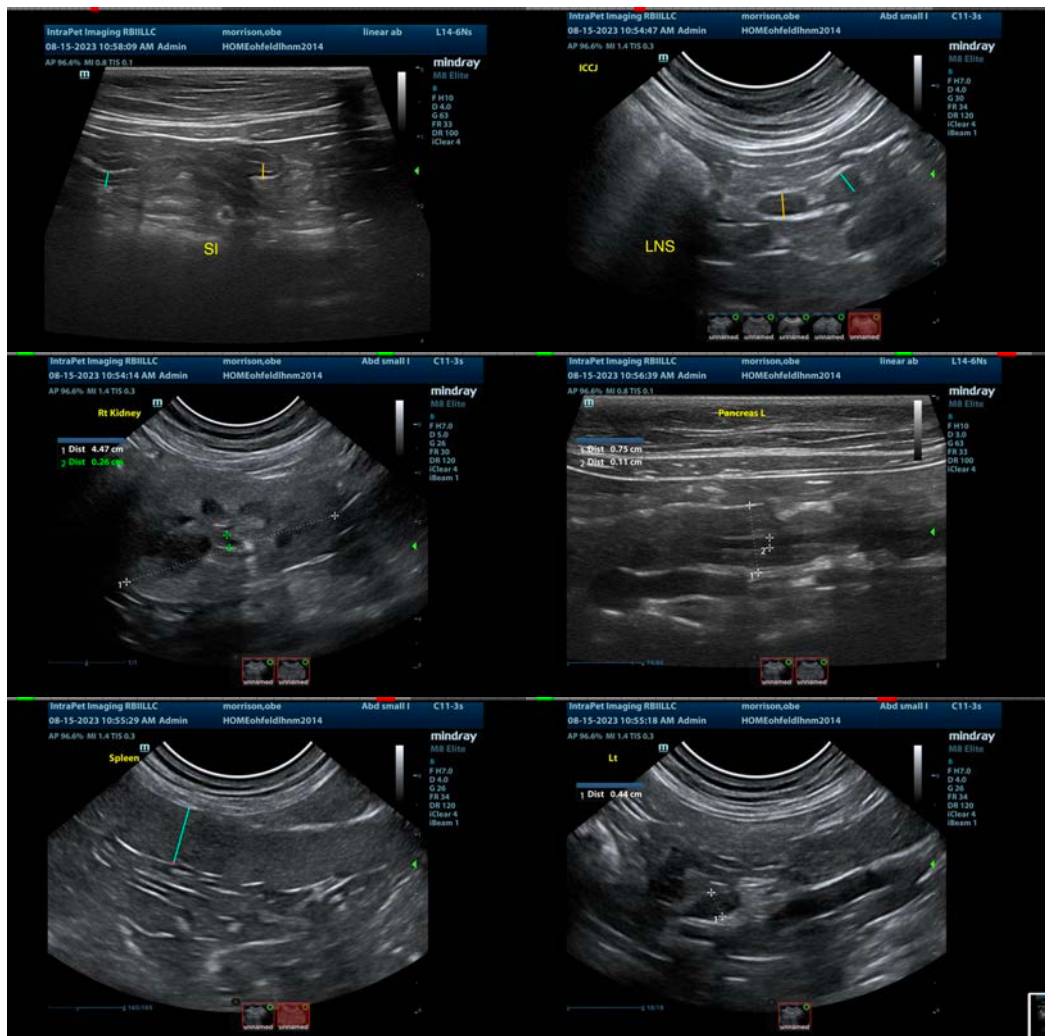
No focal lesions are visualized associated with the gastrointestinal tract to explain the chronic diarrhea reported. Unfortunately, there are many causes for chronic diarrhea that cannot be diagnosed by ultrasound alone.

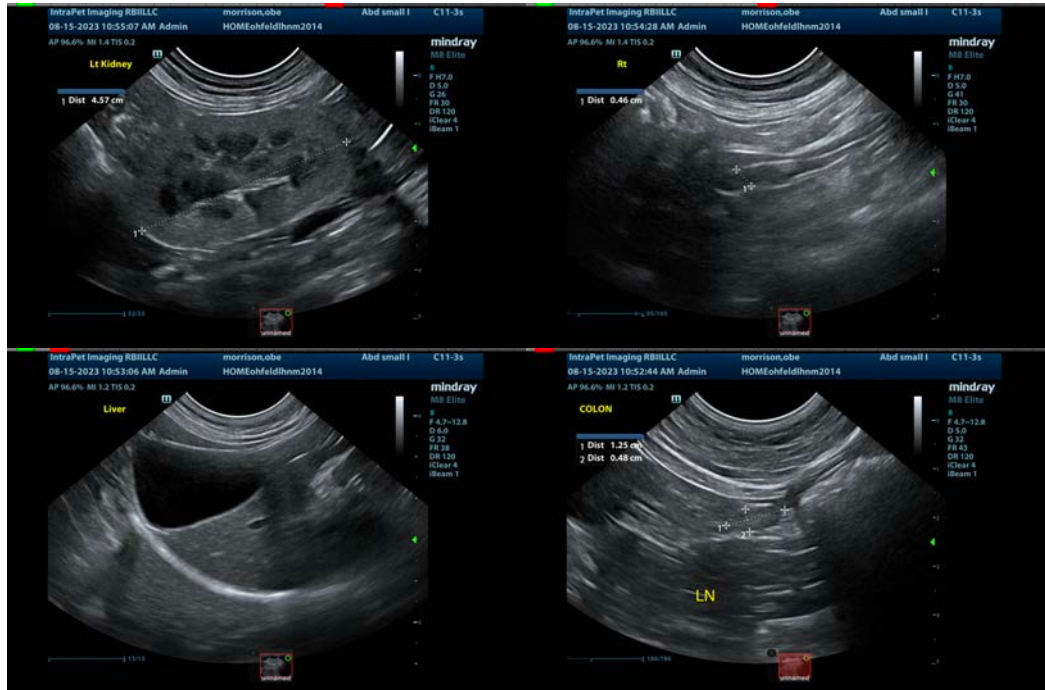
Consider such differentials as food allergy/dietary intolerance, GI parasitism, pancreatitis, dysbiosis, recurrent dietary indiscretion, IBD and less likely neoplasia, etc....

- Consider a novel protein/hydrolyzed protein diet (exclusively at least 4-6 weeks)

- Consider a GI panel to Texas A&M for evaluation of B12 levels, folate, PLI/TLI etc.. to further evaluate for pancreatic/small intestinal disease.
- Recommend chronic probiotic therapy.
- If symptoms are persistent and there is no evidence of underlying metabolic disease, consider obtaining GI biopsies.

The pancreas is prominent and mottled with mildly reactive mesentery. These changes are most consistent with pancreatic inflammation, although due to the chronic nature of these symptoms, this could also be consistent with remodeling secondary to previous episodes of pancreatic inflammation.





The information and recommendations provided are based on the images presented by the referring veterinarian/sonographer. No evaluation can be communicated regarding pathology that was not visible in the image/video clips provided.

Thank you for this referral. If the clinical or image interpretation does not parallel your findings or if I can be of any further assistance please contact me.

Kathleen Sennello DVM,MS, Diplomate ACVIM (Small animal Internal Medicine)
info@sonopath.com