

**DATE**

8/13/21

PRESENTING CLINICAL SIGNS

History: Presented for panting a lot, drinking increased, decreased mobility. History of elevated ALKP.
Current Medications: Galliprant 100 mg SID, Gabapentin 600 mg BID, Apoquel.
Lab Results: CBC, Chem, Lytes- ALT 169, ALKP 605, Lateral chest and abdomen: NSF.
Radiographs: Not provided by the veterinarian.
Date of Previous IntraPet Ultrasound: No previous IntraPet scans.
Sedation: not needed
Stat Report: not requested

PATIENT

Thumper Willhide

SPECIES

Canine

BREED

Labrador

SEX

Neutered male

AGE

11/24/09

WEIGHT

110 lbs

INTERPRETED BY

Kathleen Sennello
DVM, MS, Diplomate
ACVIM (Small Animal
Internal Medicine)

HOSPITAL NAME

Hickory VH

REFERRING VET

Dr. Lyle

INVOICE

91208

ULTRASONOGRAPHIC EXAMINATION OF THE NORMAL**Urinary System**

The urinary bladder is moderately distended with anechoic urine. The Bladder wall, trigone, ureteral papillae and visible urethra (to a depth of 2cm) appear normal with no evidence of wall thickening, mucosal irregularities, masses or cystic calculi.

The prostate is normal in size and shape for this neutered male dog. The parenchyma is homogenous and the external margins are smooth. The prostatic urethra appears normal with no evidence of irregularity, invasion, mass effect or calculi.

The left kidney has a normal shape and size (XXcm). Overall echogenicity is slightly hyperechoic with poor corticomedullary distinction and a typical 1:3 cortex:medulla ratio. There is no evidence of perinephric inflammation or effusion. There is no evidence of pyelectasia, nephroliths, infarcts or hydroureter. Renal vasculature is normal.

The right kidney has a normal shape and size (7.4 cm). Overall echogenicity is slightly hyperechoic with poor corticomedullary distinction and a typical 1:3 cortex:medulla ratio. There is no evidence of perinephric inflammation or effusion. There is no evidence of pyelectasia, nephroliths, infarcts or hydroureter. Renal vasculature is normal. There is a 1.79 cm cortical cyst visualized.

Adrenal Glands

The left adrenal gland is borderline enlarged in size measuring 1.16 cm at the caudal pole It is observed in its normal position cranial to the left renal artery. It is normal in appearance (uniformly hypoechoic) and shape with no evidence of a mass effect.

The right adrenal gland is normal in size measuring XXcm at the caudal pole It is observed in its normal position between the cranial aspect of the right kidney and the caudal vena cava. It is normal in appearance (uniformly hypoechoic) and shape with no evidence of a mass effect.

Spleen

The spleen is subjectively normal in size (1.1 cm), echotexture is homogenous, and the splenic capsule is smooth with no irregularities. The blood flow through the hilus and splenic parenchyma appears normal. No focal parenchymal abnormalities are visualized.

Liver

The liver is subjectively normal in size, and echogenicity with smooth peripheral margins. The parenchyma is heterogenous in echotexture with subtle, indistinct focal mottling. The visible portions of the vasculature and biliary tract appear normal. No focal nodules or cystic lesions are observed. The gallbladder lumen is moderately distended. The wall of the gall bladder is not thickened and has a smooth mucosal surface. Luminal contents are primarily anechoic. The cystic and common bile ducts are normal/not visible.

Gastrointestinal

The stomach contains minimal luminal contents. It measures at a normal thickness of <0.7cm with some variability due to the presence of rugal folds. The distinction of the gastric wall layers is adequate and there is no impression of reduced peristaltic activity. No masses or focal lesions were observed.

The visualized areas of duodenum, jejunum and ileum have a relatively uniform diameter with minimal fluid distension. Wall thickness is normal. Bowel loops follow a curvilinear path with distinct wall layering maintaining the typical 1:3 muscularis:mucosa layer ratio. The duodenum measured as normal (between 0.3-0.5cm in wall thickness) and the jejunum measured as normal (between 0.2-0.47cm.) Visualized peristalsis appears appropriate. There were no focal lesions consistent with obstruction or a mass effect observed.

The ileocecal junction was visualized and exhibited normal intact wall layering and is subjectively of normal thickness. Sections of colon are visualized with formed fecal material and gas shadowing distally. There is no observed focal or generalized colon wall thickening or loss of layering.

Pancreas

The pancreas is normal and isoechoic to surrounding mesentery. There is no evidence of nodules or cystic lesions. There is no evidence of regional mesenteric inflammation or fluid.

Free Abdomen

Evaluation of the peritoneal cavity did not reveal any evidence of effusion, or subjective lymphadenomegaly. The Medial iliac nodes appear normal and there was no evidence of a caudal aortic thrombus at the bifurcation. The omentum is of normal uniform echogenicity.

ULTRASONOGRAPHIC FINDINGS

PRIMARY FINDINGS:

Borderline bilateral adrenomegaly. The bilateral adrenomegaly could be consistent with bilateral hyperplasia (e.g., secondary to pituitary-dependent hyperadrenocorticism), bilateral infiltrative neoplasia, inflammatory adrenal disease, other. Correlation with clinical findings is recommended.

Decreased corticomedullary distinction of both kidneys with a right-sided cortical cyst. Mild loss of corticomedullary distinction in both kidneys could be consistent with chronic degenerative disease or interstitial nephrosis. Right-sided cortical cysts.

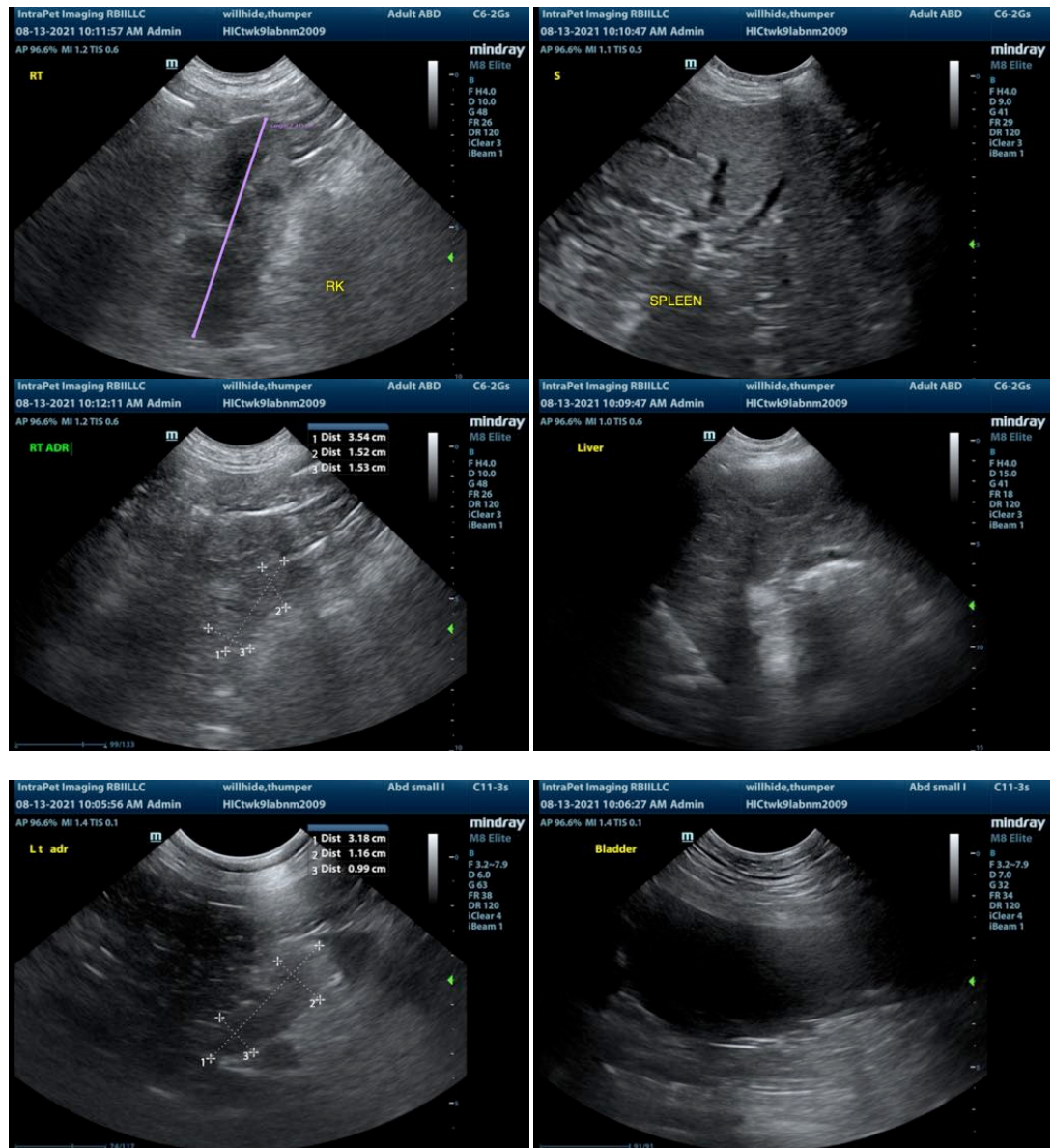
Heterogenous liver. The liver is subjectively (normal, large, small, normal/large, normal/small) in size, and echogenicity with smooth peripheral margins. The parenchyma is heterogenous in echotexture with subtle, indistinct focal mottling. The visible portions of the vasculature and biliary tract appear normal. No focal nodules or cystic lesions are observed.

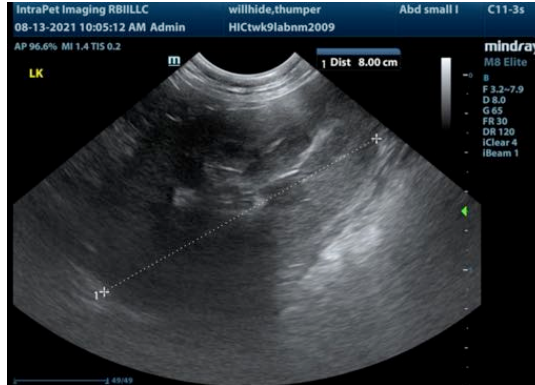
Mild gallbladder sludge. The gallbladder lumen is moderately distended. The wall of the gallbladder is not thickened and has a smooth mucosal surface. There is a moderate amount of non-organized echogenic debris. The cystic and common bile ducts are normal/not visible.

INTERPRETATION OF THE FINDINGS & FURTHER RECOMMENDATIONS

The changes observed in the liver were diffuse and non-specific. These changes combined with the bilateral adrenomegaly. There is increased concern for possible pituitary dependent Cushing's disease. If you feel that the patient would clinically benefit from treatment then consider further adrenal function testing for further evaluation.

Keep in mind some older dogs benefit from treatment of the Cushing's disease while you develop better muscle tone while some have a harder time with arthritis, allergies etc. Correlate these recommendations with the clinical picture.





The information and recommendations provided are based on the images presented by the referring veterinarian. No evaluation can be communicated regarding pathology that was not visible in the image/video clips provided.

Thank you for this referral. If the clinical or image interpretation does not parallel your findings or if I can be of any further assistance please contact me.

Kathleen Sennello DVM,MS, Diplomate ACVIM (Small animal Internal Medicine)
kathleen.sennello@sonopath.com