

**PATIENT**

Charlie Gallerani

SPECIES

Canine

BREED

Mixed

SEX

Neutered Male

AGE

7 Years

WEIGHT

14.8 Pounds

INTERPRETED BYKathleen Sennello DVM,
MS, Diplomate ACVIM
(Small Animal Internal
Medicine)**IMAGING
PERFORMED BY**

Amy Mayhew, LVT

HOSPITAL NAME

SVS Imaging MI

REFERRING VET

Rochester Vet Hospital

INVOICE

40390

DATE

8/12/22

PRESENTING CLINICAL SIGNS

GI issues

Abnormal PE/Chem/CBC/UA Results: Elevated ALP, mild liver enlargement **Please see attached records.

ULTRASONOGRAPHIC EXAMINATION OF THE ABDOMEN**Urinary System**

The urinary bladder is moderately distended with anechoic urine. The Bladder wall, trigone, ureteral papillae and visible urethra (to a depth of 2cm) appear normal with no evidence of wall thickening, mucosal irregularities, masses or cystic calculi.

The prostate is normal in size (0.63 cm) and shape for this neutered male dog. The parenchyma is homogenous and the external margins are smooth. The prostatic urethra appears normal with no evidence of irregularity, invasion, mass effect or calculi.

The left kidney has a normal shape and size (4.32 cm). Overall echogenicity is normal with adequate corticomedullary distinction and a typical 1:3 cortex:medulla ratio. There is no evidence of perinephric inflammation or effusion. There is no evidence of pyelectasia, nephroliths, infarcts or hydronephrosis. Renal vasculature is normal.

The right kidney has a normal shape and size (4.46 cm). Overall echogenicity is normal with adequate corticomedullary distinction and a typical 1:3 cortex:medulla ratio. There is no evidence of perinephric inflammation or effusion. There is no evidence of pyelectasia, nephroliths, infarcts or hydronephrosis. Renal vasculature is normal.

Adrenal Glands

The left adrenal gland is normal in size measuring 0.54 cm at the caudal pole. It is observed in its normal position cranial to the left renal artery. It is normal in appearance (uniformly hypoechoic) and shape with no evidence of a mass effect.

The right adrenal gland is normal in size measuring 0.42 cm at the caudal pole. It is observed in its normal position between the cranial aspect of the right kidney and the caudal vena cava. It is normal in appearance (uniformly hypoechoic) and shape with no evidence of a mass effect.

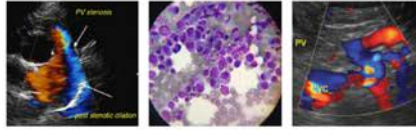
Spleen

The spleen is subjectively normal in size, echotexture is homogenous, and the splenic capsule is smooth with no irregularities. The blood flow through the hilus and splenic parenchyma appears normal. No focal parenchymal abnormalities are visualized.

Liver

The liver is large in size with smooth peripheral margins. The parenchyma is hyperechoic and homogenous in echotexture. The visible portions of the vasculature and biliary tract appear normal. No focal nodules or cystic lesions are observed.

The gall bladder lumen is moderately distended. The wall of the gall bladder is not thickened and has a smooth mucosal surface. There is a moderate amount of non-organized echogenic debris. The cystic and common bile ducts are normal/not visible.

**PATIENT**

Charlie Gallerani

SPECIES

Canine

BREED

Mixed

SEX

Neutered Male

AGE

7 Years

WEIGHT

14.8 Pounds

INTERPRETED BYKathleen Sennello DVM,
MS, Diplomate ACVIM
(Small Animal Internal
Medicine)**IMAGING
PERFORMED BY**

Amy Mayhew, LVT

HOSPITAL NAME

SVS Imaging MI

REFERRING VET

Rochester Vet Hospital

INVOICE

40390

DATE

8/12/22

Gastrointestinal

The stomach is moderately dilated with fluid and irregular shadowing material most consistent with normal ingesta and gas. It measures at a normal thickness of <0.7cm with some variability due to the presence of rugal folds. The distinction of the gastric wall layering is adequate and there is no impression of reduced peristaltic activity. No masses or focal lesions were observed.

The visualized areas of duodenum, jejunum and ileum have a uniform diameter with minimal fluid distension. Wall thickness is moderately increased. Jejunum wall measured 0.27 cm. Duodenum wall measured 0.52 cm with diffuse mucosal speckling. Bowel loops follow a typical curvilinear path. Some areas have reduced detail of wall layering. Visualized peristalsis appears appropriate. There were no focal lesions consistent with obstruction or a mass effect observed.

The ileocecal junction was visualized and exhibited normal intact wall layering and is subjectively of normal thickness. Sections of colon are visualized with formed fecal material and gas shadowing distally. There is no observed focal or generalized colon wall thickening or loss of layering.

Pancreas

The pancreas is normal and isoechoic to surrounding mesentery. There is no evidence of nodules or cystic lesions. There is no evidence of regional mesenteric inflammation or fluid.

Free Abdomen

Evaluation of the peritoneal cavity did not reveal any evidence of effusion, or subjective lymphadenomegaly. The Medial iliac nodes appear normal and there was no evidence of a caudal aortic thrombus at the bifurcation. The omentum is diffusely mildly hyperechoic.

ULTRASONOGRAPHIC FINDINGS

- Large, hyperechoic liver – The diffuse hepatic changes are non-specific and can be seen with vacuolar hepatopathy, reactive change, nodular hyperplasia or, less likely, inflammatory/immune-mediated disease, infiltrative neoplasia, or other hepatopathy.
- Moderate gallbladder debris – The significance of the aggregated gallbladder sludge is unclear. This could represent an early mucocele, cholestasis, or may be secondary to fasting.
- Moderate shadowing material visualized within the gastric lumen - Correlate with feedings history and abdominal radiographs. If adequately fasted then consider such differentials as delayed gastric emptying or a partial outflow tract obstruction (none visualized).
- Mild small intestinal thickening with prominent mucosal speckling – Bright mucosal speckling has been proposed to represent dilated lacteals or focal accumulation of mucus, cellular debris etc.. in the mucosal crypts of the small intestine.

INTERPRETATION OF THE FINDINGS & FURTHER RECOMMENDATIONS

The bowel appears subjectively thickened with mucosal speckling. These changes are concerning for primary gastrointestinal disease. Consider such differentials as food allergy/dietary intolerance, IBD, lymphangiectasia, and less likely infiltrative neoplasia (other differentials exist).

- Recommend a novel protein/hydrolyzed protein prescription diet.
- Recommend chronic probiotic therapy.
- Recommend a GI panel to Texas A&M for a qualitative PLI, TLI, cobalamin and folate to thoroughly evaluate the pancreas and small intestine.
- Consider three view thoracic radiographs to rule out concurrent thoracic disease/involvement.
- If symptoms persist, consider obtaining GI biopsies.

IMAGING PERFORMED BY

SVS Mobile Imaging MI 734-637-7711
svsimagingmi@gmail.com



EDUCATIONAL TELECONSULTATION SERVICES™
1-800-838-4268 info@sonopath.com SonoPath.com

PATIENT

Charlie Gallerani

No focal lesions were observed in the liver. The changes observed are non-specific. Options moving forward include continued monitoring or you could consider a liver function test and a fine needle aspirate of the liver, provided coagulation parameters are normal.

SPECIES

Canine

There is moderate debris visualized within the gallbladder. Recommend continued monitoring of the gallbladder for progression of this lesion.

BREED

Mixed

SEX

Neutered Male

AGE

7 Years

WEIGHT

14.8 Pounds

INTERPRETED BY

Kathleen Sennello DVM,
MS, Diplomate ACVIM
(Small Animal Internal
Medicine)

IMAGING PERFORMED BY

Amy Mayhew, LVT

HOSPITAL NAME

SVS Imaging MI

REFERRING VET

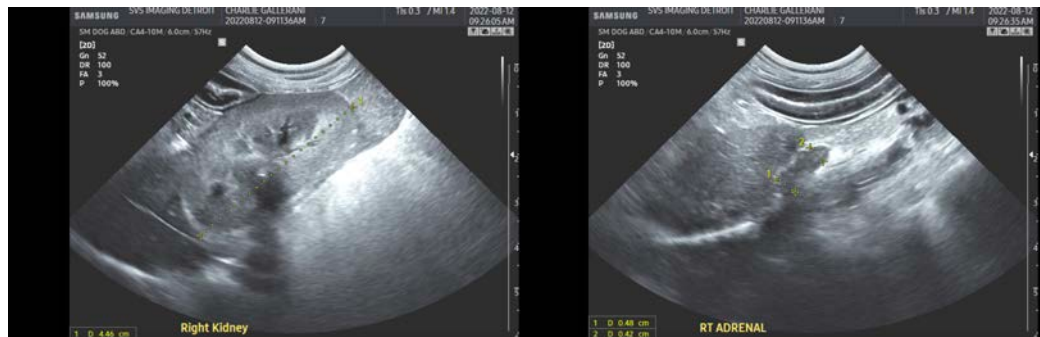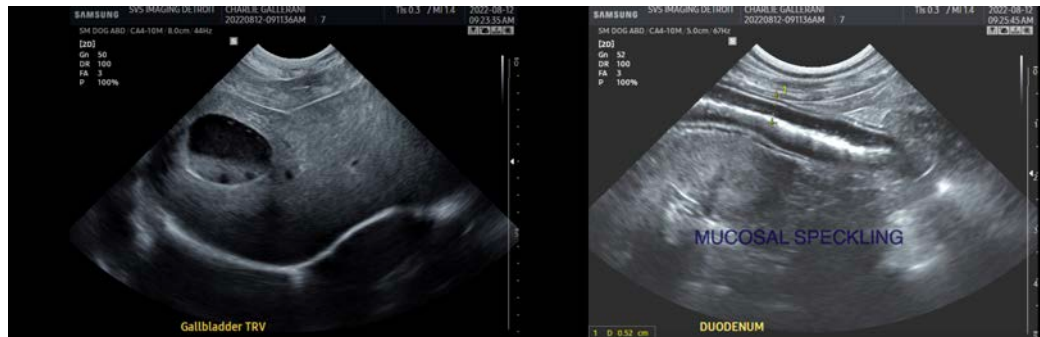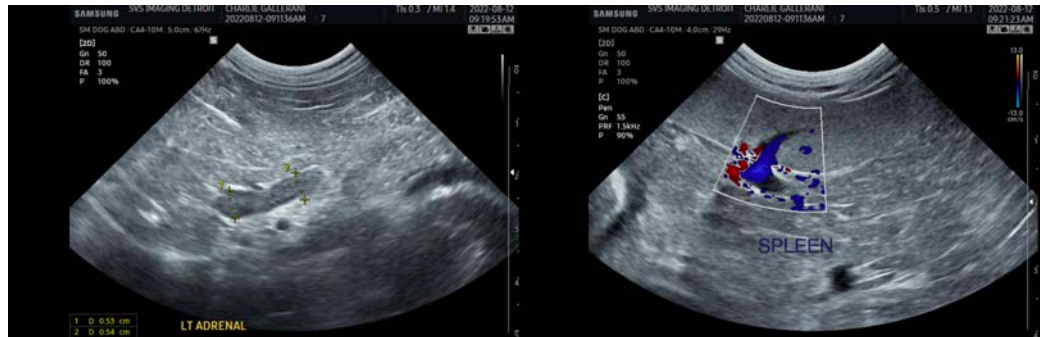
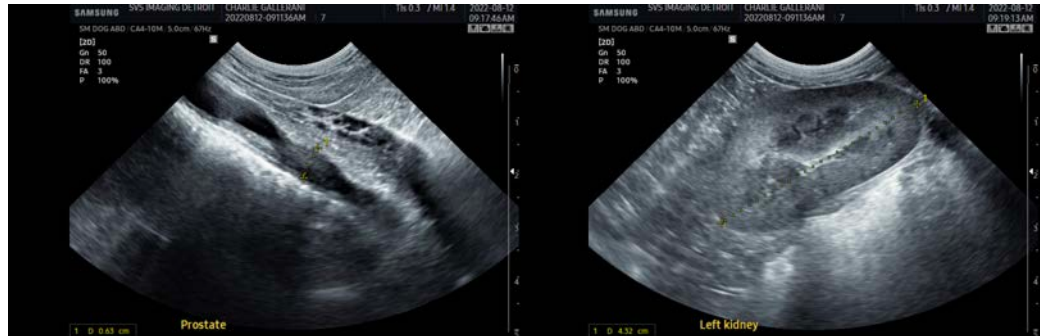Rochester Vet Hospital

INVOICE

40390

DATE

8/12/22



IMAGING PERFORMED BY

SVS Mobile Imaging MI 734-637-7711
svsimagingmi@gmail.com



PATIENT

Charlie Gallerani

SPECIES

Canine

BREED

Mixed

SEX

Neutered Male

AGE

7 Years

WEIGHT

14.8 Pounds

INTERPRETED BY

Kathleen Sennello DVM,
MS, Diplomate ACVIM
(Small Animal Internal
Medicine)

**IMAGING
PERFORMED BY**

Amy Mayhew, LVT

HOSPITAL NAME

SVS Imaging MI

REFERRING VET

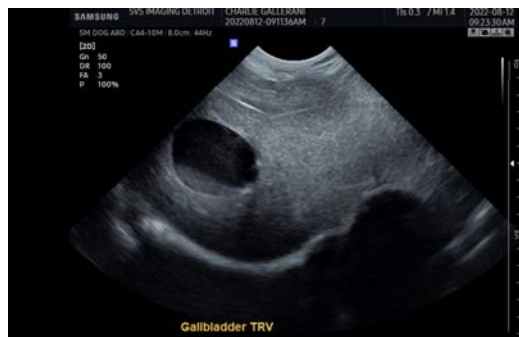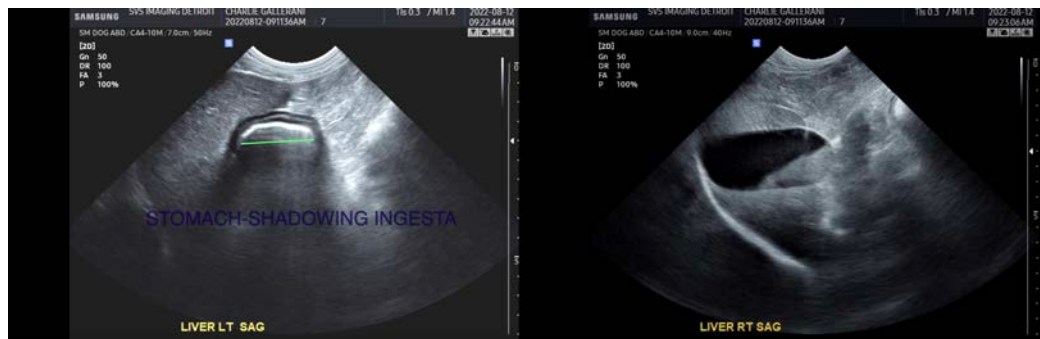
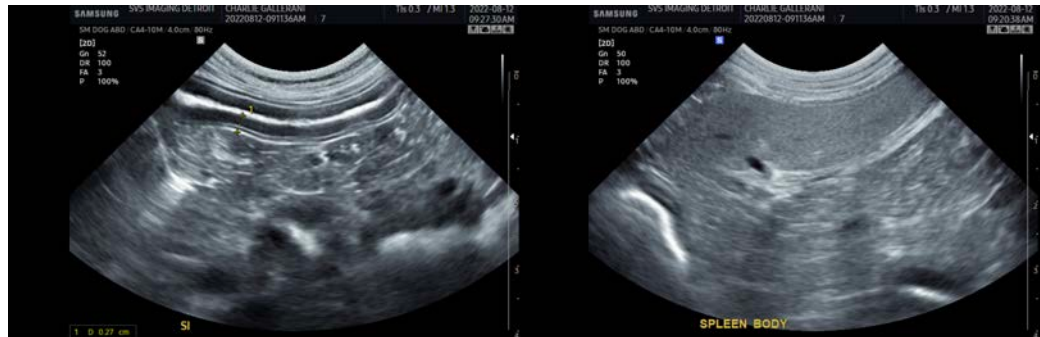
Rochester Vet Hospital

INVOICE

40390

DATE

8/12/22



The information and recommendations provided are based on the images presented by the referring veterinarian/sonographer. No evaluation can be communicated regarding pathology that was not visible in the image/video clips provided.

Thank you for this referral. If the clinical or image interpretation does not parallel your findings or if I can be of any further assistance please contact me.

Kathleen Sennello DVM,MS, Diplomate ACVIM (Small animal Internal Medicine)

kathleen.sennello@sonopath.com