

**DATE**

8/12/21

PRESENTING CLINICAL SIGNS

History: Cutaneous mast cell tumor.
Current Medications: No current medications.
Lab Results: monocytosis and increased BUN
Radiographs: Not provided by the veterinarian.
Date of Previous IntraPet Ultrasound: No previous IntraPet scans.
Sedation: Gabapentin PO prior to scan.
Stat Report: STAT report not requested by the veterinarian.

PATIENT

Jinx Horrom

SPECIES

Feline

BREED

Maine Coon

SEX

Spayed Female

AGE

4/20/05

WEIGHT

12 lbs

INTERPRETED BY

Kathleen Sennello
DVM, MS, Diplomate
ACVIM (Small Animal
Internal Medicine)

HOSPITAL NAME

North Laurel AH

REFERRING VET

Dr. Russo

INVOICE

91174

ULTRASONOGRAPHIC EXAMINATION OF THE ABDOMEN**Urinary System**

The urinary bladder is moderately distended with anechoic urine. The Bladder wall, trigone, ureteral papillae and visible urethra (to a depth of 2cm) appear normal with no evidence of wall thickening, mucosal irregularities, masses or cystic calculi.

The left kidney has a normal shape and size (4.0 cm). Overall echogenicity is slightly hyperechoic with poor corticomedullary distinction and a typical 1:3 cortex:medulla ratio. There is no evidence of perinephric inflammation or effusion. There is no evidence of pyelectasia, nephroliths, infarcts or hydroureter. Renal vasculature is normal.

The right kidney has a normal shape and size (3.46 cm). Overall echogenicity is slightly hyperechoic with poor corticomedullary distinction and a typical 1:3 cortex:medulla ratio. There is no evidence of perinephric inflammation or effusion. There is no evidence of pyelectasia, nephroliths, infarcts or hydroureter. Renal vasculature is normal.

Adrenal Glands

The region of left adrenal (Cranial to left renal artery) is unremarkable but the adrenal is not distinctly visualized. No evidence of a mass effect.

The region of the right adrenal (between right cranial kidney and vena cava) is unremarkable, but the adrenal is not distinctly visualized. No evidence of a mass effect.

Spleen

The spleen is subjectively normal in size, echotexture is homogenous, and the splenic capsule is smooth with no irregularities. The blood flow through the hilus and splenic parenchyma appears normal. No focal parenchymal abnormalities are visualized.

Liver

The liver is subjectively normal in size, and echogenicity with smooth peripheral margins. The parenchyma is homogenous echotexture. The visible portions of the vasculature and biliary tract appear normal. There is a small 0.86 x 0.66 cm cyst visualized. The gallbladder lumen is moderately distended. The wall of the gall bladder is not thickened and has a smooth mucosal surface. Luminal contents are primarily anechoic. The cystic and common bile ducts are normal/not visible.

Gastrointestinal

The stomach contains minimal luminal contents. It measures at a normal thickness of <0.36cm with some variability due to the presence of rugal folds. The distinction of the gastric wall layers is adequate and there is no impression of reduced peristaltic activity. No masses or focal lesions were observed.

The visualized areas of duodenum, jejunum and ileum have a uniform diameter with minimal fluid distension. Wall thickness is normal to slightly increased. Bowel loops follow a typical curvilinear path with distinct wall layering, but some areas display a prominent muscularis layer which does not display the typical 1:3 muscularis:mucosa layer ratio. The jejunum measures 0.34 cm. Visualized peristalsis appears appropriate. There were no focal lesions consistent with obstruction or a mass effect observed.

The ileocecal junction was visualized and exhibited normal intact wall layering and is subjectively of normal thickness. Sections of colon are visualized with formed fecal material and gas shadowing distally. There is no observed focal or generalized colon wall thickening or loss of layering.

Pancreas

The pancreas is prominent and hypoechoic as compared to the surrounding isoechoic mesentery. There is no evidence of nodules or cystic lesions. There is no evidence of regional mesenteric inflammation or fluid.

Free Abdomen

Evaluation of the peritoneal cavity did not reveal any evidence of effusion, or subjective lymphadenomegaly. The Medial iliac nodes appear normal and there was no evidence of a caudal aortic thrombus at the bifurcation. The omentum is of normal uniform echogenicity.

Heart

A brief view of the heart was submitted. No pericardial effusion was seen. There was some mild irregularity noted to the pleura and ring down artifact indicating possible parenchymal abnormalities.

ULTRASONOGRAPHIC FINDINGS

PRIMARY FINDINGS:

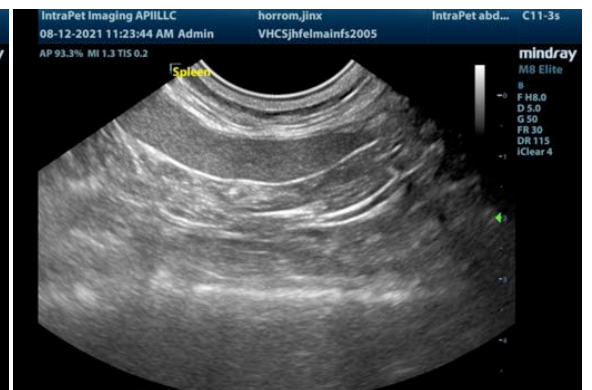
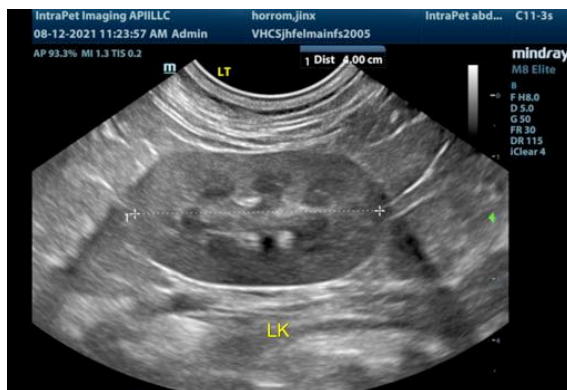
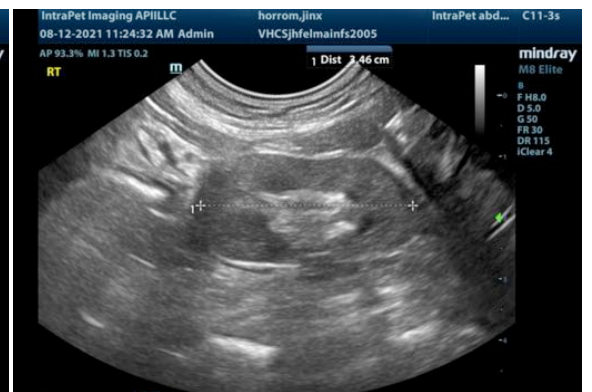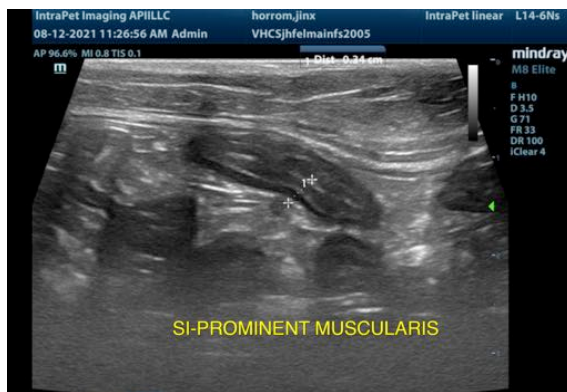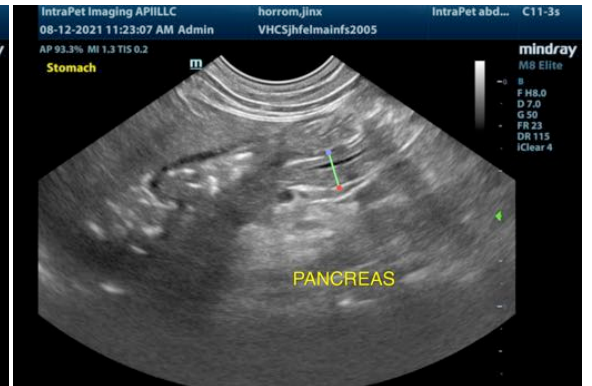
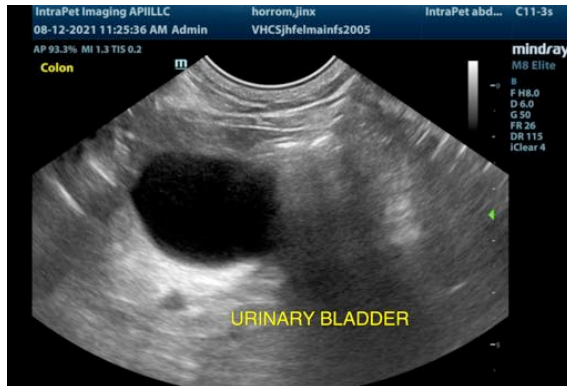
- Decreased corticomedullary distinction in both kidneys. Mild loss of corticomedullary distinction in both kidneys could be consistent with chronic degenerative disease or interstitial nephrosis.
- Prominent muscularis layer to the small intestine. The small intestinal wall changes are most consistent with an inflammatory process (i.e., inflammatory bowel disease) with a low possibility of emerging lymphoma.
- Ring down artifact noted indicating possible pulmonary parenchymal abnormalities and irregular pleura. I recommend thoracic radiographs.

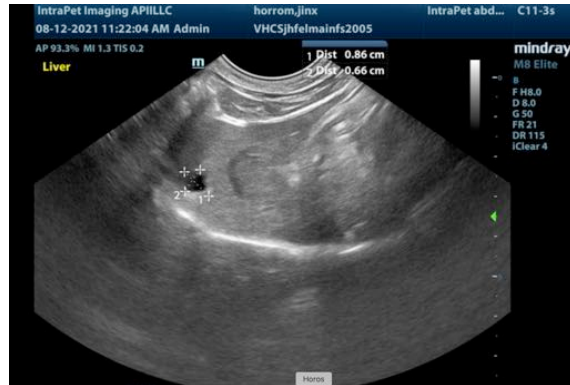SECONDARY FINDINGS:

- Small hepatic cysts observed. This is likely an incidental finding.
- Prominent, hypoechoic pancreas. The pancreatic changes are most consistent with age-related parenchymal remodeling, potentially secondary to a prior inflammatory episode, early fibrosis or chronic pancreatitis.

INTERPRETATION OF THE FINDINGS & FURTHER RECOMMENDATIONS

There is no obvious evidence of metastasis observed. The renal intestinal changes can be associated with aging change and early renal disease. I recommend urinalysis and culture along with blood pressure evaluation to further evaluate the renal disease present. I recommend three view thoracic radiographs.





The information and recommendations provided are based on the images presented by the referring veterinarian. No evaluation can be communicated regarding pathology that was not visible in the image/video clips provided.

Thank you for this referral. If the clinical or image interpretation does not parallel your findings or if I can be of any further assistance please contact me.

Kathleen Sennello DVM,MS, Diplomate ACVIM (Small animal Internal Medicine)
kathleen.sennello@sonopath.com