

**DATE**

8/12/21

PRESENTING CLINICAL SIGNS

History of 7lbs weight loss in last 6 months. Vomiting and not eating starting this past weekend. BW showed mildly elevated ALT, significantly elevated ALKP, and significantly elevated GGT.

PATIENT

Cooper Hammel

Serum mildly icteric.

Current Medications: Amoxicillin 500mg Caps, Metronidazole 500 mg.

Lab Results: Attached

Radiographs: None

SPECIES

Canine

Date of Previous IntraPet Ultrasound: No previous

Sedation: not needed

Stat Report: not requested

BREED

Golden Retriever

ULTRASONOGRAPHIC EXAMINATION OF THE ABDOMEN**Urinary System**

The urinary bladder is moderately distended with anechoic urine. The Bladder wall, trigone, ureteral papillae and visible urethra (to a depth of 2cm) appear normal with no evidence of wall thickening, mucosal irregularities, masses or cystic calculi.

SEX

Neutered male

The prostate is normal in size (1.2 cm) and shape for this neutered male dog. The parenchyma is homogenous and the external margins are smooth. The prostatic urethra appears normal with no evidence of irregularity, invasion, mass effect or calculi.

AGE

2009

The left kidney has a normal shape and size (8.19 cm). Overall echogenicity is normal with adequate corticomedullary distinction and a typical 1:3 cortex:medulla ratio. There is no evidence of perinephric inflammation or effusion. There are pinpoint, non-obstructive nephroliths. There is no evidence of pyelectasia, infarcts or hydroureter. Renal vasculature is normal.

WEIGHT

86.4 lbs

The right kidney has a normal shape and size (7.94 cm). Overall echogenicity is normal with adequate corticomedullary distinction and a typical 1:3 cortex:medulla ratio. There is no evidence of perinephric inflammation or effusion. There are non-obstructive pinpoint nephroliths. There is no evidence of pyelectasia, infarcts or hydroureter. Renal vasculature is normal.

INTERPRETED BY

Kathleen Sennello
DVM, MS, Diplomate
ACVIM (Small Animal
Internal Medicine)

Adrenal Glands

The left adrenal gland is normal/borderline enlarged in size measuring 0.87 cm at the caudal pole It is observed in its normal position cranial to the left renal artery. It is normal in appearance (uniformly hypochoic) and shape with no evidence of a mass effect.

HOSPITAL NAME

Bayside Animal
Medical Center

The right adrenal gland is normal/borderline enlarged in size measuring 0.94 cm at the caudal pole It is observed in its normal position between the cranial aspect of the right kidney and the caudal vena cava. It is normal in appearance (uniformly hypochoic) and shape with no evidence of a mass effect.

REFERRING VET**Spleen**

The spleen is subjectively (normal or large) in size. The spleen echotexture is heterogenous and mottled, the splenic capsule is smooth with no irregularities. The blood flow through the hilus and splenic parenchyma appears normal. Rare, discrete, focal, hyperechoic perivascular abnormalities are present. The appearance of these lesions is most consistent with benign splenic myelolipomas.

INVOICE

91187

Liver

The liver is subjectively large in size, and echogenicity with smooth peripheral margins. The parenchyma is heterogenous in echotexture with subtle, indistinct focal mottling. The visible portions of the vasculature and biliary tract appear normal. There are too numerous to count, ill-defined, hypoechoic nodules throughout the hepatic parenchyma. Additionally there is a discrete, hypoechoic mass observed on the left side measuring 4.88 x 3.88 cm. The gallbladder lumen is significantly distended. The wall of the gallbladder is somewhat thickened and hypoechoic with echogenic luminal contents that appear to be starting to organize into an early mucocele. There is no surrounding inflammation or fluid. The cystic and common bile ducts are normal/not visible.

Gastrointestinal

The stomach is significantly dilated with irregular shadowing material. This may be consistent with ingesta and gas, but is also concerning for the possibility of foreign material. The visible areas of the stomach wall appear normal with a thickness of less than 0.7 cm with some variability due to the presence of rugal folds. The distinction of gastric layering is adequate and there is no impression of reduced peristaltic activity.

The visualized areas of duodenum, jejunum and ileum have a relatively uniform diameter with minimal fluid distension. Wall thickness is normal. Bowel loops follow a curvilinear path with distinct wall layering maintaining the typical 1:3 muscularis:mucosa layer ratio. The duodenum measured as normal (0.47 cm in wall thickness) and the jejunum measured as normal (0.36 cm, 0.39 cm). Visualized peristalsis appears appropriate. There were no focal lesions consistent with obstruction or a mass effect observed.

The ileocecal junction was visualized and exhibited normal intact wall layering and is subjectively of normal thickness. Sections of colon are visualized with formed fecal material and gas shadowing distally. There is no observed focal or generalized colon wall thickening or loss of layering.

Pancreas

The pancreas is normal and isoechoic to surrounding mesentery. There is no evidence of nodules or cystic lesions. There is no evidence of regional mesenteric inflammation or fluid.

Free Abdomen

Evaluation of the peritoneal cavity did not reveal any evidence of effusion, or subjective lymphadenomegaly. The Medial iliac nodes appear normal and there was no evidence of a caudal aortic thrombus at the bifurcation. The omentum is generally of increased echogenicity.

ULTRASONOGRAPHIC FINDINGS

PRIMARY FINDINGS:

- Large, heterogenous liver with indistinct, hypoechoic nodules and a distinct, hypoechoic mass on the left side. The diffuse hepatic changes are non-specific and could be consistent with vacuolar hepatopathy, nodular hyperplasia, inflammatory/immune-mediated disease, fibrosis, extramedullary hematopoiesis, toxic hepatopathy (e.g., copper), infiltrative neoplasia (less likely) or other hepatopathy.
- Large gallbladder sludge with early organization, suggestive of an early mucocele. There is no evidence of surrounding gallbladder inflammation at this time. Consider monitoring closely and starting Ursodiol.
- Shadowing material in the gastric lumen. Correlate with feeding history and radiographs. This could be ingesta or ingested foreign material.

- Subjectively thickened small intestine. The bowel wall thickening could be consistent with inflammation, edema, or infiltrative neoplasia.
- Mottled spleen. The spleen is subjectively (normal or large) in size. The spleen echotexture is heterogenous and mottled, the splenic capsule is smooth with no irregularities. The blood flow through the hilus and splenic parenchyma appears normal. No focal parenchymal abnormalities are visualized.

SECONDARY FINDINGS:

- Borderline, bilateral adrenomegaly. The bilateral adrenomegaly could be consistent with bilateral hyperplasia (e.g., secondary to pituitary-dependent hyperadrenocorticism), bilateral infiltrative neoplasia, inflammatory adrenal disease, other. Correlation with clinical findings is recommended.

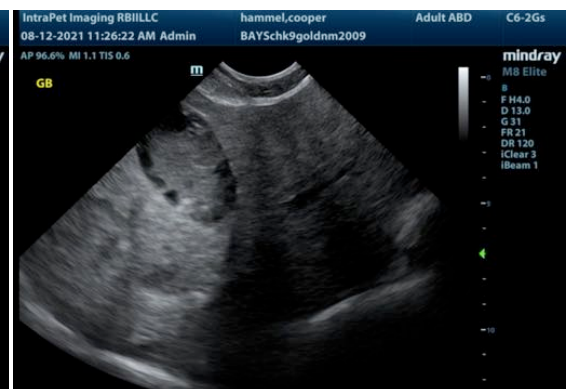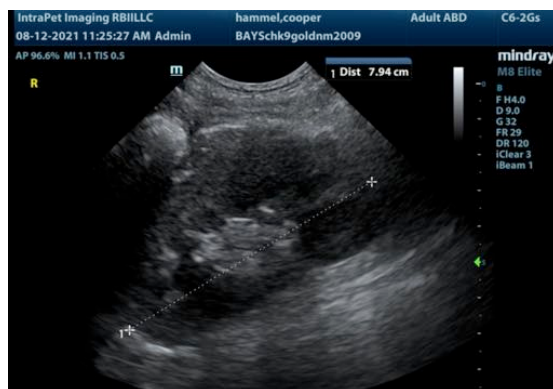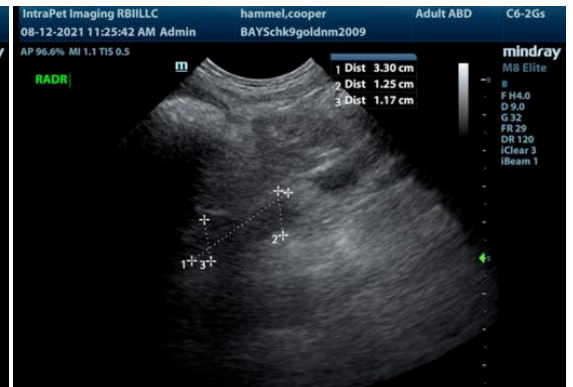
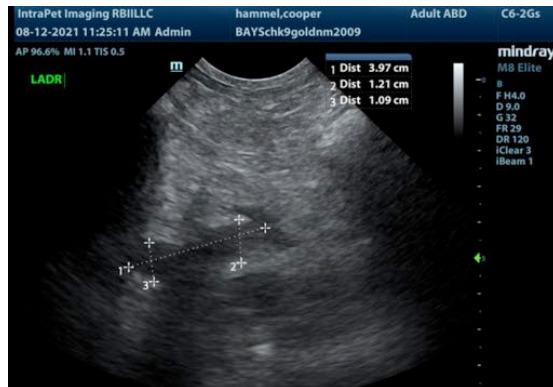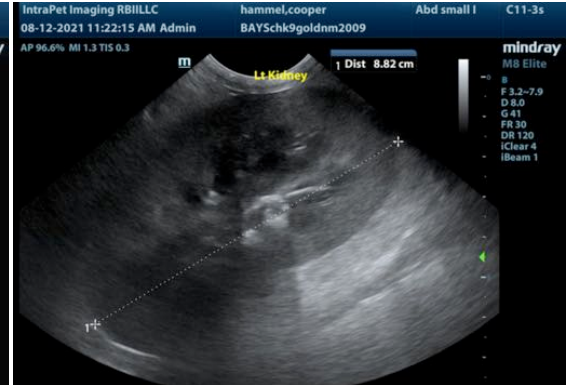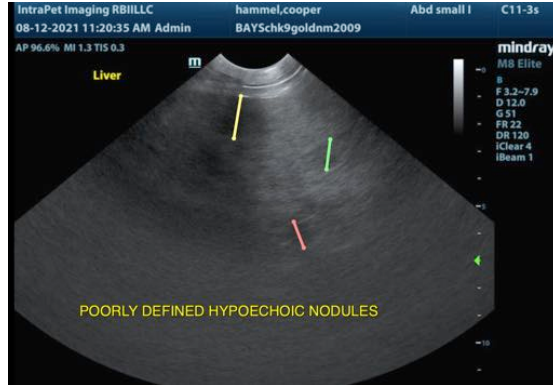
INTERPRETATION OF THE FINDINGS & FURTHER RECOMMENDATIONS

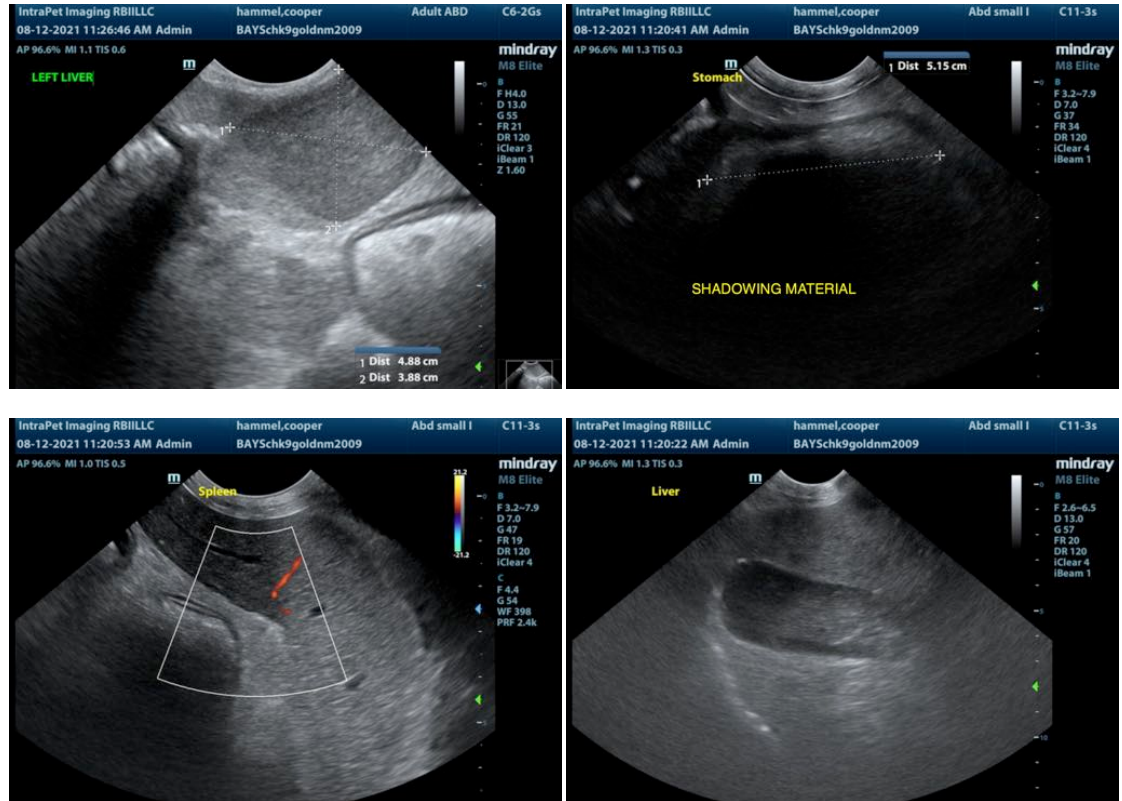
There is a lot going on in this older dog's abdomen. The liver changes may be benign or represent malignant change. I recommend evaluation of a bilirubin level as this would be very helpful. FNA of the liver and liver mass could be considered. Indistinct nodular could be consistent with regenerative nodules and it is possible that this pet has early Cushing's disease based on the size of the adrenal glands. Consider liver function testing and liver biopsy/hepatic mass removal. I recommend three view thoracic radiographs.

Additionally the gallbladder is abnormal. It does look like an inflamed mucocele, but it is concerning. If the liver mass is removed I recommend evaluation by a board certified veterinary surgeon who can evaluate the gallbladder at the same time. I recommend starting Ursodiol.

Additionally, there is foreign material in the stomach. The significance of this is unclear. Correlate with abdominal radiographs. This is unlikely to be the cause of weight loss, but can be correlated with recent vomiting.

Additionally, the small intestine appears somewhat thickened and inflamed. Consider GI panel to look for evidence of pancreatitis and small intestinal disease. It is difficult with this dog to determine what is truly the current active problem. I suspect that the liver mass and elevation in liver enzymes have been chronic and possibly there is Cushing's going on as well. These changes could cause weight loss over time and inappetence, but if there is acute vomiting present that could be due to acute gastroenteritis, foreign material in the stomach, etc. I recommend supportive care, full blood work with bilirubin, calcium, etc. A liver function test if bilirubin is normal, FNA of liver and liver mass +/- splenic aspirate and serial monitoring of the stomach with radiographs. If the patient is not improving you can consider surgical intervention for all of these concerns. Additionally if the patient is starting to feel better you can let him stabilize and then consider going back to address some of these issues.





The information and recommendations provided are based on the images presented by the referring veterinarian. No evaluation can be communicated regarding pathology that was not visible in the image/video clips provided.

Thank you for this referral. If the clinical or image interpretation does not parallel your findings or if I can be of any further assistance please contact me.

Kathleen Sennello DVM,MS, Diplomate ACVIM (Small animal Internal Medicine)
 kathleen.sennello@sonopath.com