

PATIENT

Coco Shoberg

PRESENTING CLINICAL SIGNS

Chemistry profile - BUN 34 Creat 1.3 PSL 31 else unremarkable; Thyroid hormones - T4 = 2.2; CBC - Neuts 1554 pending path review, else unremarkable.; Urinalysis - USG 1.017 protein 1+ occult blood 1+ RBC 2-3 else unremarkable ASSESSMENTS Neutropenia - moderate, CKD IRIS stage 2, Weight decreased Persistent neutropenia more pronounced than on prior labs, stable renal disease at CKD IRIS stage 2, r/o suspect geriatric patient normal vs. unlikely retroviral/toxo/bartonellosis/other. Appetite OK

SPECIES

Feline

BREED

DSH

ULTRASONOGRAPHIC EXAMINATION OF THE ABDOMEN

Urinary System

SEX

Neutered Male

The urinary bladder is moderately distended with anechoic urine. The Bladder wall, trigone, ureteral papillae and visible urethra (to a depth of 2cm) appear normal with no evidence of wall thickening, mucosal irregularities, masses or cystic calculi.

AGE

16 Years

The left kidney is normal in size (2.32 cm), yet very irregular in shape. Overall echogenicity is increased with significant decrease in distinction of the corticomedullary junction. There is no evidence of perinephric inflammation. There is free abdominal fluid. There is no evidence of pyelectasia, obstructive nephroliths or hydroureter. Renal vasculature is normal.

WEIGHT

8 Pounds

The right kidney is normal in size (2.8 cm), yet very irregular in shape. Overall echogenicity is increased with significant decrease in distinction of the corticomedullary junction. There is no evidence of perinephric inflammation. There is free abdominal fluid. There is no evidence of pyelectasia, obstructive nephroliths or hydroureter. Renal vasculature is normal.

INTERPRETED BY

Kathleen Sennello DVM,
MS, Diplomate ACVIM
(Small Animal Internal
Medicine)

Adrenal Glands

The left adrenal gland is normal in size measuring 0.33 cm at the caudal pole. It is observed in its normal position cranial to the left renal artery. It is normal in appearance (uniformly hypoechoic) and shape with no evidence of a mass effect.

IMAGING PERFORMED BY

Loetitia Saint-Jacques, RVT

The right adrenal gland is normal in size measuring 0.23 cm at the caudal pole. It is observed in its normal position between the cranial aspect of the right kidney and the caudal vena cava. It is normal in appearance (uniformly hypoechoic) and shape with no evidence of a mass effect.

HOSPITAL NAME

VCA Feline AH

Spleen

The spleen is large in size. The echotexture is largely homogeneous and hypoechoic. The splenic capsule is smooth with no irregularities, but appears somewhat swollen. The blood flow through the hilus and splenic parenchyma appears normal. There is a 0.57 cm irregular, hyperechoic lesion observed.

REFERRING VET

Dr. Vincent Fleming

Liver

The liver is large in size, and echogenicity with smooth peripheral margins. The parenchyma is heterogenous in echotexture with subtle, indistinct focal mottling. The visible portions of the vasculature and biliary tract appear normal. No focal nodules or cystic lesions are observed.

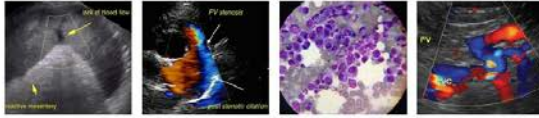
INVOICE

24611

The gallbladder lumen is moderately distended. The wall of the gall bladder is not thickened and has a smooth mucosal surface. Luminal contents are primarily anechoic. The cystic and common bile ducts are normal/not visible.

DATE

8/12/21



PATIENT

Coco Shoberg

Gastrointestinal

The stomach contains minimal luminal contents. It measures at a normal thickness of <0.36cm with some variability due to the presence of rugal folds. The distinction of the gastric wall layers is adequate and there is no impression of reduced peristaltic activity. No masses or focal lesions were observed.

SPECIES

Feline

The visualized areas of duodenum, jejunum and ileum have a relatively uniform diameter with minimal fluid distension. Wall thickness is normal. Bowel loops follow a curvilinear path with distinct wall layering maintaining the typical 1:3 muscularis:mucosa layer ratio. Jejunum wall measures 0.26 cm. Visualized peristalsis appears appropriate. There were no focal lesions consistent with obstruction or a mass effect observed.

BREED

DSH

SEX

Neutered Male

The ileocecal junction was visualized and exhibited normal intact wall layering and is subjectively of normal thickness. Sections of colon are visualized with formed fecal material and gas shadowing distally. There is no observed focal or generalized colon wall thickening or loss of layering.

Pancreas

AGE

16 Years

The pancreas is normal and isoechoic to surrounding mesentery. There is no evidence of nodules or cystic lesions. There is no evidence of regional mesenteric inflammation or fluid.

Free Abdomen

WEIGHT

8 Pounds

Evaluation of the peritoneal cavity revealed a large volume of anechoic free fluid. Very mild mesenteric lymphadenopathy is noted (an occasional mesenteric lymph node is observed measuring between 0.25-0.35 cm). The Medial iliac nodes appear normal and there was no evidence of a caudal aortic thrombus at the bifurcation. The omentum is of normal uniform echogenicity.

INTERPRETED BY

Kathleen Sennello DVM,
MS, Diplomate ACVIM
(Small Animal Internal
Medicine)

Other

A brief view of the heart was submitted. No pericardial effusion was seen.

IMAGING PERFORMED BY

Loetitia Saint-Jacques, RVT

ULTRASONOGRAPHIC FINDINGS

- Enlarged, hypoechoic spleen with indistinct hyperechoic foci – differentials include lymphoid hyperplasia, extramedullary hematopoiesis, infiltrative neoplasia, inflammation, other. Cytology or histopathology would be necessary to get a definitive diagnosis.
- Large, heterogeneous liver – Hepatic changes are non-specific and could be consistent with hepatic lipidosis, inflammatory/infectious disease, infiltrative neoplasia, or other hepatopathy.
- Irregular, hyperechoic kidneys with loss of corticomedullary distinction – Mild loss of corticomedullary distinction in both kidneys could be consistent with chronic degenerative disease or interstitial nephrosis.
- Large volume free abdominal fluid – General causes include decreased oncotic pressure, increased hydrostatic pressure, vasculitis (inflammation), paraneoplastic effusions, etc.

HOSPITAL NAME

VCA Feline AH

REFERRING VET

Dr. Vincent Fleming

INVOICE

24611

DATE

8/12/21

INTERPRETATION OF THE FINDINGS & FURTHER RECOMMENDATIONS

Both the spleen and liver appear to have very atypical parenchyma, and they appear rounded and swollen. Recommend fine needle aspirate of these organs as long as clotting parameters are normal. Additionally consider sample of free abdominal fluid for cytology and fluid analysis. Recommend 3-view thoracic radiographs, and if azotemia worsens, you could also consider a fine needle aspirate of the kidneys, as they are rounded and irregular. Recommend blood pressure evaluation, urinalysis and



PATIENT

Coco Shoberg culture, and possible urine protein/creatinine ratio.

SPECIES

Feline

BREED

DSH

SEX

Neutered Male

AGE

16 Years

WEIGHT

8 Pounds

INTERPRETED BY

Kathleen Sennello DVM,
MS, Diplomate ACVIM
(Small Animal Internal
Medicine)

IMAGING PERFORMED BY

Loetitia Saint-Jacques, RVT

HOSPITAL NAME

VCA Feline AH

REFERRING VET

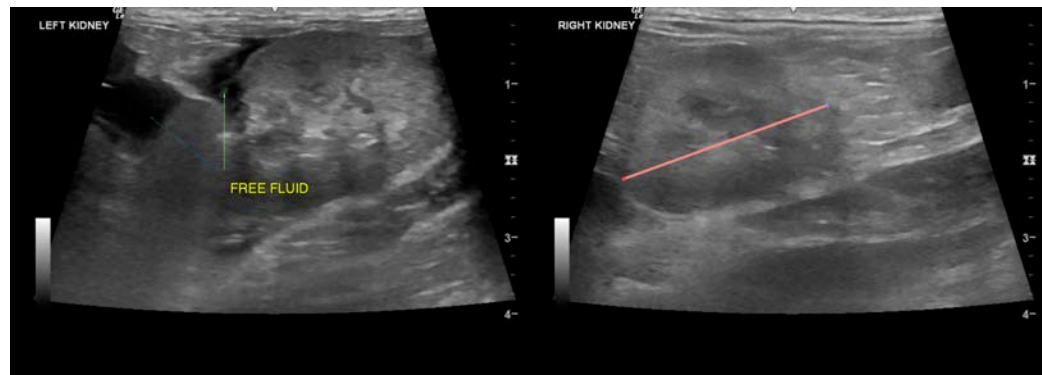
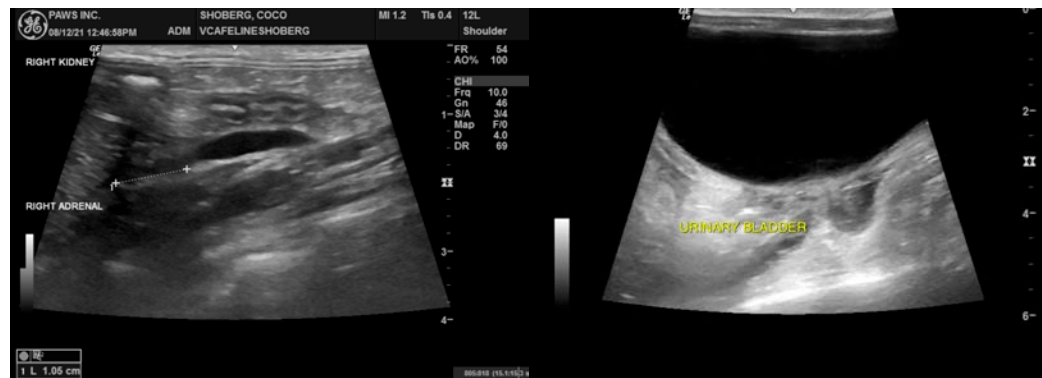
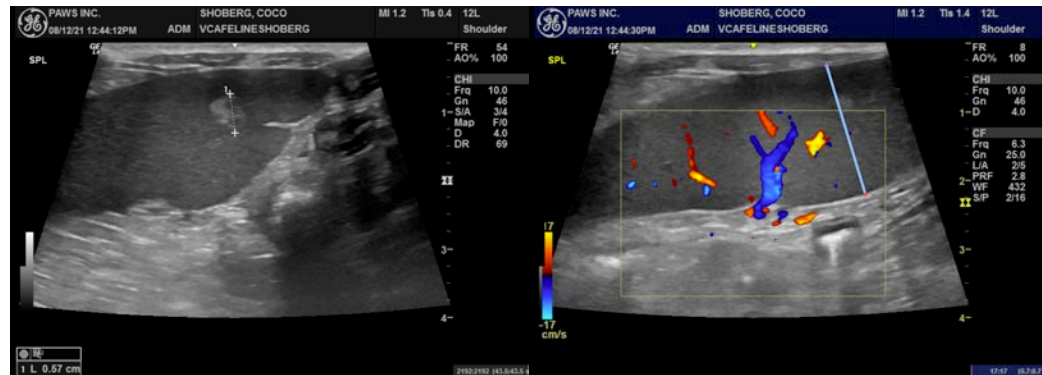
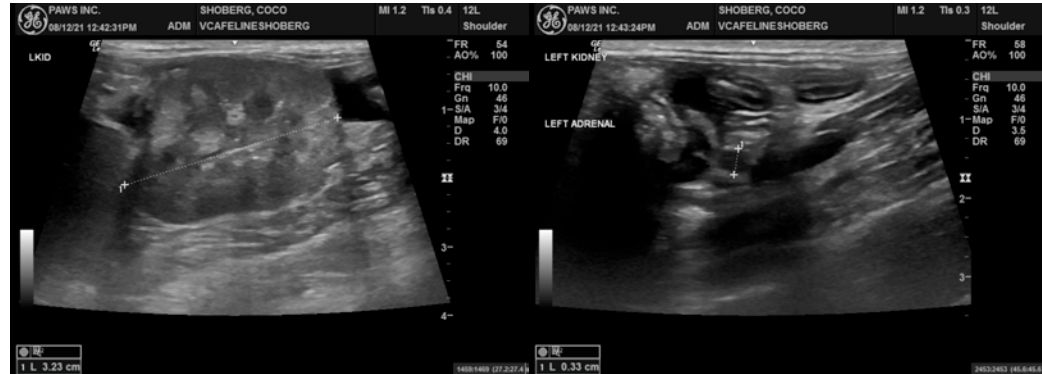
Dr. Vincent Fleming

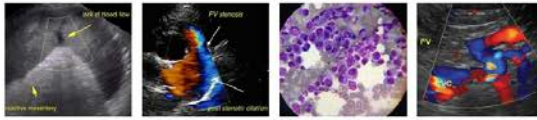
INVOICE

24611

DATE

8/12/21





PATIENT

Coco Shoberg

SPECIES

Feline

BREED

DSH

SEX

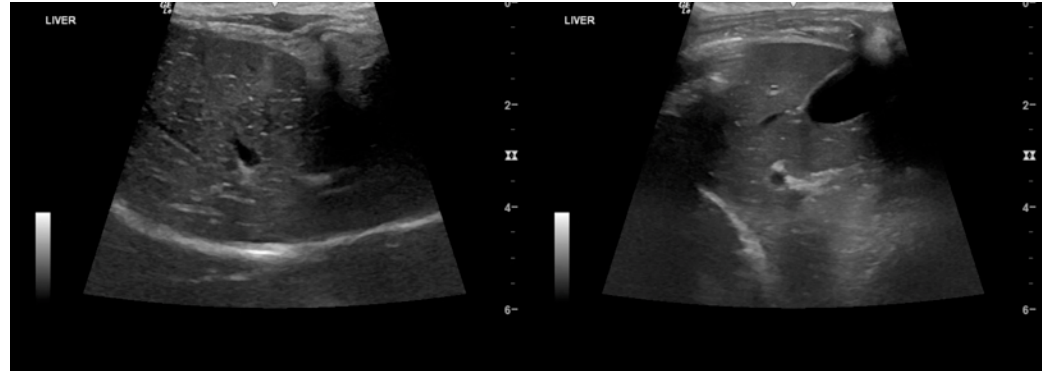
Neutered Male

AGE

16 Years

WEIGHT

8 Pounds



The information and recommendations provided are based on the images presented by the referring veterinarian. No evaluation can be communicated regarding pathology that was not visible in the image/video clips provided.

Thank you for this referral. If the clinical or image interpretation does not parallel your findings or if I can be of any further assistance please contact me.

Kathleen Sennello DVM,MS, Diplomate ACVIM (Small animal Internal Medicine)

kathleen.sennello@sonopath.com

INTERPRETED BY

Kathleen Sennello DVM,
MS, Diplomate ACVIM
(Small Animal Internal
Medicine)

IMAGING PERFORMED BY

Loetitia Saint-Jacques, RVT

HOSPITAL NAME

VCA Feline AH

REFERRING VET

Dr. Vincent Fleming

INVOICE

24611

DATE

8/12/21